

UC-NRLF



B 4 091 939

QUIZ-COMPENDS

EQUINE ANAT. & PHYS.
DR. BALLOU.


M

A Com

MEDICAL SCHOOL
LIBRARY

H

*Consultin
Lectur
Middle
Exami
Durha*



Gift of

Panama-Pacific Intern'l
Exposition Company.

For th
omists h
revise se
importan
the Unite
its wider
students.

Amor
R. J. Te
Bardeen
W. H. A.

The t
will be
clature (
to the ill
been ver

Ca
H
\$7

PART
PART
PART
PART

Mammary Glands. Index. \$1.50.

PART V. Surgical and Topographical Anatomy. Index. \$1.00.

ny

h Authors

MURRICH

*iversity of
ociation of
Member of
Institute of*

ican anat-
write and
e the very
ratories of
and, with
n-speaking

McMurrich,
Charles R.
Gunn and

e of merit
Nomen-
been paid
e book has

One
cco,
tely.

. \$1.50.
ex. \$2.00.
x. \$1.50.

Urinary
Skin and

TYSON. The Practice of Medicine. Fourth Revised Edition.

A Text-Book for Physicians and Students, with Special Reference to Diagnosis and Treatment. By JAMES TYSON, M.D., Professor of Medicine in the University of Pennsylvania, and Physician to the Hospital of the University; Physician to the Pennsylvania Hospital, etc. Fourth Edition, Revised and Enlarged. Colored Plates and 240 other Illustrations, 13 of which are in Colors. 8vo. *Just Ready.* Cloth, \$5.50; Leather or Half Morocco, \$6.50

* * This edition contains 100 new illustrations and has been increased in size by 65 pages. It includes a **Special Article on Animal Parasites and the Conditions Caused by them**, by ALLEN J. SMITH, M.D., Professor of Pathology, University of Pennsylvania.

BY THE SAME AUTHOR.

Bright's Disease and Diabetes. New Edition. Colored Plates.

Including Articles on Ocular Manifestations in these Diseases by G. E. DE SCHWEINITZ, A.M., M.D., Professor of Ophthalmology in the University of Pennsylvania; Ophthalmic Surgeon to the Philadelphia Hospital. Second Edition, Revised and Rewritten. 7 Colored Plates and other Illustrations. Octavo.

Cloth, \$4.00; Half Morocco, \$5.00

Guide to the Examination of Urine. Tenth Edition.

For the Use of Physicians and Students. With Colored Plate and Numerous Illustrations Engraved on Wood. Tenth Edition, Revised, Enlarged and partly Rewritten. 12mo. Cloth, \$1.50

Handbook of Physical Diagnosis. Fourth Edition.


Fourth Edition, Revised and Enlarged. With two Colored Plates and 55 other Illustrations. 298 pages. 12mo. Cloth, \$1.50

Cell Doctrine.

Its History and Present State. Second Edition. Cloth, \$1.50

P. BLAKISTON'S SON & CO., Publishers and Booksellers

1012 WALNUT STREET, PHILADELPHIA

 **BASED ON RECENT MEDICAL LITERATURE.**

Gould's Medical Dictionaries.

The Standard Medical Reference Books.

215,000 HAVE BEEN SOLD

INCLUDING THE PRONUNCIATION, ACCENTUATION, DERIVATION, AND DEFINITION OF THE TERMS USED IN MEDICINE AND THOSE SCIENCES COLLATERAL TO IT. WITH MANY USEFUL TABLES. ∴ ∴ ∴ ∴ ∴ ∴ ∴ ∴

By **GEORGE M. GOULD, A.M., M.D.,**
Editor of American Medicine.

The Illustrated Dictionary of Medicine, Biology and Allied Sciences.

1633 pages. Fifth Edition.

Sheep or Half Morocco, \$10.00; with Thumb Index, \$11.00
Half Russia, Thumb Index, \$12.00

Dictionary of New Medical Terms.

Being a Supplement to "Gould's Illustrated Dictionary," consisting of upwards of 571 double-column pages and containing many thousand new terms and definitions.

Sheep or Half Morocco, \$5.00; with Thumb Index, \$6.00
Half Russia, Thumb Index, \$7.00

The Above Two Books bound in One Volume, Half Morocco, \$15.00

The Practitioner's Medical Dictionary.

Illustrated. Octavo. xvi + 1043 pages. *Just Ready.*

Flexible Leather, Gilt Edges, \$5.00; Thumb Index, \$6.00

The Medical Student's Dictionary.

Eleventh Edition. Enlarged and illustrated with a large number of Engravings. 840 pages.

Half Morocco, \$2.50; with Thumb Index, \$3.00
Flexible Leather, Burnished Edges, Thumb Index, \$3.50

The Pocket Pronouncing Medical Lexicon.

(30,000 Medical Words Pronounced and Defined.)

Fourth Edition, Revised and Enlarged. 838 pages.

Flexible Leather, Gilt Edges, \$1.00; Thumb Index, \$1.25

215,000 Copies of Gould's Dictionaries Have Been Sold.

P. BLAKISTON'S SON & CO., Publishers and Booksellers
1012 WALNUT STREET, PHILADELPHIA



Digitized by the Internet Archive
in 2007 with funding from
Microsoft Corporation

From The Southern Clinic.

"We know of no series of books issued by any house that so fully meets our approval as these ? Quiz-Compendis?. They are well arranged, full, and concise and are really the best line of text-books that could be found for either student or practitioner."

BLAKISTON'S ? QUIZ-COMPENDIS ?

The Best Series of Manuals for the Use of Students.

Price of each, Cloth, \$1.00 net. Interleaved, for taking Notes, \$1.25 net.

☞ These compendis are based on the most popular text-books and the lectures of prominent professors, and are kept constantly revised, so that they may thoroughly represent the present state of the subjects upon which they treat.

☞ The authors have had large experience as Quiz-Masters and attaches of colleges, and are well acquainted with the wants of students.

☞ They are arranged in the most approved form, thorough and concise, containing over 900 fine illustrations, inserted wherever they could be used to advantage.

☞ Can be used by students of *any* college. They contain over 900 Illustrations.

☞ They contain information nowhere else collected in such a condensed, practical shape.

Illustrated Circular Free.

POTTER'S ANATOMY. Seventh Revised and Enlarged Edition. Including Visceral Anatomy. Can be used with either Morris' or Gray's Anatomy. 138 Illustrations and 16 Plates of Nerves and Arteries, with explanatory Tables, etc.

BRUBAKER, PHYSIOLOGY. Twelfth Edition, with Illustrations and a Table of Physiological Constants. Enlarged and Revised.

LANDJS, OBSTRETRICS. Eighth Edition. Revised and Edited by Wm. H. WELLS, M. D., Instructor Jefferson Medical College, Philadelphia. 56 Illustrations.

POTTER, MATERIA MEDICA, THERAPEUTICS, AND PRESCRIPTION WRITING. Seventh Revised Edition.

WELLS, GYNECOLOGY. Third Edition. With 145 Illustrations.

GOULD and PYLE, DISEASES OF THE EYE AND REFRACTION. Including Treatment and Operations and a Section on Local Therapeutics. With Formulæ and 109 Illustrations, several of which are in Colors. Third Edition.

HORWITZ'S SURGERY. Minor Surgery, and Bandaging. Fifth Edition. Enlarged and Improved. With 98 Formulæ and 167 Illustrations.

LEFFMANN, CHEMISTRY, Inorganic and Organic. Fifth Edition. Including Urinalysis, Animal Chemistry, Chemistry of Milk, Blood, Tissues, the Secretions, etc.

STEWART, PHARMACY. Sixth Edition. Based upon Prof. Remington's Text-Book of Pharmacy.

BALLOU, VETERINARY ANATOMY AND PHYSIOLOGY. With 29 graphic Illustrations.

WARREN, DENTAL PATHOLOGY AND DENTAL MEDICINE. Fourth Edition. Illustrated. Containing all the most noteworthy points of interest to the Dental Student, and a Section on Emergencies.

HATFIELD, DISEASES OF CHILDREN. Colored Plate. Third Edition. Revised and Enlarged.

ST. CLAIR, MEDICAL LATIN. Second Edition.

SCHAMBERG, DISEASE OF THE SKIN. Fourth Edition. Revised and Enlarged. 108 Illustrations.

RADASH, HISTOLOGY. With 98 Illustrations.

THAYER, SPECIAL PATHOLOGY. With 34 Illustrations.

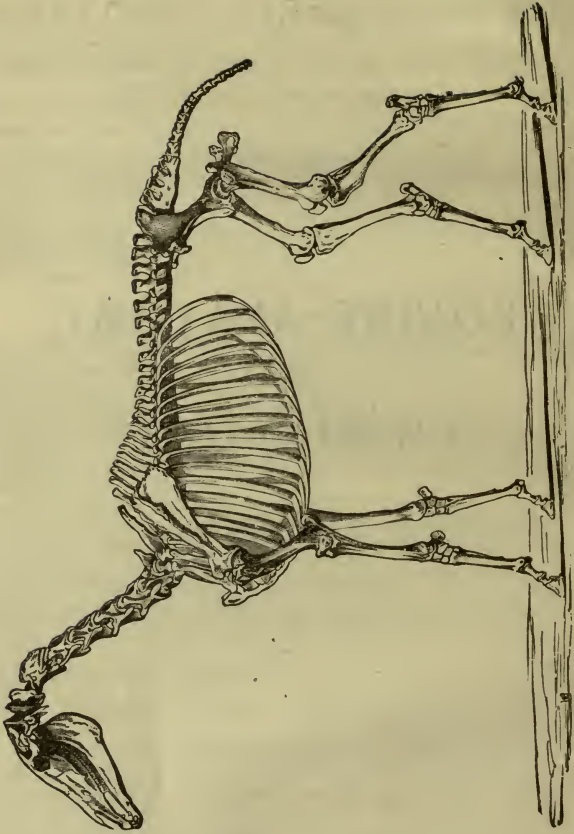
KYLE, EAR, NOSE AND THROAT. 85 Illustrations.

HIRSCH, GENITO-URINARY DISEASES AND SYPHILIS 71 Illustrations

PITFIELD, BACTERIOLOGY. 4 Plates and 80 other Illustrations

EQUINE ANATOMY
AND
PHYSIOLOGY

BALLOU



SKELETON OF THE HORSE.

BLAKISTON'S ? QUIZ-COMPENDS ?

A COMPEND
OF
EQUINE ANATOMY
AND
PHYSIOLOGY

BY ^{LC?}
WILLIAM R. BALLOU, M.D. 1864-

FORMERLY PROFESSOR OF EQUINE ANATOMY AND LECTURER ON PHYSIOLOGY, NEW
YORK COLLEGE OF VETERINARY SURGEONS; INSTRUCTOR IN GENITO-URINARY
SURGERY, NEW YORK POLYCLINIC; SURGEON BELLEVUE DISPENSARY;
LATE HOUSE SURGEON, BELLEVUE HOSPITAL, NEW YORK.

WITH
TWENTY-NINE GRAPHIC ILLUSTRATIONS

SELECTED FROM
CHAUVEAU'S "COMPARATIVE ANATOMY."

PHILADELPHIA
P. BLAKISTON'S, SON & CO.,
1072 WALNUT STREET,
1907

Copyright, 1890, by P. Blakiston, Son & Co.

Printed by
The Maple Press,
York, Pa.

QL737
U6B1
1907

TO MY STUDENTS AT THE
NEW YORK COLLEGE OF VETERINARY SURGEONS
THIS LITTLE WORK IS DEDICATED,
IN THE HOPE THAT IT MAY ASSIST THEM
DURING THEIR LIFE WORK,
WITH THE KINDEST WISHES OF
THE AUTHOR.

8502

PREFACE.

The popularity of this series of "Compendis" demonstrates that they supply a long-felt want. From a considerable experience as a quiz-master of medical students and a teacher of anatomy, the writer has seen the benefits of these, and has endeavored to supply for students of veterinary anatomy and physiology a work which would answer their needs not only as a text-book, but also for work in the dissecting-room.

While, in the main, the standard work of *Chauveau* has been followed, the works of *Strangeways*, *Gray* and *Quain* have been consulted. In the section on Physiology the late works of *Flint*, *Meade*, *Smith* and *Jeffrey Bell* have furnished the greater part of the data, and to them indebtedness is due. Many of the chemical analyses have been taken from *Charles*

Lack of space necessitated a condensation of some subjects to narrow limits, while others have been merely alluded to. The author trusts it will meet the same cordial welcome from the veterinary profession which the other works of this series have received from their fellow-workers in medicine.

My acknowledgments are due to Messrs. D. Appleton & Co., the publishers of *Chauveau's* "Comparative Anatomy of Domesticated Animals," for their courtesy in supplying the illustrations I have used.

CONTENTS.

	PAGE
ANATOMY	9
PHYSIOLOGY	9
Anatomy, Divisions of	9
Osteology	9
Bones, Varieties	9
Structure of	10
Vertebral Column	11
Head	13
Face	18
Fossæ of Skull	23
Hyoid	24
Bones of Thorax	24
Anterior Extremity	25
Posterior Extremity	31
Arthrology	37
Classes of Articulations	37
Structure of Articulations	38
Articulations of Vertebral Column	38
Lower Jaw	39
Hyoid	40
Thorax	40
Anterior Limb	41
Posterior Limb	45
Myology	50
Structure of Muscles	50
Varieties of Muscles	50
Appendages of Muscles	50
Muscles of Face	51
Mastication	53
Hyoid	54
Tongue	55
Palate	55
Pharynx	56
Trunk	57
Inferior Cervical Region	57
Back	62
Thorax	63
Abdomen	65

	PAGE
Inguinal Canal	66
Muscles of Anterior Extremity	66
Pelvis	72
Thigh	75
Leg	77
Tail	80
Angiology	81
Pericardium	81
Heart	81
Arteries of Anterior Extremity	85
Head and Neck	89
Trunk	93
Posterior Extremity	96
Artery, Pulmonary	98
Veins, Structure of	98
Head and Neck	99
Anterior Extremity	99
Abdomen and Pelvis	101
Posterior Extremity	102
Pulmonary	102
Lymphatics	102
Neurology	103
Nervous System, Structure of	103
Spinal Cord	103
Membranes of	103
Brain, Membranes of	105
Medulla Oblongata	105
Pons Varolii	106
Cerebellum	107
Cerebrum	107
Ventricles of	109
Nerves, Cranial	111
Cervical	115
Brachial Plexus of	115
Lumbo-Sacral Plexus of	117
Dorsal	118
Sympathetic Nervous System	118
VISCERA	120
Digestive System	120
Mouth	120
Tongue	120
Palate	120
Teeth	120
Salivary Glands	122
Pharynx	122
Æsophagus	122
Abdominal Cavity	123
Stomach	123
Small Intestines	125

	PAGE
Digestive System, Cæcum	127
Large Colon	128
Small Colon	128
Rectum	128
Anus	128
Liver	129
Lobes	129
Fissures	129
Ligaments	129
Parenchyma	129
Pancreas	131
Spleen	132
Peritoneum	132
Respiratory Organs	133
Larynx	133
Cartilages	133
Articulations	134
Muscles	135
Trachea	136
Bronchi	138
Lungs	138
Pleura	139
Thorax	140
Mediastinæ	140
Ductless Glands	140
Thyroid	140
Thymus	141
Urinary Organs	141
Kidneys	141
Supra-renal Capsules	144
Ureters	144
Bladder	144
Male Genitals	145
Testicles	145
Descent of	146
Vas Deferens	147
Vesiculæ Seminales	147
Prostate Gland	148
Urethra	148
Penis	149
Perineum	150
Female Genitals	150
Vulva	150
Vagina	151
Uterus	152
Oviducts	153
Ovaries	153
Mammary Glands	155
Organs of Special Sense	155
Smell	155

	PAGE
Organs of Special Sense, Nasal Fossæ.....	155
Nostrils.....	156
Taste.....	157
Papillæ of.....	157
Nerves of.....	157
Auditory Organs.....	157
External Ear.....	157
Cartilages of.....	157
Muscles of.....	158
Canal of.....	159
Middle Ear.....	159
Internal Ear.....	161
Eye ^s	162
Orbits.....	162
Tunics.....	162
Humors.....	162
Muscles of Lid.....	165
Globe.....	165
Appendages.....	166
Blood Supply.....	167
Skin and Appendages.....	167
Hairs.....	168
Hoof.....	168
 PHYSIOLOGY.....	 173
Definition.....	173
Circulation.....	173
Composition of Blood.....	173
Coagulation.....	174
Circulation.....	175
Velocity of Blood Current.....	176
Respiration.....	177
Inspiration.....	177
Muscles of.....	177
Expiration.....	178
Muscles of.....	178
Nervous Mechanism.....	179
Alimentation.....	180
Definition.....	180
Digestion.....	180
Food.....	181
Prehension.....	181
Mastication.....	182
Salivary Digestion.....	183
Deglutition.....	183
Gastric Digestion.....	184
Bile.....	185
Tests for.....	185
Glycogenic Function of Liver.....	186
Pancreatic Juice.....	186

	PAGE
Intestinal Juice.....	187
Fæces.....	188
Defecation.....	188
Intestinal Movements.....	188
Absorption.....	188
Lymph.....	189
Chyle.....	189
Animal Heat.....	190
Secretion.....	190
Definition of.....	190
Excretion, Definition of.....	190
Perspiration.....	191
Mammary Secretion.....	191
Urine.....	192
Composition of.....	192
Amount of, in Twenty-four Hours.....	193
Micturition.....	193
Ductless Glands.....	193
Supra-renal Capsules.....	193
Spleen.....	194
Thymus and Thyroid.....	194
Pituitary Body and Conarium.....	194
Nervous System.....	194
Nerves, Termination of.....	194
Spinal.....	195
Cranial.....	195
Spinal Cord.....	197
Functions of.....	198
Columns of.....	198
Medulla Oblongata.....	198
Pons.....	199
Corpora Quadrigemina.....	199
Optic Thalami.....	199
Olfactory Lobes.....	199
Cerebellum.....	199
Cerebrum.....	199
Sympathetic System.....	200
Special Senses.....	200
Touch.....	200
Smell.....	200
Taste.....	200
Hearing.....	201
Sight.....	201
Reproduction, Reference to.....	202

COMPLIMENTS
OF
P. Blakiston's Son Co.,
PHILADELPHIA, PA.

EQUINE ANATOMY AND PHYSIOLOGY.

ANATOMY.

Anatomy is the science of organization.

Equine Anatomy is its study confined to the horse.

Divisions.

Osteology, the study of bones; *Arthrology* or *Syndesmology*, of the joints; *Myology*, of the muscles; *Angiology*, of the vessels; *Neurology*, of the nervous system; *Splanchnology*, of the viscera.

OSTEOLOGY, OR THE BONES.

See plate opposite title page.

These, the passive portion of the locomotory apparatus, are divided into *long*, *short*, *flat* and *irregular*. The *long* bones are found in the limbs and are hollowed out internally; example, the femur. The *short* bones are about as wide as long, and contain no medullary cavity; example, the tarsus and carpus. The *flat* bones are found in the head, pelvis, and shoulder, contain no medullary cavity, and are not thick; examples, the parietal and scapula. The *irregular* bones have none of the characteristics of the preceding; example, the hyoid.

The Eminences of Bones.

Heads are elevations on the extremities of bones, describing the segment of a sphere; *condyles* are segments of an oval figure parallel to its large axis; *processes* or *apophyses* when much de-

tached from bones; *protuberances* or *tuberosities* are large and round; *lines*, *crests* and *ridges* are narrow and long.

Cavities of Bones.

Cotyloid are deeply excavated; *channels* or *furrows* when wide and deep; *fissures* when narrow and rough; *digital* when of the size of finger-ends; *fossæ*, *sinuses*, *cells* and *notches* are also cavities. An opening in a bone is a *foramen*, if long, a *canal*.

Composition of Bone.

Bone is composed of one-third part *animal* matter, giving elasticity, and two-thirds *mineral* matter, principally salts of lime, giving strength.

Structure of Bone.

Bones are covered externally by a fibrous, nourishing membrane, the *periosteum*. Microscopically bone is seen to consist of the following parts: the medullary canal, see cavity of long bones; the *Haversian canals* for the passage of vessels; *lacunæ*, small black spaces containing bone cells with little canals, the *canaliculi*, branching from them; these three structures form the *Haversian systems*. *Lamellæ* are layers of bone under the periosteum or around the Haversian canals.

The *marrow* or medulla of bones consist, of *red* or *fætal* marrow, and *yellow* marrow. The former is rich in round cells, the latter in fat.

Development of Bone.

It may be developed from *cartilage* or *membrane*. The former method is shown in the long, the latter in the flat bones.

Number of Bones.

Vertebral column.....	52
Head.....	8
Face.....	16
Hyoid, sternum and ribs.....	38
Anterior extremities.....	40
Posterior extremities.....	40

419

The ossicles of the middle ear are not included; the *sacrum* is considered as five separate bones, the *superior turbinated* as part of the *ethmoid*, the *pterygoid* as a process of the sphenoid, the *parietal* as a double bone, and the sesamoids are included.

THE VERTEBRAL COLUMN.

The spinal column is composed of 52 segments, divided into *true* and *false*.

The *true* are divided into 7 *cervical*, 18 *dorsal* and 6 *lumbar*. The *false* into the *sacrum*, of 5 segments closely fused, and the *coccyx*, of from 15 to 18 segments more or less movable.

Common Characteristics of Vertebrae.

Each one has a *body* and an *arch*, enclosing the *spinal canal*, which includes the spinal cord. The **body** has a *superior face*, forming the lower boundary of the spinal canal, an *inferior*, two lateral surfaces, a *head*, convex for articulation, an *anterior extremity*, and a concave *posterior extremity*.

The *arch* projects upward from the top of the body, and consists of *pedicles*, *laminæ*, *transverse*, *spinous* and *articular processes*.

The *pedicles* are two strong processes projecting upward and supporting the transverse and articular processes.

The *transverse processes* project laterally from the summit of the pedicles. They are elongated antero-posteriorly in the cervical, short in the dorsal, and long in the lumbar regions.

The *laminæ* are two processes uniting above and forming the spinous process; they enclose the spinal cord.

The *spinous processes* project upward and backward, from the junction of the laminæ. They are small in the cervical, long in the dorsal, rough and enlarged in the lumbar regions.

The *articular processes* are four in number, two anterior and two posterior. The former look upward, the latter downward. In each is a notch, which, when in apposition, forms the intervertebral foramen.

CERVICAL REGION.

Common Characters.

The *body* is long and thick and has an inferior spine.

The *spinous* processes are a roughened line.

The *transverse* or *trachelian* processes are elongated antero-posteriorly and are in relation to the trachea. They are traversed at their base by a foramen, transmitting vessels, the *vertebral*. The *articular processes* look downward and inward.

Peculiar Cervical Vertebrae.

The 1st or *atlas* articulates with the occipital, has a thin body,

no head, two deep concave facets in its place; an articular surface below for the odontoid process; transverse process very rudimentary. The spinous processes are flattened from above, downward, are elongated and show two foramina, the anterior transmitting a vein, the posterior the vertebral vessels.

The 2d or *axis* is very long, has no head, but, in its place, a process convex and smooth below, concave above, articulating with the body of the atlas, called the *odontoid* (or tooth-like). The *spinous process* is very elongated antero-posteriorly and divided into two lips. The *transverse* are little developed.

The 5th has a heart-shaped tubercle on its inferior spine.

The 6th or *tricuspid* has a third prolongation on its transverse process.

The 7th or *prominens* has a long spine, demi-facets behind for the 1st rib, the transverse processes are single, and the vertebral foramen is absent.

THE DORSAL VERTEBRÆ.

The *body* is short with a projecting *head* anteriorly, a marked depression posteriorly, and four articular cavities for the heads of the ribs, two in front, two behind. The *spinous processes* are long, and flattened on the sides. The *transverse processes* are short, and have a facet for articulation with the tuberosity of a rib. The length of the spines increases to the 5th and then decreases to the 18th. The 18th has no facet on its body behind.

THE LUMBAR VERTEBRÆ.

The *body* is longer and wider than the preceding, the *spinous process* is shorter and surmounted by a tubercle; the *transverse processes* are flattened from above, downward, and pass transversely outward, the fifth and sixth, and sixth and front of the sacrum articulating by facets.

THE SACRUM.

The sacrum consists of five segments, closely fused. It articulates with the last lumbar and its transverse process in front, the coccyx behind and the os innominata laterally.

It is triangular in shape with a *base* anteriorly articulating with the body, articular and transverse processes of the last lumbar; showing also the vertebral canal, an *apex* behind articulating with the coccyx, two *lateral borders* articulating with the innominate

bones in front, an *inferior surface* smooth and showing four *intervertebral foramina*, and a *superior surface* showing the spinous process and the supersacral foramina.

THE COCCYX.

This consists of from fifteen to eighteen segments; the first three or four only are complete, the spinal canal then simply continuing as a groove. The first is often consolidated with the sacrum.

THE HEAD.

This consists of eight bones, the *occipital*, two *parietal*, two *temporal*, the *ethmoid*, *frontal* and *sphenoid*.

OCCIPITAL.

The *occipital* forms the upper and posterior portion of the head, and is divided into an *external* and *internal face* and *circumference*.

The **External Face** shows—

The *external occipital protuberance*, an elevation forming the point of the head.

The *occipital foramen* (or foramen magnum) below and in front of the preceding, a large round opening, transmitting the spinal cord, its membranes, the cerebro-spinal vessels and eleventh nerve.

The *basilar process*, a long narrow prolongation passing forward to unite with the body of the sphenoid.

Two *sharp crests* running outward, the superior, continuing as the zygomatic process, the inferior, terminating at the base of the styloid process.

The two *condyles* which lie on either side of the foramen, articulating with the atlas.

The *styloid processes*, two large blunt projections lying outside the preceding.

The *condyloid foramina*, lying at the bottom of a fossa under the condyles and transmitting the twelfth nerves.

The **Internal Face** shows the foramen magnum, condyloid foramen, and a smooth roof for the cranial cavity.

The **Circumference** shows—

Articulations above for the parietal bones, and laterally for the temporal.

A *deep notch* closed in by the temporal and sphenoid, forming the *anterior* and *posterior lacerated foramina*, separated by a ligament.

Articulations 6.

Two *parietal*, two *temporal*, *sphenoid* and *atlas*.

PARIETAL (A WALL).

The parietals form the roof of the cranial cavity, are developed from two centres closely fused together and closed in by the *occipital*, *frontal*, *temporal* and opposite *parietal*.

It has *external* and *internal* surfaces, and *four borders*, *superior*, *inferior*, *external* and *internal*.

The *external surface* shows the *parietal ridge* beginning at the occipital protuberance and ending at the supra-orbital process of the frontal. It divides the bone into two rough and one smooth portions.

The *internal surface* shows depressions for the brain and a marked elevation, the *parietal eminence*, which lodges the confluence of the sinuses, the *torcular Herophili*; from this point lateral ridges run, lodging the *parieto-temporal confluents*. In front it is prolonged by the suture between the two bones, the *sagittal*.

The *superior border* is thick and articulates with the occipital.

The *inferior border* articulates with the frontal.

The *internal border* articulates with its opposite.

The *external border* articulates with the temporal and forms a groove, the *parieto-temporal canal*.

Articulations 5.

Occipital, *frontal*, *sphenoid*, *temporal* and *opposite*.

FRONTAL.

The frontal (*frons*, the forehead) forms the front part of the roof of the cranium and part of the face. It lies between the *parietals* above, the *nasals* and *lachrymals* below, and the *temporals* laterally.

It has two *surfaces*, an *external* and *internal*, and four borders, a *superior*, *inferior* and two *lateral*.

The **External Surface** shows—

A median plane surface covered with skin and forming the base of the forehead. Two strong processes projecting outward form-

ing the *orbital arch* and articulating externally with the zygomatic process of the temporal. An opening in the orbital arch, the supra-orbital.

At the base of the arch a depression for the pulley of the superior oblique.

The **Internal Surface** is concave and shows—

A *superior part* articulating with the parietal above and joining below the *crista galli* and wing of the sphenoid.

An *inferior part* articulating in the median line with the ethmoid, and shows two large openings into the *frontal sinuses*, two spaces between the external and internal plates of the bone. It forms part of the roof of the nasal fossæ.

The *superior border* articulates with the parietal and temporal, the *inferior* with the *lachrymal* and nasal, and the *lateral* with the palate and sphenoid, forming with the latter the orbital foramen.

The frontal has two centres of ossification.

Articulations, 14.

With two *parietal*, two *temporal*, two *nasal*, two *lachrymal*, *sphenoid*, *ethmoid*, two *palate* and two *superior maxillary*.

ETHMOID.

The ethmoid (sieve-like) lies at the anterior part of the floor of the skull, and forms part of the roof of the nasal fossæ.

It is divided into a *vertical plate*, a *horizontal portion*, and two *lateral masses*.

The *vertical portion* articulates below with the vomer and the median nasal cartilage, forms the median septum of the nose, and terminates above in the *crista galli*, a small elevation on which a process of the cerebral dura mater is attached.

The *horizontal portion* forms the roof of the nasal cavities, part of the cranial floor, and is perforated by a number of openings for the passage of the filaments of the olfactory nerves. The *lateral masses* form part of the orbital and nasal walls, are excavated to form the ethmoidal cells and show an anterior projection forming the *superior turbinated* bone which is really a part of the ethmoid and considered as such.

Articulations, 7.

Sphenoid, *frontal*, *vomer*, two *palate*, two *superior maxillary*.

SPHENOID.

The sphenoid (a wedge) serves to connect the bones of the head and face, being wedged in between the occipital behind, the ethmoid and frontal in front, the parietals and temporals laterally. It is divided into a *body* and *two wings*.

The *body* shows on its internal surface—

The *optic fossa*, a transverse depression for the optic nerves, ending in the *optic foramina*, which open into the orbit.

The *sella turcica* or *pituitary fossa*, behind this, receiving the pituitary body.

The *wings* projecting from the body and articulating with the frontal.

Two fissures outside the *sella turcica*, the inner one lodging the *cavernous sinus*.

The *supra-sphenoidal canals*, the upper one called the great sphenoidal fissure, the lower the *foramen rotundum*, the middle opening near the optic.

The **External or Inferior Surface** shows—

Outside, the *vidian canal* opening into the orbit.

The *internal pterygoid plate* (pterygoid bone) outside the vomer, flattened laterally.

Its internal face forms part of the pharyngeal walls.

At its base is found the vidian canal (see above).

Its apex forms the hamular (hooked) process, passing backward and serving for the passage of the tendon of the *tensor palati*.

The *external pterygoid* or *sub-sphenoidal* process lying outside the preceding.

Above this the opening of the *sub-sphenoidal canal* which opens into the orbit.

Below two fissures for articulation with the *vomer*.

The *superior* or *posterior* border is continuous with the basilar process of the occipital, and on each side forms the inner boundaries of the lacerated foramen. Three notches are also seen, for the passage of the *carotid artery*, the *foramen ovale* for the *inferior maxillary nerve*, and one for the *middle meningeal artery*, the *foramen spinosum*.

The *anterior* or *inferior* border shows—

The *sphenoidal sinuses*, excavations continuous with the ethmoidal plate.

The *lateral borders* show—

Thin edges for articulation with the frontal, squamous part of the temporal and parietal.

Articulations, 10.

Occipital, ethmoid, frontal, vomer, two parietal, two temporal and two superior maxillary.

THE TEMPORAL.

The *Temporal* is important as forming the bony canals for the reception of the organ of hearing, and is found forming parts of the sides of the head, face and cranial cavity.

It is divided into squamous and tuberos portions.

The **Squamous portion** is flattened, oval in shape, forming part of the *lateral cranial wall*, and is divided into external and internal surfaces and a circumference.

The **External Surface** shows—

The *zygomatic* process, passing downward and forward, and articulating with the zygoma; at its base is found the *glenoid cavity* for the condyle of the inferior maxilla, limited in front and behind by two marked elevations.

The **Internal Surface** shows—

The *groove*, which, with the parietal, forms the parieto-temporal canal and depressions for cerebral convolutions.

The *circumference* articulates with the frontal, parietal, sphenoid and occipital.

It is not united to the tuberos portion.

The **Tuberos portion** passes forward and inward between the occipital and parietal, and is divided into *petrous* and *mastoid* processes.

The *petrous* portion shows—

An *anterior* face in contact with the parietal.

A *posterior* face in contact with the occiput.

An *internal* face which shows the *internal auditory meatus*, the entrance of the seventh nerve to the internal ear, and the opening of the *aqueductus fallopii*.

An *anterior border* separating the cerebral from the cerebellar cavities.

The *mastoid* portion forms the base of the horizontal part of the bone and shows—

The *external auditory meatus*, a round opening leading into the *auditory canal*.

The *mastoid* process, a round eminence behind the preceding, hollowed out with cells, communicating with the middle ear.

The *stylo-mastoid*, in front of the preceding.

Below, the *styloid* process for the origin of the *Tensor Palati* and *Eustachian tube*.

The *hyoid* or *vaginal* process, a small elevation.

Articulations 7.

Occipital, parietal, frontal, sphenoid, zygoma, superior maxilla and *inferior maxilla*.

THE FACE.

This consists of 16 bones, viz., *two superior maxillary, two inter-maxillary, two palate, two zygomas, two lachrymals, two nasals, two inferior turbinated, one vomer* and *one inferior maxillary*. The *pterygoid* bones are considered parts of the sphenoid, the *superior turbinated* parts of the ethmoid, and the *hyoid* not as belonging to the face.

THE SUPERIOR MAXILLA.

These two large bones form the greater part of the structure of the face, and are wedged in between the *frontal, nasal zygomas, palates, lachrymal* and *vomer*.

It is divided into *two faces, two borders, and two extremities*.

The **External Face** shows—

A *convex* surface ending below in the super-maxillary spine, a long ridge continuous with the zygoma.

The orifice of the *intra-orbital* canal.

The **Internal Face** shows—

The flat surface, forming the outer *wall of the nasal fossa*.

A deep excavation, the *maxillary sinus*.

A *fissure* which forms the *palatine canal*.

A *ridge* for the *inferior turbinated*.

The inferior opening of the *lachrymal canal*.

The *palatine process*, uniting with the opposite, forming the floor of the nasal fossa.

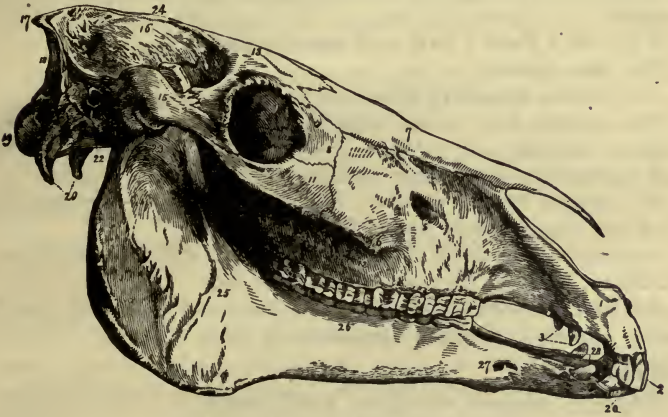
Anterior border shows—

Articular processes for the *nasal, pre-maxillary, lachrymal* and *palate bones*.

External border shows—

Six cavities for the molar teeth, behind them the *alveolar tuberosity*. Below, the small interidental space.

FIG. 1.



LATERAL VIEW OF THE HORSE'S SKULL.

- 1, Premaxillary bone; 2, Upper incisors; 3, Upper canine teeth; 4, Superior maxillary bone; 5, Infraorbital foramen; 6, Superior maxillary spine; 7, Nasal bones; 8, Lachrymal bone; 9, Orbital cavity; 10, Lachrymal fossa; 11, Malar bone; 12, Upper molar teeth; 13, Frontal bone; 15, Zygomatic process, or arch; 16, Parietal bone; 17, Occipital protuberance; 18, Occipital crest; 19, Occipital condyles; 20, Styloid processes; 21, Petrous bone; 22, Basilar process; 23, Condyle of inferior maxilla; 24, Parietal crest; 25, Inferior maxilla; 26, Inferior molars; 27, Anterior maxillary foramen; 28, Inferior canine teeth; 29, Inferior incisor teeth.

Superior extremity shows—

A *rounded enlargement*, lodging the maxillary sinus.

The *infra-orbital canal*, running above the molar teeth, ending opposite the third molar by one opening, the other extending into the interior.

The *palatine canal*, between the bone and palate, ending at the palatine fissure.

Inferior extremity shows—

A cavity for the tusk, uniting with the pre-maxillary.

Articulations, 8.

Opposite, palate, pre-maxillary, ethmoid, lachrymal, nasal, inferior turbinated, zygoma.

PRE-MAXILLARY OR INTER-MAXILLARY.

The pre-maxillaries are two bones lying at the inferior portion of the face and wedged in anterior to the superior maxillaries and nasals.

They each show a base and two processes.

The *base* shows—

An external smooth or *labial face*.

An *internal face*, united with the opposite, and showing the incisive foramen.

A *posterior* or *buccal face*, forming the roof of the mouth.

An *external border*, showing three sockets for the incisors, the inter-space and a half socket for the *tusk*.

An *external process* passes upward between the nasal and super-maxillary, forming part of the nose and face.

An *internal process* forms part of the nasal floor and buccal roof. It forms, also, the deep incisive notch.

Articulations 4.

Opposite, superior maxillary, nasal, vomer.

PALATE.

The palates, two in number, at the back part of the nasal and oral cavities, are elongated from above downward, and show *two faces, two borders* and *two extremities*, a *superior*, united with the sphenoid, and an *inferior*, united with the opposite.

The **External Face** shows—

A superior *orbital*, inferior *palatine*, forming the roof of the palate, and middle *articular*, for the superior maxillary, *portions*.

The *internal face* forms part of the outer nasal wall.

The *anterior border* shows—

A deep foramen, the *nasal*, an articulation for the super-maxillary, and a cavity uniting with the sphenoidal sinus.

The *posterior border* shows—

The palatine crest above, and a surface for the external *pterygoid plate*.

Articulations, 7.

Superior maxillary, sphenoid, inferior turbinated, vomer, ethmoid, frontal and opposite.

ZYGOMATIC OR MALAR.

The zygomas form part of the side of the face, wedged in between the superior maxilla, frontal and zygomatic process of the temporal. It has a *base*, united with the superior maxillary, a *summit*, united with the zygomatic process, an *external face, internal face, anterior and posterior border.*

The *external face* has a smooth portion forming part of the orbital margin and a smooth convex facial portion.

The *internal face* shows an articulation for the superior maxilla.

The *anterior border* joins the lachrymal, the *posterior* or *masseteric* forms a ridge continuous with that of the superior maxilla.

Articulations, 3.

Superior maxillary, temporal and lachrymal.

LACHRYMAL.

The lachrymal is a quadrilateral bone forming parts of the face and orbit, bent on itself and wedged between the *frontal, nasal, malar and superior maxilla.* It shows *external and internal surfaces,* and a *circumference* articulating with the surrounding bones.

The *external surface* shows—

A *superior* or *orbital portion*, concave, and forming the upper extremity of the *lachrymal duct and fossa.*

An *inferior* or *facial* convex portion.

The *internal surface* forms part of the maxillary and frontal sinuses.

Articulations, 4.

Frontal, nasal, superior maxilla and malar.

NASAL.

The nasal bones are two in number, articulating with each other in the median line, and forming the bony framework of the nose.

They are triangular in shape, with their base upward uniting with the frontal, the *apex* downward and pointed, forming the *nasal prolongation.*

It also shows an *external* and *internal face*, an *external* and *internal border*.

The *external face* is convex from side to side and smooth.

The *internal face* gives attachment to the *ethmoid*, and is covered with mucous membrane.

The *external* border unites with the lachrymal, superior and inter-maxillaries, the internal with the opposite nasal.

Articulations, 5.

Frontal, lachrymal, superior maxillary, inter-maxillary and opposite.

INFERIOR TURBINATED.

These two scroll-shaped bones are attached to the superior maxilla and palate, and rolled from behind forward. It separates the middle from the inferior nasal meatus.

Articulations, 2.

Superior maxilla and palate.

VOMER.

The vomer is a single bone in the median facial line, forming part of the nasal septum, and attached above to the sphenoid by its upper extremity, which is divided into two narrow processes. Its lower extremity is attached to the superior maxillary palate and pre-maxillary bones. Its two lateral faces are smooth and covered with mucous membrane.

Articulations, 8.

Sphenoid, ethmoid, two superior maxillary, two pre-maxillary and two palate.

INFERIOR MAXILLA.

The lower jaw is a large bone forming the inferior and anterior part of the face, and articulating with the two temporal bones. It is convex externally, concave internally, forming the inter-maxillary space. It consists of *two extremities*, an inferior and superior, *two faces*, external and internal, and *two borders*, a superior and inferior.

The *inferior extremity* shows—

The union of the two lateral halves of the bone.

An *inferior or labial* face, smooth and convex, containing the opening of the *mental foramen* on the sides; at this point it is constricted, the *neck*.

A *superior* or concave *buccal face*, supporting the tongue.

A *circumference*, convex anteriorly, with sockets for the *six incisors*, and behind these for the two tusks.

The space between the lateral incisors and tusks, is called the dental interspace or bars.

The *superior extremity* shows—

The *condyloid process* elongated transversely for articulation with the glenoid cavity of the temporal.

The *neck*, a constriction below this.

The *coronoid process*, in front of the condyle, separated from it by the *sigmoid notch*, is flattened on its sides, and receives the insertion of the *temporal muscle*.

The *external face* shows—

A *smooth surface* below, a *rough one* above, for the masseter.

The *internal face* shows—

In its upper one-third the entrance of the *inferior maxillo-dental canal*, which runs down under the teeth, giving off another, the *mental foramen* (see above), and then continued in the bone under the incisors.

A *smooth surface* in its lower two-thirds.

The *mylo-hyoid ridge*, a line running parallel with and below the teeth.

The *genial surface*, a rough spot at the junction of the two sides.

The *anterior border* shows—

The *alveolar surface*, already described, and a *thin portion* for muscular insertion.

The *posterior border* shows—

A sharp *straight portion* and a more rounded portion above, changing its direction at this point. It is there called the *angle*.

Articulations, 2.

The *temporals*.

THE FOSSÆ.

The *cranial cavity* is oval in form, the walls formed by the *frontal*, *parietals* and *occipital* above; the *occipital*, *parietals*, *temporals* and *sphenoid* on the sides; the *occipital basilar process*, the *sphenoidal body*, the transverse portion of the *ethmoid*, and internal surface of the *frontal* below.

It is divided into *anterior* or *cerebral* and *posterior* or *cerebellar*

fossæ by the petrous portion of the temporal. In the posterior fossa is the *foramen magnum*, the communication between the spinal and cerebral cavities.

Contents—cerebrum, cerebellum, cranial nerves and vessels.

The *orbital cavity* and *nasal fossæ* are described with the special senses of sight and smell.

The *temporal fossæ*, oval in shape, lie behind the orbit, on the outer cranial wall, bounded *within* by the parietal ridge, *without* by the zygomatic process.

They *lodge* the temporal muscle, coronoid process and vessels.

THE HYOID.

The hyoid bone consists of seven segments, lying below the head, above the larynx and under the tongue, in the inter-maxillary space.

It consists of a *body*, *two thyroid* or *great cornua*, *two styloid* or *lesser cornua*, and *two styloid bones*.

The *body* is convex in front, concave behind, with two lateral prolongations, continuous with the thyroid cornua, and an *anterior appendix*, projecting into the muscular structure of the tongue.

The *thyroid* or *great cornua* project backward, articulating with the extremities of the thyroid cartilage.

The *styloid* or *lesser cornua* are small, and articulate below with the body at its junction with the great cornua. It often has a cartilaginous nodule at its inferior extremity, the *styloid nucleus*.

The *styloid bones* are long, flattened on the sides, articulating above with the *hyoideal prolongation* of the temporal, below with the *lesser cornua*. They represent the styloid process and stylohyoid ligament of man.

THE STERNUM.

The *sternum* forms the inferior boundary of the thoracic cavity, showing on either side articulations for the first eight ribs. It shows an anterior extremity, the *cervical prolongation*, and a posterior, the *abdominal prolongation* or *xiphoid appendix*.

It is flattened, laterally, in its anterior two-thirds, and from above downwards in its posterior one-third.

Articulations, 16.

With eight anterior ribs on either side.

THE RIBS.

The ribs are 36 in number, 18 on either side, forming the lateral boundaries of the thorax, terminating below by cartilaginous prolongations, the *costal cartilages*. They articulate above with the dorsal vertebræ. They are divided into *sternal* or *true*, eight in number, and *asternal* or *false*, the posterior ten.

General Characteristics.—Each rib has an *external* convex and *internal* concave smooth surface and an *anterior* or *convex* border, a *posterior* border, showing a groove for the intercostal vessels and nerves, a *shaft* and two extremities.

The *superior extremity* articulates with the vertebral column, and shows a *head* with two demi-facets for the bodies of the vertebræ in front and behind, a *neck* below the head, and a *tuberosity* for articulation with a *dorsal transverse* process.

The *inferior extremity* is excavated for the cartilage.

The *costal cartilages* are flattened laterally, the first eight lying on the sternum, the remainder articulating with the cartilage in front.

The *length* of the ribs increases from the first to the 9th, then decreases; their *width* from the 1st to the 6th, then decreases.

The *1st rib* has no outer groove and no notch on its head. Its cartilage is short and thick, and has an articular facet below for the opposite.

The *18th rib* has no external channel, and the facet on its tuberosity is confounded with that of its head.

For *thorax* see *Lungs*.

THE ANTERIOR EXTREMITY.

This is divided into the *shoulder*, *arm*, *forearm* and *forefoot* or *hand*.

THE SHOULDER.

In solipedes this consists of the *scapula* only, the clavicle being absent.

THE SCAPULA.

The *scapula* or shoulder blade is a flat, triangular bone, lying at the anterior and inferior part of the outer thoracic wall, articulating below with the head of the humerus. Its general direction is downward and forward.

It has *two surfaces*, *external* and *internal*, *three angles*, *anterior*

or *cervical*, *posterior* or *dorsal*, and *inferior* or *humeral*, and *three* borders, *anterior*, *posterior*, and *superior*.

The *external surface* shows two cavities, giving attachment to the *antea* and *postea-spinati* muscles, divided by a marked crest, the *spine*, running in its long axis; elevated in its middle, the *tuberosity*.

The *internal surface* is concave, forming the *sub-scapular fossa* for the muscle of the same name.

The *anterior* or *cervical angle* is thin; the *posterior* thick.

The *inferior* or *humeral angle* has a constricted *neck*; below this the *glenoid cavity*, a round, shallow depression, for the *humeral head*.

In front of the cavity is the *coracoid process*, with a *base* and a *summit* curved inwardly.

The *superior border* is prolonged by a well-marked, flattened cartilage.

The *anterior border* is sharp and thin; the *posterior*, thicker and concave.

It *articulates* with the humerus.

THE ARM.

The single bone forming the arm is the *humerus*.

THE HUMERUS.

The *humerus* is a long bone, articulating above with the scapula, below with the ulna and radius. It has a shaft, an upper and a lower extremity.

The *shaft* has—

An *anterior surface*, showing below some muscular imprints.

A *posterior surface*, smooth and rounded.

An *external surface*, which shows a groove, winding from above downward, and behind forward, called the *furrow of torsion*, and is bounded in front by an *anterior crest*, behind by the *posterior crest*.

The anterior crest ends below, at the junction of the upper and middle thirds, in the *deltoid imprint*, a rough and prominent elevation, with a concavity toward the furrow of torsion. The furrow of torsion lodges the *short flexor of the forearm*.

The *internal surface* is rounded, and has, at its middle, a rough depression for the *teres major* and *latissimus dorsi*. The nutrient foramen is at its lower third.

The *superior extremity* has—

A *convex head* for articulation with the glenoid cavity.

An *external or great tuberosity*, which shows a *summit, crest* and *convexity*.

An *internal or small tuberosity*, receiving the insertion of the *subscapularis*.

The *bicipital groove*, between the two tuberosities, and running downward. It consists of two grooves and a central elevation, which allow the passage of the fibro-cartilaginous tendon of the biceps.

The *inferior extremity* has—

A *transversely elongated* articular process, convex from before backward, and divided into two, a larger internal one, the *trochlea*, and a smaller external, the *condyle*; behind and above this a depression, which receives the beak of the olecranon in extension, called the *olecranon fossa*. In front and to the inner side, another, the *coronoid fossa*, which receives the coronoid in flexion. On the inner side, above the trochlea, the *epi-trochlea*, a *bony* elevation. On the outer side, in the same position, the *epi-condyle*.

Articulations, 3.

Scapula, radius and *ulna*.

THE FOREARM.

This consists of two bones, the *radius and ulna*, united into one at an early age.

THE RADIUS.

The *radius* is a long bone articulating above with the humerus, and below with the carpus.

It shows—

An *external and internal border*, thick and rounded.

An *anterior surface*, smooth and convex.

A *posterior surface*, concave, with a rough, triangular surface from the upper to the lower fourth, for attachment of the interosseous ligament; above, a transverse groove, to form the radio-ulnar arch, a rough spot at its inferior third.

The *superior extremity* shows—

An *articular surface*, smooth and concave, divided into a double depression externally, a middle ridge, and an internal depression.

A well-marked *external tuberosity*.

The *internal* or *bicipital tuberosity*, for attachment of the *coraco-radialis*.

Below this, a *transverse groove*, for the *short flexor of forearm*.

The *coronoid process*, a small projection anteriorly.

Two facets, posteriorly, for the ulnar articulation.

The *inferior extremity* shows—

Below, the articulating surface for the four upper carpus.

Two tubercles for ligaments, externally and internally.

Three grooves anteriorly, the two outer ones lodging the anterior *extensors of the phalanges* and *metacarpus*; the internal oblique one, the *oblique extensor*.

A strongly marked *ridge* behind, for ligaments.

Articulations, 6.

Humerus, ulna, pisiform, cuneiform, semi-lunar and *scaphoid*.

THE ULNA.

The *ulna* is a long bone forming the posterior and upper three-fourths of the forearm, and strongly united to the radius.

It has a *shaft*, an *upper* and *lower extremity*.

The shaft is triangular, and has—

An *external* smooth, *internal concave*, and an *anterior* rough surface. The latter shows *two facets* and the *ulnar groove* for the radio-ulnar arch.

There are also two lateral, and a posterior rough, borders.

The *upper extremity* shows—

A superior enlargement, the *olecranon process*, for the attachment of the extensors of the forearm. This has *external* convex and *internal* concave surfaces.

Its anterior portion shows a deep notch, the *sigmoid cavity*, for articulation with the humerus, terminating above in the *beak*.

The *inferior extremity* shows—

A *small knob*, the capitellum, which sometimes reaches to the end of the radius.

Articulations, 2.

The *humerus* and *radius*.

THE FORE-FOOT, OR HAND.

This comprises in the horse the *carpus*, seven in number, three *metacarpus*, three *phalanges* and three *sesamoids*.

THE CARPUS.

The *carpus*, seven in number, are divided into a superior and an inferior row.

The *superior row* are named from without inward—the (1) *pisiform* or *super-carpal*, (2) *cuneiform*, (3) *semi-lunar*, and (4) *scaphoid*.

The *inferior row* are named—

(1) *Unciform*, (2) *os magnum* and (3) *trapezoid*.

The (1) *super-carpal* has an *external convex face*, an *internal concave face* and a *circumference*, free except anteriorly, where it *articulates* with the *radius* and *cuneiform*.

The (2) *cuneiform* is wedge-shaped, and *articulates* with the *radius*, *super-carpal*, *semi-lunar*, and *unciform*.

The (3) *semi-lunar* is half-moon shaped and *articulates* with the *cuneiform*, *scaphoid*, *radius*, *unciform* and *magnum*.

The (4) *scaphoid* is boat-shaped and the largest of the row, *articulating* with the *radius*, *semi-lunar*, *magnum* and *trapezoid*.

The *unciform* is hook-shaped and *articulates* with the *cuneiform*, *semi-lunar*, *magnum*, *external* and *middle metacarpals*.

The (2) *os magnum*, the largest, *articulates* with the *semi-lunar*, *scaphoid*, *unciform*, *trapezoid*, *internal* and *middle metacarpals*.

The (3) *trapezoid*, resembling the same geometrical figure, *articulates* with the *scaphoid*, *magnum*, *middle* and *internal metacarpals*.

THE METACARPUS.

This region consists of three portions, the middle or principal, and two lateral, the external and internal metacarpals.

The *principal metacarpal* shows—

A *shaft*, smooth and rounded in front, flattened behind, with articular surfaces on each side for the rudimentary bones; at its upper third the nutrient foramen.

An *upper extremity* articulating with the inferior carpal row.

An *inferior extremity*, showing two articular condyles separated by a median ridge. On each side are ligamentous depressions.

The *rudimentary metacarpals* (or splint-bones) show a *superior extremity* articulating with the inferior carpal row, an *inferior extremity* extending as far as the lower fourth of the middle bone and ending in a button and a *shaft* with *three surfaces*, an *anterior*, articulating with the middle, *external* and *internal* smooth ones.

The internal is the thicker and longer, and has two articular facets above.

THE PHALANGES.

THE FIRST PHALANX (OR PASTERBONE).

The *first phalanx* lies between the principal metacarpal and the second phalanx, and has a *shaft* and *two extremities*.

The *shaft* has an *anterior convex surface*, a *posterior*, flattened and rough, and two thick borders.

The *upper extremity* has two articular depressions, separated by a ridge.

The *inferior extremity* has two condyles, separated by a groove and laterally two ligamentous depressions.

SECOND PHALANX (OR OS CORONÆ).

The *second phalanx* is a short bone with two *articular depressions* above, two *articular processes* below, an *anterior face* with imprints, and a *posterior face* with a transverse gliding surface.

Articulations.

First phalanx, third phalanx and navicular bone.

THIRD PHALANX (OR OS PEDIS).

The third phalanx supports the hoof and anterior limb. It is somewhat pyramidal in shape, and is divided into *three faces*, *three angles*, and *two lateral borders*.

The *anterior face* is perforated for vessels and shows laterally the pre-plantar fissure between the basilar and retrossal processes; the *patilobe eminence* below the fissure.

The *superior face* shows—

Two *articular cavities* separated by a ridge, for the second phalanx.

The *inferior (or solar) face* shows—

A flat surface below, on which the foot rests, a curved line, the *semi-lunar crest*, and laterally two channels, the *plantar fissures*, opening into a cavity in the interior, the *semi-lunar sinus*.

The *superior border* has its convexity forward, and shows the *pyramidal eminence* for muscular insertion.

The *inferior border* is convex and perforated by foramina.

The *posterior border* shows a facet for the navicular bone.

The *lateral angles* show two posterior projections, a superior, the *basilar*, and inferior, *retrossal* processes. Between the two is the origin of the pre-plantar fissure.

THE SESAMOIDS.

The sesamoids consist of *two superior* or large, and *one inferior*, small or *navicular bone*.

THE LARGE SESAMOIDS.

These are two in number, lying side by side behind the superior part of the first phalanx. Each one is pyramidal, and has an anterior face articulating with the metacarpal, a *posterior*, smooth for the gliding of tendons, a *lateral face*, a *base* and *summit*.

They *articulate* with the metacarpal and first phalanx.

THE NAVICULAR BONE.

The *small sesamoid* bone lies behind the third phalanx, to which it is attached. It is long transversely and narrow, and shows a *superior surface*, articulating with the second phalanx; an *anterior surface*, articulating with the third phalanx; an *inferior surface*, a *posterior border* and two extremities.

THE POSTERIOR EXTREMITY.

This is divided into the *pelvis*, *thigh*, *leg*, and *foot*.

THE PELVIS.

The *pelvis* is a bony cavity containing the sexual organs and termination of the internal tract. It is formed *above* by the *sacrum* *laterally*, and *below* by the *os innominata*.

The *os innominata* are two bones, each one composed of three segments closely fused together. In early life the innominata bones are separate, but they are completely joined as age advances. They consist of three segments, the *ilium*, *ischium* and *pubes*.

THE ILIUM.

The *ilium* is flat and triangular, and corresponds internally to the sides of the sacrum. It has *two surfaces*, *three borders*, and *three angles*. The *external surface* is rough, the *internal surface* shows an external smooth and internal rough portion, the *auricular surface* for articulation with the ilium. The *anterior border*

is rough, the *external* thick and concave, the *internal* thin and concave, forming the *great sciatic notch*.

The *external angle*, or anterior superior spinous process is thick, wide and flat, and called the *angle of the haunch*. The *internal* or *posterior superior spine*, curving backward and upward, is called the *angle of the croup*. The *posterior angle* forms part of the cotyloid cavity; above this cavity is the *supra-cotyloid crest*, two rough points for origin of the *rectus*, and *ilio-pectineal eminence* at the junction with the pubes.

THE PUBIS.

The pubis is flattened from above down, elongated transversely, and has *two surfaces*, *three borders* and *three angles*. It lies inside the ilium and in front of the ischium.

The *superior* or *pelvic surface* forms the pelvic floor, and is smooth and concave.

The *inferior surface* is rough and convex and shows a *groove* for the pubio-femoral ligament.

The *anterior border* is rough, the internal is united with the opposite to form the *symphysis*, and the posterior forms the anterior boundary of the obturator foramen.

The *external* or *cotyloid* angle forms the bottom of the cotyloid cavity.

The *internal* unites with the opposite.

The *posterior* is united with the ischium.

THE ISCHIUM.

The ischium lies behind the pubes and ilium, and is the smallest of the three portions.

It has two surfaces, a *superior* or pelvic, smooth, and an *inferior*, rough, *four borders* and *four angles*.

The *anterior border* bounds the obturator foramen, the *posterior* diverging forms the *sciatic arch*, and shows the *ischiatric spine*.

The *external* is concave, forming the lesser sciatic notch.

The *internal* unites with the opposite to form the *ischial symphysis*.

The *antero-external angle* forms part of the cotyloid cavity; the *antero-internal* unites with the pubis; the *postero-external* forms an enlargement, the *tuberosity*; the *postero-internal* unites with the opposite.

The *cotyloid cavity* (or *acetabulum*) is a deep excavation, at the

junction of the three bones, with a narrow rim above, and incomplete below, where it communicates with the sub-pubic notch. It receives the femoral head.

The *obturator* (or *oval*) foramen is composed of the pubis and ischium, and forms part of the lower pelvic boundary, when closed in by the *external* and *internal obturator* muscles.

THE PELVIS.

This cavity has an *inlet* bounded above by the sacrum, below by the pubes, laterally by the ilia.

It has four diameters, a *vertical*, from the sacrum to the anterior pubic symphysis, of $8\frac{1}{4}$ inches, a *horizontal*, between the pectineal eminences, of $8\frac{6}{10}$ inches, and two *oblique*, from the sacro-iliac joints to the pectineal eminences, of $8\frac{7}{10}$ inches.

It also has an *outlet* through which pass the rectum and genital organs, bounded *above* by the summit of the *sacrum*, *below* by the upper surface of the ischia, *laterally* by the sacro-ischiatic ligaments.

It has two diameters, a *vertical*, of $6\frac{7}{10}$ inches, from the sacrum to the ischium, and a *transverse*, of $7\frac{7}{10}$ inches, between the supracotyloid crests.

The pelvis of the mare is much more roomy than that of the male, being more marked in its transverse diameters.

THE THIGH.

This consists of one bone, the femur.

THE FEMUR.

The femur lies between the pelvis above and the tibia below, having a general direction downward and forward.

It has a *shaft* and *upper* and *lower extremities*.

The *shaft* has—

An *external*, *anterior* and *internal face*, all smooth and convex, and a *posterior*, rough and irregular.

The *posterior face* shows in its upper one-third internally a rough elevation, the *lesser* or *internal trochanter*, a rough surface for the attachment of the pectineus and adductor magnus, below a deep groove and a number of rough elevations, the *supra-condyloid* crest; in its upper third rough lines and crests.

The *upper extremity* shows—

The *head* articulating with the *acetabulum*, forming two-thirds of a sphere and a constriction externally, the *neck*.

The *great* or *external trochanter*, outside and above, with a *summit*, *convexity* and *crest*.

The *digital* or *trochanterian* fossa, behind and below, receiving the obturator muscles.

The *inferior extremity* is flattened laterally and shows—

The *external* and *internal condyles*, separated by a notch behind, with depressions for the *crucial ligaments*.

The *trochlea*, a wide, smooth surface between the condyles anteriorly, on which the patella glides.

A *fossa* for muscular insertion outside the preceding.

Rough spots outside each condyle, for muscular and ligamentous insertion.

Articulations, 3.

Os innominata, *patella* and *tibia*.

THE LEG.

This consists of three bones, the *tibia*, *fibula* (or *peroneus*) and *patella* (or knee-pan).

THE TIBIA.

The tibia is a long bone. Its general direction is downward and backward, and has a *shaft* and *upper* and *lower extremity*.

The shaft has *three borders* and *three surfaces*.

The *anterior border* is sharp above, and known as the tibial crest.

The *external border* is concave above, forming part of the tibial arch. The *internal border* is thick.

The *external surface* is concave above, convex below, giving origin to the fleshy part of the *flexor of the metatarsus*.

The *internal surface* presents above, muscular imprints for the *adductors* and *semi-tendinosus*.

The *posterior surface* is divided, by an oblique line, into two portions, the upper giving attachment to the *popliteus*, the lower to the *perforans*.

The *superior extremity* shows—

An *anterior tuberosity*, separated from the external by the groove

for the tendon of the *flexor of the metatarsus*. It has a depression in front for the middle patellar ligament.

The *external tuberosity*, with a facet for the fibular head.

The *internal tuberosity*, with ligamentous imprints.

Above, *two oval depressions* for the condyles of the femur; the external is the wider. Between the two an eminence, the *spine*, for attachment of ligaments and cartilages.

The *inferior extremity* shows—

An *external tuberosity*, with a vertical fissure for the *lateral extensor of the phalanges*.

An *internal tuberosity*, with an oblique channel for the *oblique flexor of phalanges*.

An *articular surface* for the astragalus, two antero-posterior depressions, separated by a median elevation.

Articulations, 4.

Femur, patella, fibula and astragalus.

THE FIBULA OR PERONEUS.

The *fibula* is a rudimentary bone lying outside the tibia and articulating with it alone.

It has a *superior* and *inferior extremity* and *shaft*.

The *superior extremity* is called the *head*, and shows *internally* an articular facet for the tibia, *externally* rough elevations for ligaments.

The *inferior extremity* ends in a blunt point at the end of the upper third of the tibia.

The *shaft* is thin and small, forming the outer side of the tibial arch.

THE PATELLA.

The patella is a sesamoid bone, developed in the tendon of the *triceps extensor* and strongly attached to the tibia by three ligaments.

It has a *superior face*, rough, for attachment of the *extensor cruris*. An *anterior*, convex, and a *posterior*, covered with cartilage and divided by a median ridge into an *external* and *internal articular facet*, the latter the larger, and both articulating with the femoral trochlea.

Articulations, 2.

Femur and tibia.

THE FOOT.

This is divided into the *tarsus*, *metatarsus* and bones of the *digit*.

THE TARSUS.

The *tarsus* corresponds to the carpus of the anterior foot, and consists of six or seven segments.

These segments are divided into two rows: an upper and lower. In the former, in front, is the *astragalus*, behind the *os calcis*; in the latter, outside, is the *cuboid*, inside, above, the *scaphoid*, below the *large* and *small cuneiforms*. There are sometimes three cuneiforms, making seven segments.

THE ASTRAGALUS.

The *astragalus* lies between the tibia above, the scaphoid below, and the calx behind.

It has *external* and *internal* rough faces, a *posterior* with facets for the *os calcis*, an *inferior* convex for the articulation with the scaphoid and a *superior* and *anterior* with two articular elevations and a depression for the tibial articular surface.

Articulations, 4.

Tibia, *os calcis*, *scaphoid* and *cuboid*.

THE OS CALCIS OR CALCANEUS.

The *os calcis* is elongated, lying behind the astragalus, above the cuboid, and forming the summit of the tarsus. It shows—

A convex *outer surface* and concave *inner*, forming the *tarsal arch*.

A concave *anterior* and thick *posterior* border.

A *superior extremity* with a rough spot for insertion of the *gastrocnemius*, a smooth surface on which the tendon plays, and behind another for the gliding of the *perforatus*.

The *inferior extremity* shows articular facets for the *astragalus* and *cuboid*.

Articulations, 2.

Astragalus and *cuboid*.

The *cuboid* is irregularly quadrilateral in shape, and articulates with the *calcaneus*, *astragalus*, *scaphoid*, *middle* and *external metatarsals*, and *large cuneiform*.

The *scaphoid* is boat-shaped, articulating with four; the *astragalus* above, *cuneiforms* below, and the *cuboid* externally.

The *great cuneiform* (wedge-shaped), lies inside the *cuboid*, articulating with it, the *small cuneiform*, *scaphoid*, *middle* and *internal metatarsals*.

The *small cuneiform* lies on the inner side of the tarsus, articulating with the *scaphoid*, *large cuneiform*, *middle* and *internal metatarsals*.

THE METATARSUS.

The *median* is longer and larger than that in the anterior extremity. The *external* is longer and thicker than the *internal* which has two facets above for the tarsus.

THE DIGITAL REGION.

The *first phalanx* is shorter, the *second* narrower, the *third* narrower, more V-shaped, the sesamoid smaller, and the *navicular* shorter and narrower than the corresponding bones of the anterior foot.

ARTHROLOGY.

The **articulations** are divided into three classes:

1. *Synarthroses* or immovable joints.
2. *Amphiarthroses* or limited in motion.
3. *Diarthroses*, freely movable joints.

Synarthroses are further divided into—

- (a) *Schindylesis*, a bony plate received into a groove.
- (b) *Gomphosis*, a conical process in a socket.
- (c) *Sutura* or by indentation, which are again divided into *sutura vera* and *sutura notha*.
 - (d) *Sutura vera*, *true sutures*.
 - Sutura dentata*, tooth-like processes.
 - S. serrata* with saw-like processes.
 - S. limbosa* with beveled margins and dentated processes.
 - (e) *Sutura notha*, *false sutures*.
 - S. harmonia* by opposed rough surfaces.
 - S. squamosa* with overlapping bony tables.

Diarthroses are divided again into—

Arthrodial, or gliding joints.

Enarthrodial, or ball and socket.

Ginglymus, or hinge-like.

Diarthrosis rotatoria, or a pivot which turns in a cavity.

Condylloid, one or more condyles received in oval excavations.

Examples.

S. dentata.—Intra-parietal suture.

S. serrata.—Inter-frontal suture.

S. limbosa.—Fronto-parietal suture.

S. harmonia.—Occipito-temporal suture.

S. squamosa.—Parieto-temporal suture.

Amphiarthroses.—Bodies of vertebræ, sacro-iliac joints.

Arthrodial.—Carpo-metacarpal joints.

Enarthrodial.—Hip and shoulder joints.

Ginglymus.—Hock and humero-radial joints.

Diarthrosis rotatoria.—Atlo-axoid joint.

Condylloid.—Temporo-maxillary and knee-joints.

Structures entering into joints are—

Articular lamellæ of bone, ligaments, cartilage, fibro-cartilage, synovial membrane and synovia.

Movements of joints are—

Flexion, extension, abduction, adduction, external rotation, internal rotation, circumduction and gliding.

Articulations of vertebral column—

1. *Common superior vertebral ligament*, lies above bodies of vertebræ, and attached to them from the axis to the sacrum.

2. *Common inferior vertebral ligament*, lies below bodies, and attached to them from sixth or eighth dorsal to sacrum.

3. *Interarticular fibro-cartilage*, between the bodies of the vertebræ, except between atlas and axis.

4. *Capsular*, between articular processes.

5. *Inter-transverse*, between transverse processes.

6. *Inter-lamellar*, between laminæ.

7. *Inter-spinous*, between spinous processes.

8. *Supra-spinous*, between tips of spinous processes.

Ligamentum nucha is the continuation of the supra-spinous ligament from the first dorsal to the occiput; it supports the head.

In the sacral and coccygeal regions the articulations are more or less fused or rudimentary.

the interarticular fibro-cartilage
process of the last lumbar articu-
crum.

articulate between their *trans-*

are—

otion, free in the cervical but

ICULATION.

s of axis to corresponding de-

ior arch of atlas.

Superior anto-axoid, between spines.

Inferior atlo-axoid, below bodies.

Capsular ligaments (two), between articular processes.

Action.

Lateral rotation.

OCCIPITO-ATLOID.

Ligaments.

Two capsular.

Two lateral, from transverse process to occiput.

Action.

(Condylod,) extension, flexion and lateral inclination.

TEMPORO-MAXILLARY.

(*Double condyloid joint.*)

Ligaments.

Capsular, from margins of glenoid cavity to neck of condyle of inferior maxilla.

Interarticular fibro-cartilage moulded on condyle.

Two synovial membranes, one above, one below cartilage.

Action.

Depression, elevation, lateral motion and gliding.

HYOID.

Two *elastic cartilages*, between styloid bone and temporal.

Two *capsular ligaments*, between body and lesser cornua.

Motion.

Amphiarthrodial.

THORAX.

COSTO-VERTEBRAL.

Two convex facets on head of ribs and two depressions in vertebræ, in front and behind, also in the intervertebral substance.

Ligaments.

Interarticular, from head of rib to intervertebral disk, none in first, and sometimes not in second articulation.

Inferior (stellate), of three fasciculi, running to vertebræ in front and behind and intervertebral substance.

Two *capsular ligaments*, one in front and one behind the inter-articular ligament.

COSTO-TRANSVERSE.

Between facet on tuberosity of rib and dorsal transverse processes.

Anterior costo-transverse or *interosseous*.

Posterior costo-transverse.

One synovial membrane.

CHONDRO-STERNAL.

Eight upper ribs, with sternum, by cartilages.

Superior chondro-sternal.

Inferior chondro-sternal.

The articulations of the first two ribs run into each other.

CHONDRO-COSTAL.

Implantation of a cartilage, on the one in front, by means of diarthrodial facets.

Their movements are obscure.

ANTERIOR LIMB.

SCAPULO-HUMERAL.

Enarthrodial joint, between the head of humerus and glenoid cavity of scapula.

Ligaments.

A rudimentary *glenoid* ligament, deepening the cavity.

Capsular ligament, from margins of cavity to neck of humerus.

Two supporting fasciculi from coracoid process to head of humerus.

The *muscles* in relation to joint are—

1. *In front*, coraco-radial.
2. *Behind*, large extensor of forearm and teres minor.
3. *Outside*, short abductor of arm and *postea spinatus*.
4. *Inside*, *subscapularis*.

Action.

Abduction, adduction, flexion, extension, rotation and circumduction.

HUMERO-RADIAL.

Ginglymus, between inferior extremity of humerus and upper extremity of ulna and radius.

Ligaments.

Anterior, from humerus above articular surface to anterior part of radius.

External lateral, from cavity outside of humerus to external portion of radius.

Internal lateral, inner tuberosity of inferior extremity of humerus, to radial tuberosity and to interosseous fibres.

Action.

Flexion and extension.

RADIO-ULNAR.

Two facets and rough surfaces on each bone.

Ligaments.

Two *interosseous*, the lower always ossifies, the upper rarely.

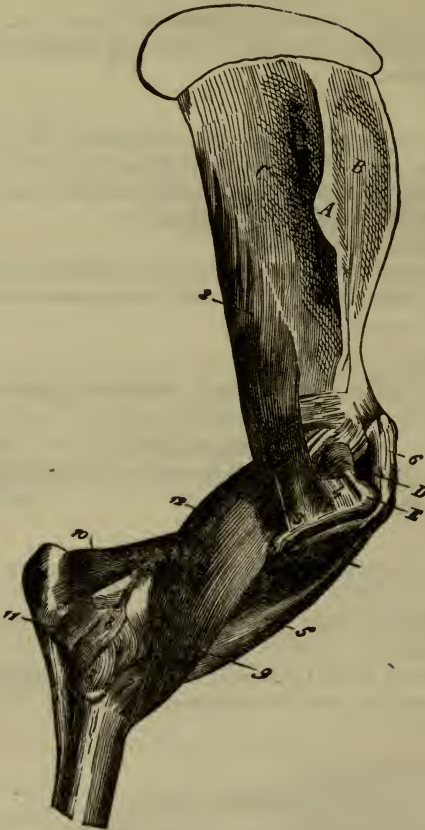External peripheral band.

Internal peripheral band.

Action.

Very little in youth, none when consolidated.

FIG. 2.



SCAPULO-HUMERAL AND HUMERO-RADIAL ARTICULATIONS, WITH THE MUSCLES SURROUNDING THEM (EXTERNAL FACE).

- 1, Scapulo-humeral capsular ligament; 2, Short abductor muscle of the arm; 3, Its insertion in the humerus; 4, Insertion of the subspinous muscle on the crest of the great tuberosity; 5, Coraco-radial muscle; 6, Its tendon of origin attached to the coracoid process; 7, Its radial insertion confounded with the anterior ligament of the ulnar articulation; 8, 8, External lateral ligament of that articulation; 9, Anterior ligament; 10, Anconeus, or small extensor of the forearm; 11, Origin of the external flexor muscle of the metacarpus; 12, Short flexor muscle of the forearm.—A, Tuberosity of the scapular spine.—B, Superspinous fossa.—C, Subspinous fossa.—D, Convexity of the small trochanter.—E, Summit of the trochanter.

RADIO-CARPAL.

Lower articular surface of radius with four upper carpal bones.

Ligaments.

Internal, from radius to fourth bone.

Superficial external, radius to supercarpal bone.

Deep external, radius to second bone and interosseous ligament.

Action.

Imperfect ginglymus.

CARPUS.

First row with each other.

Three *anterior* and three *interosseous* running in front of and between bones.

Second row with each other.

Two *anterior* and two *interosseous*.

First and second rows with each other.

Ligaments.

External posterior, from first of upper to second bone of lower row.

Internal posterior, from internal bone of upper row to second and third of metacarpal row.

External, from supercarpal to first bone of second row and head of external metacarpal.

Action.

Imperfect ginglymus.

CARPO-METACARPAL.

Between three lower carpus and three metacarpus, forming a planiform diarthrosis.

Ligaments.

Two *anterior*, one between second bone and principal metacarpal; the other from the first to external metacarpal.

Two *interosseous*, from articulations between metacarpus to interosseous ligaments of second row.

COMMON CARPAL LIGAMENTS.

1. *Anterior*, from radius to principal metacarpal.

2. *Posterior*, posterior part of radial surface to carpus and principal metacarpal.

3. *External lateral*, from outer side of radius to first bones of upper and lower rows and outer metacarpal bone.

4. *Internal lateral*, from inner side of the radius to principal and inner metacarpal as well as into carpus.

METACARPO-PHALANGEAL.

Ginglymus joint between end of metacarpal bone and first phalanx, with the two upper sesamoids.

Ligaments.

Inter-sesamoid, between two sesamoids.

Lateral sesamoid, between sides of sesamoids and upper extremity of first phalanx.

Inferior sesamoid, of three fasciculi, from posterior surface of first phalanx to sesamoids.

External and internal lateral, from metacarpal to sides of first phalanx.

Anterior, between anterior surfaces of both bones.

Posterior or suspensory ligament of the fetlock, from first and second bone of inferior carpal row and posterior face of principal metacarpal to top of sesamoids, divides into two fasciculi which pass forward and are inserted into the anterior extensor of the phalanges.

Movements.

Flexion and extension.

FIRST INTER-PHALANGEAL ARTICULATION.

Imperfect ginglymus between first and second phalanges.

Ligaments.

Two *lateral ligaments* between sides of bones.

One *posterior ligament* or glenoidal fibro-cartilage attached to the first and second phalanges by six bands. It increases the articular surface below and forms a sheath for the passage of the *perforans* tendon, being in relation to the *perforatus* at its side.

Movements.

Flexion, extension and some lateral motion.

SECOND INTER-PHALANGEAL ARTICULATION.

Imperfect ginglymus, between second and third phalanges.

Ligaments.

Interosseous, between navicular and pedal bones.

Two *anterior lateral*, from anterior surfaces.

Two *posterior lateral*, from anterior surfaces.

Movements.

Same as preceding.

POSTERIOR EXTREMITY.

SACRO-ILIAC.

An *amphiarthrosis*, between auricular surface of sacrum and side of ilium.

Ligaments.

Sacro-iliac, about margins of articulation.

Superior ilio-sacral, from internal angle of ilium to sacral spine.

Inferior ilio-sacral, with preceding and inserted into sides of sacrum.

Movements.

Slight gliding.

Sacro-iliac ligament, from sides of sacrum by its *superior border* into super-cotyloid crest and ischial border by its *inferior border*, forming, with the *lesser sciatic notch*, the opening by which the *internal obturator* and *pyramidal* muscles leave the pelvis.

An *anterior border* forms the *greater sciatic foramen* with the notch, and through it pass the *gluteal* and *sciatic* vessels and nerves.

A *posterior border* which embraces the *semi-membranosus* muscle.

ISCHIO-PUBIC SYMPHYSIS.

In young animals is a true amphiarthrosis.

In adult life bones are fused together.

COXO-FEMORAL OR HIP JOINT.

An *enarthrodia* between the cotyloid cavity and the head of the femur.

Ligaments.

Capsular, from margins of cotyloid cavity to neck of femur.

Transverse, converting notch into a foramen.

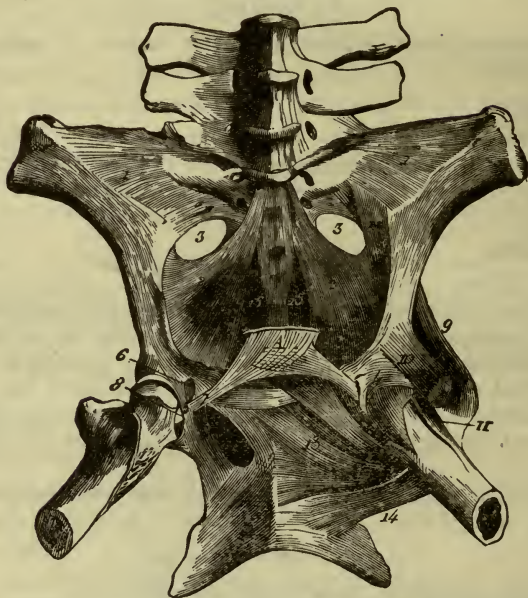
Cotyloid, deepening the cavity.

Coxo-femoral (ligamentum teres) from bottom of cotyloid cavity to a depression in head of femur.

Pubo-femoral, from inferior face of pelvis, to be inserted with the preceding.

Synovial membrane, very extensive.

FIG. 3.



SACRO-ILIAC AND COXO-FEMORAL ARTICULATIONS, WITH THE SMALL DEEP MUSCLES SURROUNDING THE LATTER.

- 1, Sacro-iliac ligament; 2, Sacro-ischiatic ligament; 3, Great ischiatic notch; 4, Anterior portion of the capsular ligament of the coxo-femoral articulation; 5, Internal band of cotyloid ligament; 6, Coxo-femoral ligament; 7, Pubio-femoral ligament; 8, Its insertion into the femur; 9, Small gluteal muscle; 10, Origin of the straight anterior muscle of the thigh (rectus); 11, Anterior thin muscle (rectus parvus); 12, Pyramidal muscle of the pelvis; 13, External obturator muscle; 14, Square crural muscle (quadratus femoris); 15, Inferior sacro-coccygeal muscle.

Muscles in relation to joint;—

In front.—Gracilis and rectus.

Behind.—Gemelli, internal obturator and pyramidalis.

Below.—Ext. obturator.

Above.—Small gluteal.

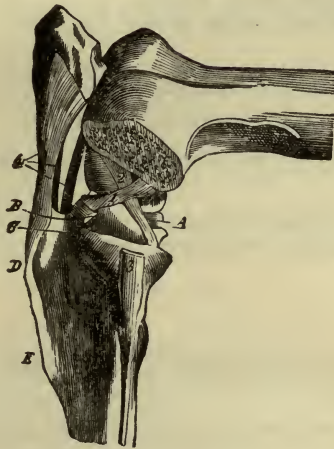
Action.

Same as shoulder.

FEMORO-TIBIAL ARTICULATION.

A *condyloid* joint between the femur above, tibia below and patella in front.

FIG. 4.



No. 2. External face; the external condyle of the femur and the meniscus have been removed to show the crucial ligaments.—1, Anterior crucial ligament; 2, Posterior ditto; 3, Fibular insertion of the external lateral ligament; 4, Anterior patellar ligaments.—A, Internal meniscus; B, Anterior insertion of the external meniscus; C, Passage for the tendinous cord common to the flexor of the metatarsus and the anterior extensor of the phalanges; D, Anterior and superior tuberosity of the tibia; E, Tibial crest.

Ligaments.

Anterior or *ligamentum patellæ* of three strong fasciculi from patella to the anterior surface of the tibia.

Ante-patellar aponeurosis, an expansion of the fascia lata binding patella to the femur by two lateral fasciculi.

External lateral, from external condyle to head of fibula.

Internal lateral, from internal condyle to inner tibial tuberosity.

Posterior, from posterior face of femur to tibia. In relation to external gastrocnemius and popliteal artery.

Crucial.

(a) *Anterior* or *external* from front of tibial spine to inner side of external condyle.

(b) *Posterior* or *internal*, in opposite direction.

Interarticular fibro-cartilages (or menisci), (a) *right* and (b) *left* attached to tibial spine, and by fasciculi to femur and tibia.

Synovial membrane.

(a) *Middle* portion under patella.

(b) *Lateral portions* under lateral ligaments.

Action.

Flexion, extension and rotation on menisci.

TIBIO-FIBULAR ARTICULATION.

A *planiform diarthrosis*, between tibia and fibula.

Ligaments.

Two *lateral fasciculi*, from sides of fibula to tibia.

Interosseous, between two bones, leaving a space called tibio-fibular arch.

Action.

Limited.

HOCK OR TARSAL ARTICULATION.

Tibio-tarsal.

A *ginglymus*, between lower end of tibia and astragalus.

Ligaments.

Anterior.—From front of tibia to astragalus, scaphoid, great cuneiform bones and astragalo-metatarsal ligament.

Internal lateral.

(a) *Superficial fasciculus*, from inner extremity of tibia to sides of tarsus and metatarsus.

(b) *Middle fasciculus*.

Tibial tuberosity to astragalus and calx.

(c) *Deep fasciculus*.

From tibia to astragalus.

External lateral.

(a) *Superficial* portion, from tibia to sides of tarsus and metatarsus.

(b) *Deep portion*, from tibia to astragalus and calx.

Action.

Flexion and extension.

Calcaneo-astragaloid.

A *compound diarthrodia* between three or four facets on astragalus, with same on calx.

Ligaments.

Superior, external lateral, internal lateral and *interosseous*, running from one bone to another, as their names imply.

Action.—Very limited.

Second row of tarsus with each other. Between scaphoid, cuboid and two cuneiforms.

Ligaments.

Two anterior, the *cuboido-cunean* and *cuboido-scaphoid* and two corresponding *interosseous*.

An *interosseous scaphoid-cunean* and *inter-cunean*.

Action.—Very limited.

Two rows of tarsus with each other.

Ligaments.

Two *lateral ligaments* of tibio-tarsal joint.

Calcaneo-metatarsal, from posterior border of calx to cuboid and head of external metatarsal.

Astragalo-metatarsal, from inner side of astragalus to scaphoid, great cuneiform and middle metatarsal.

Posterior tarso-metatarsal from all of tarsus to top of metatarsus.

One *interosseous*, between four bones.

Action.—Very limited.

Tarso-metatarsal.

Between cuboid and cuneiform above, and metatarsal below.

Ligaments.

Those previously described and one strong *interosseous*.

Synovial sacs of tarsus.

1. *Membrane of tibio-tarsal articulation*, communicates in front with that between the two rows, and behind with the superior articulation of astragalus with calx.

2. One for articulation, between scaphoid and great cuneiform, and also to the cuboido-scaphoid and posterior cuboido-cunean.
3. That between two rows, which has communications as above, and with anterior cuboido-scaphoid joint.
4. That of tarso-metatarsal articulation which ascends into anterior cuboido-cunean joint between cuneiform and down into inter-metatarsal articulation.

MYOLOGY.

THE MUSCLES.

The *muscles* are the active portions of the *locomotory* apparatus, and form one-half of the body's weight.

They are divided into *striated* or *striped* and *unstrained* or *unstriped*. The former are *voluntary* and the latter *involuntary*.

The *striped muscles* consist of *fibres* divided into *fibrillæ*, the whole being surrounded by a membrane, the *perimysium*. The *fibrillæ* are composed of small portions, the *sarcous elements*, attached to each other end to end. Between the *fibrillæ* is more or less interstitial substance.

The *unstriped muscles* are found in the viscera as the intestine and consist of fusiform cells, each with a distinct nucleus and bound together by connective tissue.

Appendages of Muscles.

These are *tendons*, *fasciæ* and *aponeuroses*.

Tendons are round, or flattened, white cords at the termination of muscles, composed of condensed white fibrous tissue.

Aponeuroses are flattened bands connected with, or the terminations of, the broad muscles, and composed of white fibrous tissue.

Fasciæ are strong processes of the same structure, forming sheaths and coverings for the muscles.

Bursæ are thin bags filled with mucous or serous fluid, and placed on bony points over which muscles glide. Their office is to prevent friction.

Sheaths of tendons are composed of fibrous tissue, forming depressions or compartments in which tendons glide. When complete they are called vaginal. They may be lined with *synovial membrane*.

MUSCLES OF FACE.

ORBICULARIS ORIS.

Origin.—No bone attachment; confounded with buccinator and other muscles in vicinity.

Insertion.—About oral orifice.

Action.—To close oral orifice.

Nerve.—Facial.

BUCCINATOR.

Origin.—Maxillary tuberosity, above posterior three molar teeth of superior maxilla and from interior maxilla, behind last molar.

Insertion.—Into orbicularis.

Action.—Compresses cheeks.

Nerve.—Buccal, from fifth.

ZYGOMATICO-LABIALIS.

Origin.—From outer surface of masseteric fascia.

Insertion.—On surface of buccinator.

Action.—Retraction of lips.

Nerve.—Facial.

LACHRYMO-LABIAL.

Origin.—Outer surface of lachrymal and malar bones.

Insertion.—Into buccinator fascia.

Action.—To corrugate skin of lower lid.

Nerve.—Facial.

SUPER-NASO-LABIALIS.

(*Levator labii superioris et alæque nasi* of man.)

Origin.—Frontal and nasal bones.

Insertion.—Anterior division into external wing of nose and buccinator, posterior into angle of lips; between divisions passes the super-maxillo-labialis magnus.

Action.—Raises wing of nose and upper lip.

Nerve.—Facial.

SUPER-MAXILLO-LABIALIS.

Origin.—Outer surface of super-maxillary and malar bones.

Insertion.—With opposite into fascia of upper lip.

Action.—Raises upper lip, or singly carries it to one side.

Nerve.—Facial.

SUPER-MAXILLO-NASALIS MAGNUS.

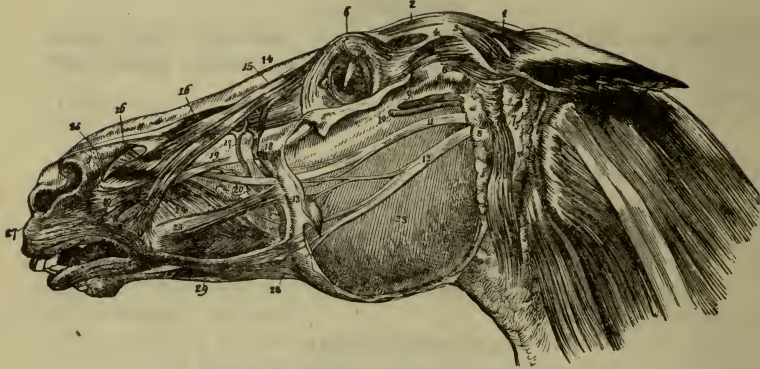
Origin.—Below ridge on superior maxilla.

Insertion.—Skin of external wing of nostril.

Action.—Dilates anterior nares.

Nerve.—Facial.

FIG. 5.



SUPERFICIAL MUSCLES OF THE FACE AND HEAD.

- 1, Temporo-auricularis externus, or attollens maximus; 2, Levator palpebræ, or corrugator supercili; 3, Temporo-auricularis internus, or attollens posterior; 4, 5, Zygomatico-auricularis, or attollens anterior; 6, Orbicularis palpebrarum; 7, Parotido-auricularis, or deprimens aurem; 8, Parotid gland; 9, Temporal, or subzygomatic vein; 10, Ditto, artery; 11, 12, Superior and inferior maxillary nerves; 13, Fascia of the masseter muscle; 14, Nasal bones; 15, Super-naso labialis, or levator labii superioris alæque nasi; 16, Super-maxillo-labialis, or nasalis longus labii superioris; 17, External maxillary or facial artery; 18, Facial vein; 19, Super-maxillo-nasalis magnus, or dilator naris lateralis; 20, Superior maxillary nerve; 21, Zygomatico-labialis, or zygomaticus; 22, Parotid, or Steno's duct; 23, Masseter; 24, Alveolo-labialis, or buccinator; 25, Super-maxillo-nasalis parvus, or nasalis brevis labii superioris; 27, Labialis, or orbicularis oris; 28, Maxillo-labialis, or depressor labii inferioris; 29, Mento-labialis, or levator menti.

SUPER-MAXILLO-NASALIS MINOR.

Origin.—External process of pre-maxilla and superior maxilla.

Insertion.—Skin and cartilage of nostril.

Action.—Dilatation of nostril.

Nerve.—Facial.

TRANSVERSALIS NASI.

Runs from one internal ala of nose to the other.

Action.—To dilate nostrils.

Nerve.—Facial.

ANTERIOR INTERMEDIATE.

Origin.—Facial surface of pre-maxilla above incisors.

Insertion.—With maxillo-nasalis minor into inferior turbinated bone.

Action.—Dilation of anterior nasal entrance.

Nerve.—Facial.

MAXILLO-LABIALIS.

Origin.—Inferior maxilla behind last molar.

Insertion.—Skin of lower lip.

Action.—Depresses lower lip, or singly moves it laterally.

Nerve.—Facial.

POSTERIOR INTERMEDIATE.

Origin.—Outer surface of inferior maxilla beneath incisors.

Insertion.—Into fibers of orbicularis oris.

Action.—Elevates lower lip.

Nerve.—Facial.

MASSETER.

Origin.—Zygomatic process of temporal.

Insertion.—Outer surface of ramus of jaw.

Action.—Elevator of jaw.

Nerve.—Inferior maxillary of fifth.

TEMPORAL.

Origin.—From temporal fossa, temporal fascia and outer border of orbit.

Insertion.—Coronoid process and ramus of inferior maxilla.

Nerve.—Buccal branch of fifth.

EXTERNAL PTERYGOID.

Origin.—Under surface of sphenoid and pterygoid process.

Insertion.—Neck of condyle of maxilla.

Action.—To pull inferior maxilla forward, alone to cause lateral motion, as in grinding food.

Nerve.—Buccal branch of fifth.

INTERNAL PTERYGOID.

Origin.—Palatine crest and pterygoid process.

Insertion.—In hollow of maxillary ramus.

Action.—Elevates and moves jaw laterally.

Nerve.—Inferior maxillary of fifth.

DIGASTRIC.

Origin.—Posterior belly from styloid process of occipital bone; tendon passes through fibrous ring of insertion of stylo-hyoideus into hyoid.

Insertion.—Into posterior border and internal face of inferior maxilla.

Action.—Raises hyoid bone or depresses lower jaw.

Nerve.—Facial.

MYLO-HYOID.

Origin.—Mylo-hyoid ridge of inferior maxilla.

Insertion.—Body of hyoid and anterior appendix and median raphé between two muscles.

Action.—Same as above and also elevates tongue.

Nerve.—Inferior maxillary of fifth.

GENIO-HYOID.

Origin.—Genial surface of inferior maxilla.

Insertion.—Extremity of hyoideal appendix.

Action.—Draws hyoid forward and upward.

Nerve.—Hypoglossal.

STYLO-HYOID.

Origin.—Superior angle of styloid bone.

Insertion.—Base of hyoideal cornua.

Action.—Antagonizes former; carries hyoid up and back.

Nerve.—Facial.

KERATO-HYOID.

Origin.—Posterior border of styloid cornu and inferior extremity of hyoid bone.

Insertion.—Superior border of thyroid cornua.

Action.—Approximates two cornua.

Nerve.—Hypoglossal.

* OCCIPITO-STYLOID.

Origin.—Styloid process of occipital.

Insertion.—Horizontal portion of posterior border of the styloid bone.

Action.—Depresses inferior extremity of hyoid.

Nerve.—Facial.

TRANSVERSUS HYOIDEI.

Runs between superior extremities of styloid cornua.

Action.—Approximates styloid cornua.

Nerve.—Hypoglossal.

TONGUE.

STYLO-GLOSSUS.

Origin.—Outer surface of lower extremity of styloid bone.

Insertion.—Side and tip of tongue.

Action.—Pulls tongue up and backward or to one side alone.

Nerve.—Hypoglossal.

HYO-GLOSSUS MAXIMUS.

Origin.—Side of appendix, body and great cornua of hyoid.

Insertion.—Lateral borders of tongue.

Action.—Retracts tongue and depresses its base.

GENIO-GLOSSUS.

Origin.—Posterior surface of body of lower jaw, near symphysis.

Insertion.—Under surface of tongue.

Action.—Pulls tongue forward or depresses it.

Nerve.—Hypoglossal.

HYO-GLOSSUS MINIMUS.

Origin.—Body of hyoid near small branch.

Insertion.—Into base of tongue.

Action.—Contracts and retracts tongue.

PALATE.

PALATO-GLOSSUS.

Origin.—From lateral wall of pharynx.

Insertion.—Into side of tongue between hyo- and genio-glossi.

Action.—Elevates tongue.

Nerve.—Superior maxillary division of fifth and Meckel's ganglion.

PALATO-PHARYNGEUS.

Origin.—From soft palate.

Insertion.—Side of pharynx and superior border of thyroid cartilage.

Action.—Makes tense and elevates free border of palate.

Nerve.—Superior maxillary division of fifth and Meckel's ganglion.

PALATO-STAPHYLEUS.

Origin.—Uvular aponeurosis with opposite.

Insertion.—Into free border of soft palate.

Action.—Pulls palate upward and forward.

Nerve.—Posterior palatine.

PERI-STAPHYLEUS EXTERNUS (TENSOR PALATI)

Origin.—Styloid process of temporal.

Insertion.—Winds around pterygoid trochlea, changes its direction and spreads out into soft palate.

Action.—Tensor of soft palate.

Nerve.—Posterior palatine.

PERI-STAPHYLEUS INTERNUS (LEVATOR PALATI).

Origin.—With preceding.

Insertion.—Into palato-pharyngeus and soft palate.

Action.—Elevator of soft palate.

Nerve.—Posterior palatine.

PHARYNX.

PALATO-PHARYNGEUS.—See above.

PTERYGO-PHARYNGEUS (SUPERIOR CONSTRICTOR).

Origin.—Pterygoid process.

Insertion.—Into median raphé, with opposite, and hyoid and thyroid cartilage.

Action.—Constricts pharynx and raises larynx.

HYO-PHARYNGEUS (FIRST MIDDLE CONSTRICTOR).

Origin.—Cornua of hyoid.

Insertion.—Median raphé.

THYRO-PHARYNGEUS (SECOND MIDDLE CONSTRICTOR).

Origin.—External surface of thyroid cartilage.

Insertion.—Median raphé.

CRICO-PHARYNGEUS (INFERIOR CONSTRICTOR).

Origin.—Superficial face of cricoid.

Insertion.—Median raphé.

Action.—With three above, as constrictors of pharynx.

Nerves.—Glosso-pharyngeal, pneumogastric, sympathetic.

STYLO-PHARYNGEUS.

Origin.—Great throideal cornua.

Insertion.—Sides of pharynx.

Action.—Elevates and dilates pharynx.

Nerves.—Same as preceding.

TRUNK.

FLESHY PANNICULUS.

Origin.—From flank to posterior border of olecranian mass of muscles and pectoralis major.

Insertion.—One layer to anterior limb and one to small trochanter.

Nerve.—Subcutaneous thoracic.

CERVICAL REGION.—RHOMBOIDEUS.

Origin.—First, fourth or fifth division vertebræ by spinous processes.

Insertion.—Scapular cartilage.

Action.—Draws shoulder upward and forward.

Nerve.—Sixth cervical.

LEVATOR ANGULI SCAPULÆ.

Origin.—Transverse processes of last five cervical vertebræ.

Insertion.—Anterior triangular surface in inner face of scapula.

Action.—Draws scapula forward and upward. If scapula is fixed, inclines neck to side.

Nerve.—Sixth cervical.

SPLENIUS.

Origin.—To lip of cervical ligament and first dorsal vertebræ.

Insertion.—Into mastoid crest with small complexus, transverse processes of atlas and third, fourth and fifth cervical vertebræ.

Action.—Extends head and neck or draws them to side.

Nerve.—Superficial cervical.

GREAT COMPLEXUS.

Origin; Anterior Portion.—Transverse processes of first and second dorsal vertebræ, and articular tubercles of cervical vertebræ.

Posterior Portion.—From spinous process of first dorsal, and transverse process of first four or five dorsal vertebræ.

Insertion.—Occipital tuberosity.

Action.—Extensor of head.

Nerve.—Deep cervical.

SMALL COMPLEXUS.

Origin.—Same as anterior portion of former.

Insertion.—Mastoid process of temporal.

Action.—Extends head and inclines it to one side.

Nerve.—Deep cervical.

TRANSVERSE SPINOUS OF NECK.

Origin.—To five last articular tubercles of cervical spine.

Insertion.—Second, third, fourth, fifth and sixth cervical spinous processes.

Action.—Extensor and flexor of cervical region.

Nerve.—Deep cervical.

INTER-TRANSVERSE OF NECK.

Origin.—Six short muscles between transverse processes of cervical spine, except between first and second.

Action.—Incline neck to same side.

Nerve.—Superficial cervical.

GREAT OBLIQUE OF HEAD.

Origin.—Spinous process of axis.

Insertion.—Transverse process of atlas.

Action.—Rotates atlas on odontoid process.

Nerve.—Second cervical.

SMALL OBLIQUE.

Origin.—Transverse process of atlas.

Insertion.—Styloid process, external surface of occipital and mastoid crest.

Action.—Inclines head on atlas.

Nerve.—First cervical.

POSTERIOR GREAT STRAIGHT OF HEAD.

Origin.—Spinous process of axis.

Insertion.—To occipital behind complexus.

Action.—Extends head.

Nerve.—Deep cervical.

POSTERIOR SMALL STRAIGHT OF HEAD.

Origin.—From superior face of atlas.

Insertion.—Below preceding, on occipital.

Action.—Same as preceding.

Nerve.—Deep cervical.

INFERIOR CERVICAL REGION.—SUBCUTANEOUS OF NECK.

Origin.—Anterior prolongation of sternum and muscles of chest.

Insertion.—Skin of neck—raphé—muscles of face, and zygomatic crest.

Action.—Braces muscles and pulls mouth backward.

Nerve.—Facial.

MASTOIDO-HUMERALIS.

Origin; Anterior Portion.—Mastoid process and crest.

Insertion.—Furrow of torsion of humerus below deltoid imprint.

Origin; Posterior Portion.—Transverse processes of first four cervical vertebræ.

Insertion.—With first portion.

Action.—Carries limb forward or inclines head to side.

Nerve.—Spinal accessory.

STERNO-MAXILLARIS.

Origin.—Cariniform process of sternum.

Insertion.—Posterior border of inferior maxilla.

Action.—Flexes head or turns it to one side.

Nerve.—Spinal accessory.

STERNO-HYOID.

Origin.—Cariniform cartilage of sternum.

Insertion.—Inferior surface of body of hyoid.

Action.—Depresses hyoid and larynx.

Nerve.—First cervical.

STERNO-THYROID.

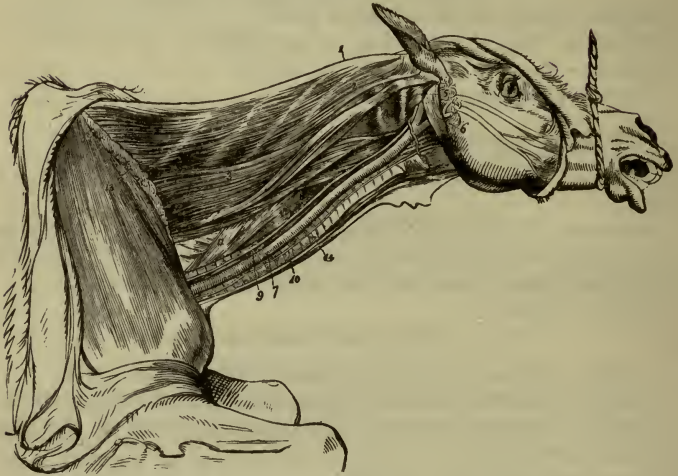Origin.—As preceding.

Insertion.—Posterior border of thyroid cartilage.

Action.—As preceding.

Nerve.—First cervical.

FIG. 6.



LATERAL VIEW OF THE NECK; MIDDLE LAYER OF MUSCLES.

- 1, Funicular portion of the cervical ligament; 2, Complexus major; 3, Complexus minor; 4, Rectus capitis posticus major; 5, Rectus capitis posticus minor; 6, Stylo-maxillaris; 7, Carotid artery; 8, Pneumogastric nerve and branch of sympathetic; 9, Longus colli; 10, Recurrent nerve; 11, Inferior scalenus; 12, Spinalis, or transversalis colli; 13, Incision through rhomboideus and trapezius; 14, Trachea.

OMO-HYOID.

Origin.—Inner surface of sub-scapularis.

Insertion.—Body of hyoid bone with sterno-hyoid (separates carotid artery from jugular vein in upper half of neck).

Action.—Depresses hyoid.

Nerve.—First cervical.

RECTUS CAPITIS ANTICUS MAJOR.

Origin.—Transverse process of third, fourth and fifth cervical vertebræ.

Insertion.—Body and basilar process of sphenoid.

Action.—Flexes head or carries it to one side.

Nerve.—First cervical.

RECTUS CAPITIS ANTICUS MINOR.

Origin.—Inferior surface of atlas.

Insertion, action, nerve.—Same as preceding.

RECTUS CAPITIS LATERALIS.

Origin.—From atlas outside preceding.

Insertion.—Styloid process of occipital.

Action.—Depresses head laterally.

Nerve.—First cervical.

SCALENUS SUPERIOR.

Origin.—Transverse processes of last three or four cervical vertebræ.

Insertion.—Superior extremity of first rib.

Action.—Flexes neck, inclines it to one side, or raises rib.

Nerve.—Third and fourth cervical.

SCALENUS INFERIOR.

Origin.—Transverse process of last four cervical vertebræ.

Insertion.—Anterior border and external face of first rib.

Action.—As preceding.

Nerve.—Third and fourth cervical.

LONGUS COLLI.

Origin; Posterior Portion.—Inferior face of bodies of first six dorsal vertebræ.

Insertion.—Inferior tubercle of sixth cervical vertebræ.

Origin; Middle Portion.—Transverse process of last six cervical vertebræ.

Insertion.—Inferior ridge of bodies of first six cervical vertebræ.

Origin; Anterior Portion.—Anterior three or four fasciculi of middle portion.

Insertion.—Inferior tubercle of atlas.

Action.—Whole muscle flexes neck.

Nerve.—Third and fourth cervical.

REGION OF BACK.

TRAPEZIUS.

Origin.—Cervical cord and transverse processes of first dorsal vertebræ.

Insertion.—Olecranian spine and scapular aponeurosis.

Action.—Raises shoulder and carries it forward or backward.

Nerve.—Spinal accessory.

LATISSIMUS DORSI.

Origin.—Spinous processes of all lumbar and last fourteen or fifteen dorsal vertebræ.

Insertion.—Internal tuberosity of body of humerus.

Action.—Carries arm backward and upward, also in forced inspiration.

Nerve.—Eighth cervical.

SERRATUS ANTICUS MINOR.

Origin.—Dorsal spinous processes from second to thirteenth.

Insertion.—External surface of ribs from fifth to fourteenth.

Action.—Raises ribs in inspiration.

Nerve.—Intercostals.

SERRATUS POSTICUS MINOR.

Origin.—Spinous processes of dorsal vertebræ from tenth to eighteenth, and few lumbar vertebræ.

Insertion.—External face of last nine ribs.

Action.—Draws ribs upward and backward in *expiration*.

Nerve.—Intercostals.

ILIO-SPINALIS (LONGISSIMUS DORSI OF PERCIVAL).

Origin.—Lumbar border, external angle and internal surface of ilium, and spinous processes of all lumbar, dorsal and last four cervical vertebræ.

Insertion.—Transverse processes of lumbar vertebræ and outer surfaces of fifteen or sixteen last ribs.

Action.—Extends vertebral column and pulls ribs forward in expiration.

Nerve.—Superior dorsal.

COMMON INTERCOSTAL.

Origin.—Runs from external surface of one rib to the next; the anterior fasciculus; into the last cervical vertebra.

Action.—Depresses ribs.

Nerve.—Intercostal.

TRANSVERSE SPINOUS OF BACK AND LOINS.

Origin.—Lateral lip of sacrum, articular tubercles of lumbar and transverse processes of dorsal vertebræ.

Insertion.—Spinous process of sacral, lumbar, dorsal and last cervical vertebræ.

Action.—Extensor of spine.

Nerve.—Superior dorsal.

COSTAL REGION.

Here are found 54 muscles:—

(1) 17 external intercostals; (2) 17 internal intercostals; (3) 17 supercostals; (4) serratus magnus; (5) costo-transversalis, and (6) triangularis sterni.

EXTERNAL INTERCOSTALS.

Origin.—Downward and backward from posterior border of rib in front.

Insertion.—Anterior border of rib behind.

Action.—Muscles of inspiration.

Nerve.—Intercostal.

INTERNAL INTERCOSTALS.

Origin.—Downward and forward, crossing preceding from inner and anterior border of rib behind.

Insertion.—Posterior border of rib in front.

Action.—Muscles of expiration.

Nerve.—Intercostals.

SUPERCOSTALS.

Origin.—From transverse processes of dorsal vertebræ.

Insertion.—External surface of one or two ribs below.

Action.—Draws ribs forward in inspiration.

Nerve.—Superior dorsal.

SERRATUS MAGNUS.

Origin.—External surface of first eight ribs.

Insertion.—Anterior and posterior triangular surfaces of scapula and subscapularis.

Action.—Acts to support body as a girdle or depresses scapula.

Nerve.—Superior thoracic.

TRANSVERSE COSTAL.

Origin.—External face of first rib.

Insertion.—Fourth costal cartilage and sternum.

Action.—Raises ribs and enlarges thorax.

Nerve.—Intercostal.

TRIANGULARIS STERNI.

Origin.—From superior border of sternum.

Insertion.—Cartilages of true ribs except first.

Action.—Expiratory muscle by depressing cartilages.

Nerve.—Intercostal.

DIAPHRAGM.

The muscular partition between the thoracic and abdominal cavities.

Origin.—By right and left pillars from lumbar vertebræ, con-founded with inferior common ligament of the spine. (Between two pillars pass posterior aorta and thoracic duct.) From xiphoid appendix of sternum and anterior extremities of last twelve ribs.

Insertion.—Phrenic centre, dividing into right and left leaflets.

RELATIONS.—*Anteriorly*, with pleuræ and lungs; *posteriorly*, peritoneum, stomach, liver, colon and spleen.

Openings.—Behind for *aorta and thoracic duct*; in right leaflet for *vena cava*; in right pillar for *œsophagus*.

Nerves.—Phrenic.

Action.—Muscle of respiration.

ABDOMINAL REGION.

EXTERNAL OBLIQUE.

Origin.—External surface of thirteen or fourteen lower ribs and aponeurosis of latissimus dorsi.

Insertion.—Into *linea alba* and pre-pubic tendon. A number of strong fibres are reflected from the pubes to the anterior superior spine of the ilium, forming *Poupart's ligament*.

Action.—Compresses abdominal viscera, flexes spine and acts as muscle of forced expiration.

Nerve.—Intercostal and lumbar.

INTERNAL OBLIQUE.

Origin.—Aponeurosis of latissimus dorsi; external angle of ilium; outer fourth of Poupart's ligament, and external face of last few ribs.

Insertion.—Linea alba; the fibres separating inferiorly to form part of the inguinal canal.

Action.—Same as preceding.

Nerve.—Intercostal and lumbar.

RETRACTOR OF LAST RIB.

Origin.—From transverse processes of first two or three lumbar vertebræ.

Insertion.—Posterior border of last rib.

Action.—Fixes last rib.

Nerve.—Lumbar.

TRANSVERSALIS.

Origin.—Internal surface of asternal ribs, and transverse processes of lumbar vertebræ.

Insertion.—Into *linea alba* (or middle aponeurosis of abdominal tunic) and crural arch.

Action.—Same as oblique muscles.

Nerve.—Intercostal and lumbar.

RECTUS ABDOMINIS.

Origin.—To cartilages of fifth, sixth, seventh, eighth, and ninth ribs, and inferior face of sternum.

Insertion.—To common tendon into pubes.

Action.—Draws pelvis forward, thorax backward; flexes spine and compresses abdomen.

Nerve.—Intercostal.

INGUINAL CANAL.

A canal on each side and in front of the pubic bone, running downward, backward and inward, which transmits the spermatic cord and vessels in the male, and the external mammary vessels in the female.

Has an external or scrotal, and internal or peritoneal ring, and two pillars.

ANTERIOR EXTREMITY.

SUPERFICIAL PECTORAL.

Composed of two parts.

(A) Sterno-humeralis.

Origin.—Anterior appendage and inferior border of sternum.

Insertion.—Anterior ridge of humerus.

Action.—Abductor of anterior limb.

Nerve.—Inferior thoracic.

(B) Sterno-aponeuroticus.

Origin.—Inferior surface of sternum.

Insertion.—With preceding; and also into fascia of limb.

Action.—Same as preceding, and tensor of brachial fascia.

Nerve.—Inferior thoracic.

DEEP PECTORAL.

Composed of two parts.

(A) Sterno-trochineus.

Origin.—Abdominal tunic and posterior two-thirds of inferior border of sternum.

Insertion.—Internal tubercle of head of humerus, fascia of coraco-brachialis and coraco-radialis, and lip of bicipital groove.

Action.—Pulls limb backward.

Nerve.—Inferior thoracic.

(B) Sterno-prescapularis.

Origin.—Sides of inferior border of sternum, and cartilages of first three or four ribs.

Insertion.—Supra-spinatus fascia.

Action.—Pulls scapula backward and downward.

Nerve.—Sixth and seventh cervical.

ANTEA SPINATUS.

Origin.—Antea-spinous fossa.

Insertion.—By two tendons into external and internal humeral tubercles.

Action.—Extensor of humerus.

Nerve.—Sixth and seventh cervical.

POSTEA SPINATUS.

Origin.—Postea-spinous fossa, acromion spine and tuberosity.

Insertion.—External humeral tuberosity.

Action.—Abductor and external rotator.

Nerve.—Sixth and seventh cervical.

TERES MAJOR.

Origin.—One head from dorsal angle and the other from aponeurosis and tuberosity of spine of scapula.

Insertion.—Deltoid imprint of humerus.

Action.—Abductor and external rotator.

Nerve.—Eighth cervical.

TERES MINOR.

Origin.—Posterior border and postea-spinous fossa of scapula and margin of glenoid cavity.

Insertion.—Humerus between external and deltoid tuberosities.

Action.—Like preceding.

Nerve.—Circumflex.

SUBSCAPULARIS.

Origin.—Subscapular fossa.

Insertion.—Internal tubercle of humerus.

Action.—Adductor and internal rotator.

Nerve.—Seventh cervical.

ADDUCTOR OF THE ARM.

Origin.—Dorsal angle of humerus and subscapularis.

Insertion.—Circular imprint of humerus.

Action.—As name implies, also internal rotator.

Nerve.—Eighth cervical.

CORACO-BRACHIALIS.

Origin.—Coracoid process.

Insertion.—Above internal tuberosity and anterior face of humerus.

Action.—Adductor internal rotator.

Nerve.—Musculo-cutaneous.

SMALL SCAPULO-HUMERALIS.

Origin.—Above glenoid cavity.

Insertion.—Into capsular ligament.

Action.—Raises capsular ligament during flexion.

Nerve.—Subscapular.

BRACHIAL REGION.

CORACO-RADIALIS.

Origin.—Coracoid process through bicipital groove.

Insertion.—Bicipital tuberosity on superior and inner border of radius, capsular and internal lateral ligament.

Action.—Flexes forearm.

Nerve.—Musculo-cutaneous.

HUMERO-RADIALIS.

Origin.—Posterior face of humerus below head.

Insertion.—Passes through groove on radius under internal lateral ligament into upper end of radius and ulna. (Winds through twisted furrow of humerus.)

Action.—Flexes forearm.

Nerve.—Radial.

LONG EXTENSOR OF FOREARM.

Origin.—Aponeurosis from posterior border of scapula.

Insertion.—Posterior border of ulna and anti-brachial aponeurosis.

Action.—Extends forearm.

Nerve.—Radial.

LARGE EXTENSOR OF FOREARM.

Origin.—Dorsal angle and axillary border of scapula.

Insertion.—Into olecranon, after gliding over a bursa.

Action.—As preceding.

Nerve.—Radial.

SHORT EXTENSOR OF FOREARM.

Origin.—Line running from head of humerus to deltoid.

Insertion.—Imprint with preceding.

Action.—With preceding.

Nerve.—Radial.

MIDDLE EXTENSOR OF FOREARM.

Origin.—Inner surface of humerus above tuberosity.

Insertion.—Tip and side of olecranon.

Action.—As preceding.

Nerve.—Radial.

ANCONEUS.

Origin.—Above margin of olecranian fossa.

Insertion.—Anterior and external border of olecranon.

Action.—Raises capsule of humero-ulnar-radial articulation.

Nerve.—Radial.

FOREARM.

The anti-brachial aponeurosis is a strong layer of fibrous tissue that binds the muscles of the forearm together and passes between them, forming the inter-muscular septum. It is attached to the olecranon and sides of radius.

ANTERIOR EXTENSOR OF THE METACARPUS.

Origin.—From humerus below crest of furrow of torsion, and above and in front of the inferior articular portion.

Insertion.—Anterior and superior tuberosity of large metacarpal bone.

Action.—As name implies.

Nerve.—Radial.

FIG. 7.

OBLIQUE EXTENSOR OF METACARPUS.

Origin.—External surface of radius.

Insertion.—Head of internal metacarpal with internal lateral ligament.

Action.—Extends metacarpus and rotates them outward.

Nerve.—Radial.

ANTERIOR EXTENSOR OF PHALANGES.

Origin.—Below crest of furrow of torsion, of humerus, and in front of its inferior extremity; the external lateral ligament of elbow and external tuberosity and border of radius.

Insertion.—Pyramidal eminence of third phalanx, capsular ligament of fetlock-joint and anterior surfaces of first and second phalanges.

Action.—As name implies.

Nerve.—Radial.

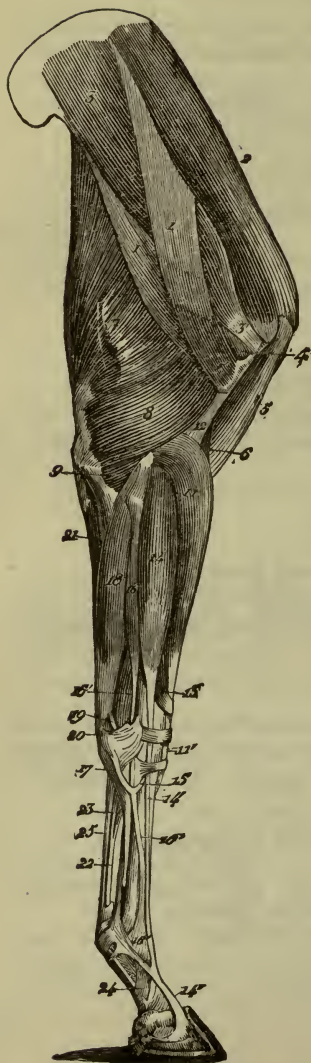


FIG. 7.—EXTERNAL MUSCLES OF THE RIGHT ANTERIOR LIMB.

- 1, 1, Long abductor of the arm; 1', Its humeral insertion; 2, Superspinatus; 3, Subspinatus; 3', Its tendon of insertion; 4, Short abductor of the arm; 5, Biceps; 6, Anterior brachialis; 7, Large extensor of the forearm; 8, Short extensor of the forearm; 9, Anconeus; 11, Anterior extensor of the metacarpus; 11', Its tendon; 12, Aponeurosis separating that muscle from the anterior brachialis; 13, Oblique extensor of the metacarpus; 14, Anterior extensor of the phalanges; 14', Its principal tendon; 15, The small tendinous branch it furnishes to the lateral extensor; 16, Lateral extensor of the phalanges; 16', Its tendon; 17, The fibrous band it receives from the carpus; 18, External flexor of the metacarpus; 19, Its metacarpal tendon; 20, Its supracarpal tendon; 21, Ulnar portion of the perforans; 22, Tendon of the perforans; 23, Its carpal ligament; 24, Its reinforcing phalangeal sheath; 25, Tendon of the perforatus.

LATERAL EXTENSOR OF PHALANGES.

Origin.—Outer side of superior tuberosity of radius; from continuous sides of radius and ulna and external lateral ligament.

Insertion.—Anterior surface of superior portion of first phalanx.

Action.—As preceding.

Nerve.—Radial.

EXTERNAL FLEXOR OF METACARPUS.

Origin.—External condyle of humerus.

Insertion.—Supercarpal and external metacarpal bones.

Action.—Flexes foot.

Nerve.—Radial.

OBLIQUE FLEXOR OF METACARPUS.

Origin.—Base of epitrochlea and olecranon.

Insertion.—On supercarpal with preceding.

Action.—As preceding.

Nerve.—Ulnar.

INTERNAL FLEXOR OF METACARPUS.

Origin.—Epitrochlea with preceding.

Insertion.—Head of internal metacarpal bone.

Action.—Same as external flexor.

Nerve.—Radial.

FLEXOR SUBLIMIS DIGITORUM OR PERFORATUS.

Origin.—Summit of epitrochlea.

Insertion.—By two divisions into superior extremity of second phalanx; between the two divisions passes the perforans tendon. It also passes through the *carpal sheath*, a reflexion of strong fibres running from the first to the fourth carpal bones.

Action.—Flexes second phalanx and also whole foot.

Nerve.—Ulnar.

FLEXOR PROFUNDUS DIGITORUM OR PERFORANS.

Origin.—Summit of epitrochlea, summit and posterior border of olecranon and posterior surface of radius.

Insertion.—Passes through carpal sheath, between two heads

of perforatus, and is attached by means of plantar aponeurosis into semi-lunar crest of os pedis.

Action.—Flexes third phalanx and also whole foot.

Nerve.—Ulnar.

ANTERIOR FOOT.

They comprise two lumbricales and two interossei.

LUMBRICALI.

Origin.—From right and left side of perforans tendon.

Insertion.—Into fibrous tissue of the fetlock.

INTEROSSEI.

Origin.—Anteriorly between metacarpal bones.

Insertion.—Into anterior extensor of phalanges.

Action.—With extensor.

Nerve.—Ulnar.

POSTERIOR EXTREMITY.

PELVIC REGION.—GREAT PSOAS.

Origin.—From bodies of last two dorsal and first five lumbar vertebræ, inferior surface of last two ribs and lumbar transverse processes.

Insertion.—Internal trochanter.

Action.—Flexor and external rotator of thigh.

Nerve.—Iliaco-muscular.

ILIO-PSOAS.

Origin.—Whole iliac surface, external iliac angle, sacro-iliac ligament and ilio-pectineal crest.

Insertion.—With preceding.

Action.—Same.

Nerve.—Iliaco-muscular.

SMALL PSOAS.

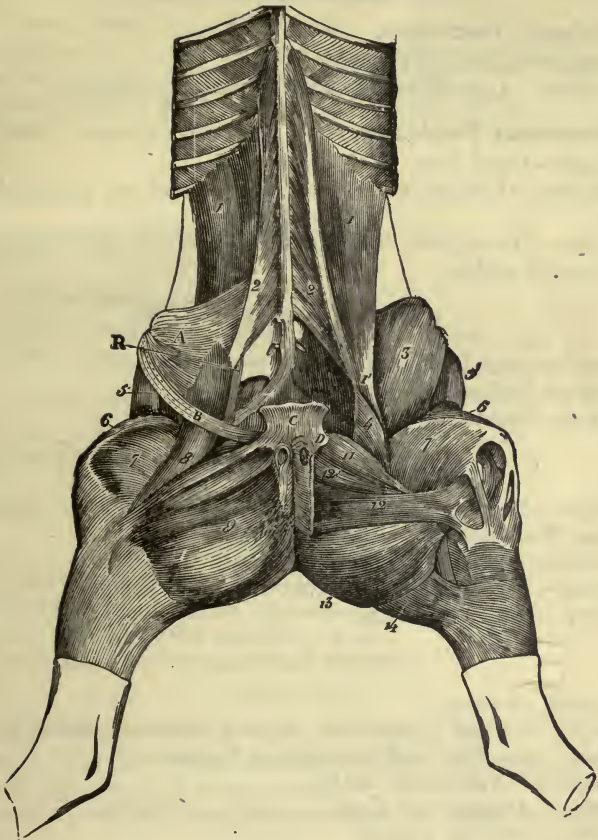
Origin.—Bodies of three or four last dorsal and all lumbar vertebræ.

Insertion.—Ilio-pectineal eminence and ilio-lumbar aponeurosis.

Action.—Flexes pelvis on spine, or spine on pelvis.

Nerve.—Iliaco-muscular.

FIG. 8.



MUSCLES OF THE SUB-LUMBAR, PATELLAR, AND INTERNAL CRURAL REGIONS.

- 1, Psoas magnus; 1', Its terminal tendon; 2, Psoas parvus; 3, Iliacus; 4, Its small internal portion; 5, Muscle of the fascia lata; 6, Rectus of the thigh; 7, Vastus internus; 8, Long adductor of the leg; 9, Short adductor of the leg; 11, Pectineus; 12, Great adductor of the thigh; 12', Small adductor of the thigh; 13, Semimembranosus; 14, Semitendinosus.—A, Portion of the iliac fascia; B, Portion of the layer reflected from the aponeurosis of the abdominal great oblique, forming Poupart's ligament; c, Pubic tendon of the abdominal muscles; d, Origin of the pubo-femoral ligament.

QUADRATUS LUMBORUM.

(A) **Primary Fasciculus.**

Origin.—Sacro-iliac ligament.

Insertion.—Last rib and transverse lumbar processes.

(B) **Secondary Fasciculus.**

Origin.—From first.

Insertion.—Lumbar transverse processes and last two or three ribs.

Action.—Draws last rib backward and inclines spine laterally.

Nerve.—Lumbar.

INTER-TRANSVERSE OF LOINS.

Runs between lumbar transverse processes.

Action.—Inclines lumbar region laterally.

Nerve.—Lumbar.

GLUTEAL REGION.—SUPERFICIAL GLUTEAL.

Origin.—Internal aspect of gluteal aponeurosis, postero-external iliac angle and ischiatic ligament.

Insertion.—Third trochanter of femur.

Action.—Abductor and external rotator of femur.

Nerve.—Anterior gluteal.

MIDDLE GLUTEAL.

(Largest of three.)

Origin.—Gluteal aponeurosis, superior face and external angles of ilium, sacro-iliac and sacro-sciatic ligaments.

Insertion.—Trochanter major.

Action.—Abductor of thigh, or assists in rearing.

Nerve.—Anterior gluteal.

DEEP GLUTEAL.

Origin.—Neck of ilium and supra-cotyloid ridge.

Insertion.—Convexity of trochanter.

Action.—Abductor and internal rotator.

Nerve.—Posterior gluteal.

THIGH.—TENSOR VAGINÆ FEMORIS.

Origin.—External angle of ilium.

Insertion.—Into the strong fascia covering and running between the muscles of the thigh, the *fascia lata*.

Action.—Flexes thigh and renders fascia lata tense.

Nerve.—Anterior gluteal.

CRURAL TRICEPS.

(A) **Rectus.**

Origin.—Lip of cotyloid cavity.

Insertion.—Into patella.

(B) **Vastus Externus.**

Origin.—Outer and anterior surfaces of femur.

Insertion.—As above.

(C) **Vastus Internus.**

Origin.—Inner and anterior surfaces of femur.

Insertion.—As above.

Action.—Extensor of leg.

Nerve.—Posterior gluteal.

ANTERIOR GRACILIS.

Origin.—From ilium near origin of rectus.

Insertion.—Into capsular ligament of hip joint.

Action.—Makes tense capsule of joint.

Nerve.—Ilio-muscular.

LONG VASTUS.

(A) **Anterior portion.**

Origin.—Sacral spine, sacro-sciatic ligament, tuberosity of ischium and coccygeal aponeurosis.

Insertion.—Below subtrochanteric crest of femur and side of patella.

Action.—Pulls femur backward and patella outward.

(B) **Posterior portion.**

Origin.—Spine and tuberosity of ischium.

Insertion.—Crest of tibia and tibial fascia.

Action.—Flexes leg and makes tense fascia.

Nerve.—Great sciatic.

SEMI-TENDINOSUS.

Origin.—From sacral spine, sacro-sciatic ligament (with long vastus and tuber ischii).

Insertion.—Anterior crest of tibia.

Action.—Same as preceding.

Nerve.—Great sciatic.

SEMI-MEMBRANOSUS.

Origin.—Tuberosity and inferior face of body of ischium and coccygeal aponeurosis.

Insertion.—Eminence above internal condyle of femur.

Action.—Adductor and extensor of thigh and an adjunct in rearing.

Nerve.—Great sciatic.

INTERNAL FEMORAL REGION.—SARTORIUS.

Origin.—Iliac aponeurosis near tendon of psoas parvus.

Insertion.—Internal patellar ligament.

Action.—Adducts leg and flexes femur.

Nerve.—Obturator.

GRACILIS.

Origin.—Ischio-pubic symphysis.

Insertion.—With preceding and internal tuberosity of tibia.

Action.—Adductor of leg and tensor of tibial aponeurosis.

Nerve.—Obturator.

PECTINEUS.

Origin.—Inferior face of pubes of pubo-femoral ligament.

Insertion.—Inner surface of femur near nutrient foramen.

Action.—Adductor, flexor and internal rotator of femur.

Nerve.—Obturator.

ADDUCTOR BREVIS.

Origin.—Inferior face of pubis.

Insertion.—Quadrilateral line on posterior surface of femur.

Action.—As name implies.

Nerve.—Obturator.

ADDUCTOR LONGUS.

Origin.—Lower face of ischium and symphysis.

Insertion.—With preceding, and internal condyle of femur.

Action.—Adductor, extensor and external rotator of thigh.
Nerve.—Obturator.

QUADRATUS FEMORIS.

Origin.—Tuber ischii.
Insertion.—Posterior surface of femur, below trochanter.
Action.—Extensor and adductor of femur.
Nerve.—Great sciatic.

EXTERNAL OBTURATOR.

Origin.—Below margin of obturator foramen.
Insertion.—Trochanterian fossa.
Action.—Adductor and external rotator.
Nerve.—Obturator.

INTERNAL OBTURATOR.

Origin.—Above margin of obturator foramen.
Insertion.—Trochanterian fossa.
Action.—Abductor and external rotator.
Nerve.—Great sciatic.

GEMELLI.

Origin.—Above and below tendon of obturator internus, from ischium.
Insertion.—Into tendon of internal obturator.
Action.—Like preceding.
Nerve.—Great sciatic.

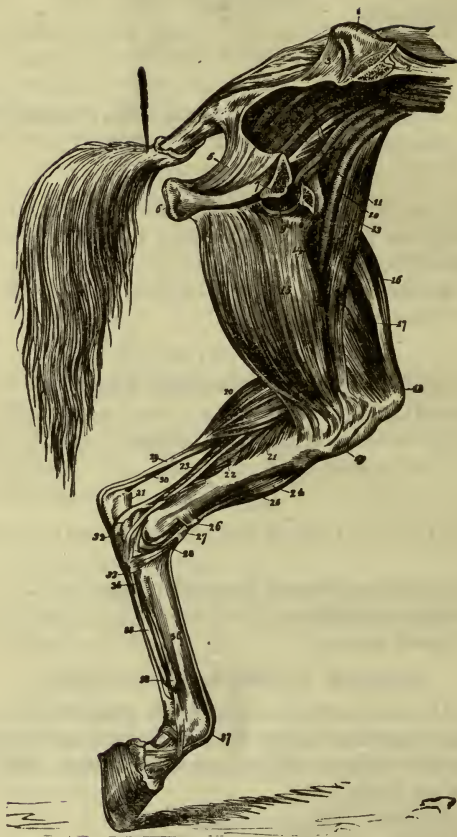ANTERIOR EXTENSOR OF PHALANGES.

Origin.—Digital fossa above external condyle of femur.
Insertion.—Capsular ligament of metatarso-phalangeal articulation, anterior surfaces of first two phalanges, and pyramidal eminence of os pedis.
Action.—Extends digit.
Nerve.—External popliteal.

LATERAL EXTENSOR OF PHALANGES.

Origin.—External femoro-tibial ligament and whole extent of fibula.
Insertion.—Terminates in tendon of anterior extensor.
Action.—As preceding.
Nerve.—External popliteal.

FIG. 9.



MUSCLES ON INNER ASPECT OF LEFT POSTERIOR LIMB.

- 1, Crest of the ilium; 2, Section through it; 3, Sacro-ischiatic ligament; 4, Pyriformis; 5, Posterior portion of sacro-ischiatic ligament; 6, Tuberosity of ischium; 7, Anterior portion of ischium, sawn through; 8, Pubis; 9, Obturator foramen; 10, External iliac artery and vein, 11; 12, Obturator artery and vein; the figures are placed on the internal obturator muscle; 13, Long adductor of the leg, or sartorius; 14, Small adductor of the thigh, or adductor brevis; 15, Short adductor of the leg, or gracilis; 16, Rectus of the thigh; 17, Vastus internus; 18, Patella, with insertion of rectus; 19, Upper extremity of tibia; 20, Gastrocnemius; 21, Popliteus; 22, Oblique flexor of the phalanges, or flexor pedis accessorius, with its

tendon,³⁴; 23, Perforans muscle, with its tendon, 35; 24, Flexor metatarsi; 25, Anterior extensor of the phalanges, or extensor pedis; 26, Annular ligament; 27, Tendon of flexor metatarsi, and its cunean branch, 28; 29, Tendon of superficial flexor, or internal gastrocnemius; 30, Tendon of gemelli or external gastrocnemius; 31, Os calcis; 32, Astragalus; 33, Perforatus tendon; 34, Tendon of oblique flexor joining the perforans tendon, 35; 36, Large metatarsal bone; 37, Extensor pedis tendon; 38, Terminal knob of small metatarsal bone.

FLEXOR OF METATARSUS.

(A) Tendinous Portion.

Origin.—From front of femur between trochlea and external condyle.

Insertion.—Front of superior extremity of principal metatarsal and cuboid.

Action.—Flexes metatarsus and hock joint.

(B) Muscular Portion.

Origin.—From tibia on sides of groove for tendinous portion.

Insertion.—In front of superior extremity of principal metatarsal and second cuneiform bone.

Nerve.—Anterior tibial.

GASTROCNEMII.

Origin.—External head from above and behind external condyle. Internal from internal condyle.

Insertion.—Into posterior part of summit of os calcis after passing over a bursa.

Action.—Extends foot on tibia.

Nerve.—Great sciatic.

SOLEUS.

Origin.—External tuberosity of tibia.

Insertion.—Into tendon of preceding.

Action.—As preceding.

Nerve.—Great sciatic.

FLEXOR SUBLIMIS DIGITORUM OR PERFORATUS.

Origin.—Above super-condyloid fossa of femur.

Insertion.—Into summit of os calcis and fibrous band of hock, then spreads out on second phalanx.

Action.—Flexes second phalanx and extends foot.

Nerve.—Plantar.

POPLITEUS.

Origin.—Outside external condyle of femur.

Insertion.—Into triangular surface on posterior surface of tibia at its upper portion.

Action.—Flexes tibia and rotates it outward.

Nerve.—Great sciatic.

FLEXOR PROFUNDUS DIGITORUM OR PERFORANS.

Origin.—To external tuberosity and posterior surface of tibia fibula and interosseous ligament.

Insertion.—Passes through tarsal sheath on inner side of os calcis and into semilunar crest of os pedis.

Action.—Flexes phalanges on each other and on metatarsus.

Nerve.—Great sciatic.

OBLIQUE FLEXOR OF PHALANGES.

Origin.—External tuberosity of tibia.

Insertion.—Upper third of metatarsus.

Action.—With preceding.

Nerve.—Great sciatic.

POSTERIOR FOOT.

Two lumbricales and *two interossei*, as in anterior foot.

PEDAL MUSCLE.

Origin.—Lower end of os calcis and astragalus.

Insertion.—Into tendons of extensors of phalanges.

Action.—Aids in extending digit and flexing hock.

Nerve.—Plantar.

COCCYGEAL REGION.—(3 PAIRS.) SACRO-COCCYGEUS SUPERIOR.

Origin.—From side of spinous processes of last 3 or 4 sacral vertebræ.

Insertion.—Into coccygeal vertebræ.

Action.—Elevates tail or carries it to one side.

Nerve.—Coccygeal.

SACRO-COCCYGEUS INFERIOR.

Origin.—From third portion of sacrum, internal surface of sacro-sciatic ligament.

Insertion.—Under surface of coccygeal vertebræ.

Action.—Depresses tail or carries it to one side.

Nerve.—Coccygeal.

SACRO-COCCYGEUS LATERALIS.

Origin.—Spinous processes of last lumbar vertebræ.

Insertion.—Sides of coccygeal vertebræ.

Action.—Carries tail to one side.

Nerve.—Coccygeal.

ISCHIO-COCCYGEUS.

Origin.—Internal face of sacro-sciatic ligament and sciatic crest.

Insertion.—Last sacral and first two coccygeal vertebræ.

Action.—Depresses whole tail.

Nerve.—Coccygeal.

CIRCULATORY APPARATUS.

PERICARDIUM.

A fibro-serous membrane enveloping the heart and favoring its movement by its polished surfaces. *Fibrous layer* attached by its *apex* to the *sternum*, from the fourth rib to the xiphoid appendix.

By its base to the great vessels of the neck and continuous with the fascia of the neck.

Serous layer composed of a layer of flattened epithelium on a basement membrane. It is composed of two divisions, a visceral and parietal. The parietal layer is reflected on the fibrous sac, and the visceral over the heart itself. Amount of fluid in sac, very small.

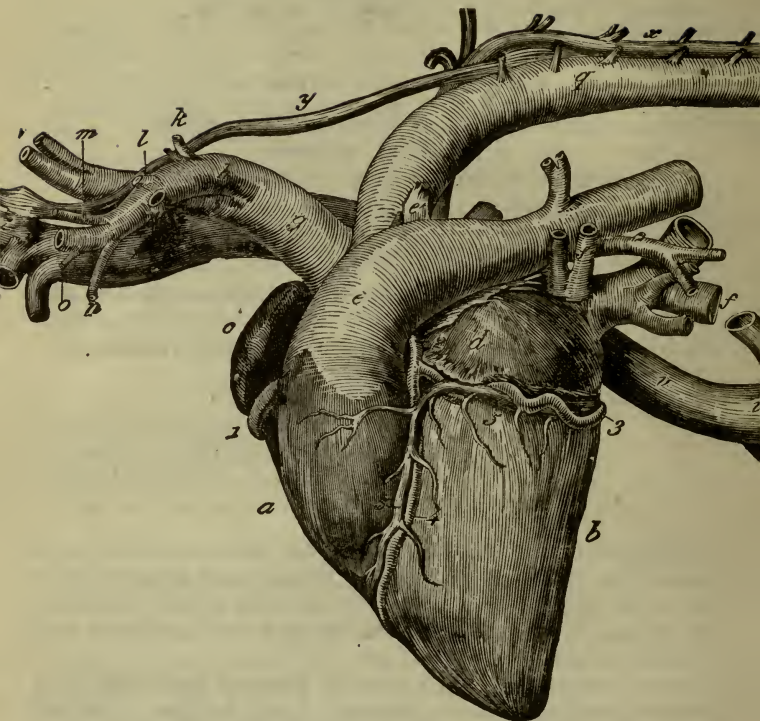
Blood supply from mediastinal arteries.

Nerves from sympathetic.

HEART.

The heart is the propelling organ of the blood. It is a hollow muscle placed in the thorax opposite the third, fourth, fifth and sixth ribs, between and below the lungs. It is conoidal in shape, 10 inches long and $7\frac{1}{2}$ inches wide. Weight, $6\frac{3}{4}$ lbs.

FIG. 10.



THE HEART AND PRINCIPAL VESSELS; LEFT FACE.

a, Right ventricle; *b*, Left ventricle; *c*, Right auricle; *d*, Left auricle; *e*, Pulmonary artery; *f*, Obliterated arterial canal; *g*, Anterior aorta; *h*, Left axillary artery; *i*, Right axillary artery, or brachio-cephalic trunk; *j*, Origin of the dorsal artery; *k*, Origin of the superior cervical artery; *l*, Origin of the vertebral artery; *m*, Origin of the inferior cervical artery; *n*, Origin of the internal thoracic artery; *o*, Origin of the external ditto; *p*, Carotid arteries; *q*, Posterior aorta; *r*, Anterior vena cava; *s*, Trunk of the axillary vein; *t*, Trunk of the internal thoracic vein; *u*, Trunk of the dorso-cervical vein; *v*, Posterior vena cava; *w*, Embouchure of the hepatic and diaphragmatic veins; *x*, Vena azygos; *y*, Thoracic duct; *z*, Embouchure of that vessel, placed near the origin of the anterior vena cava. 1, Right cardiac artery; 2, Left cardiac artery; 3, Auriculo-ventricular branch of the latter; 4, Its ventricular branch; 5, Cardiac vein.

Cavities.—It is divided by a vertical septum into two parts, which are further divided into four by a transverse septum.

The cavities above the transverse septum are called the *right* and *left auricles*.

Those below, the *right* and *left ventricles*.

RIGHT AURICLE.

On an average the walls are one-fourth of an inch thick. It receives the *anterior vena cava*, *posterior vena cava*, *azygos*, and the *large coronary veins*, and opens into the interior of the *auricular appendix*, a mass projecting from the outside of the auricle. Its interior is divided by a number of transverse bands called *musculi pectinati*.

On the posterior wall is the *fossa ovalis*, the remains of the opening existing in foetal life; around its periphery is found the *annulus ovale* or ring.

Behind the anterior cava is an eminence, the *tuberculum Loweri*. The anterior border of the fossa ovalis shows a fold called the Eustachian valve, a remnant of foetal life.

The auriculo-ventricular opening is found on its floor, circular in outline, surrounded by a fibrous ring and closed by the tricuspid valve.

RIGHT VENTRICLE.

The walls are, on an average, $\frac{6}{10}$ of an inch thick. The apex extends to only $1\frac{1}{2}$ inches from the point of the heart. The walls are uneven from the columnæ *carneæ*, or muscular columns, which project into the cavity. They are of three varieties, one attached by one end and the other prolonged by the chordæ tendinæ, to the edges of the valves; the second, by both extremities; the third, adherent through all its length.

The *tricuspid valve* closes the opening into the auricle, and is composed of three segments, all attached to the *chordæ tendinæ*.

The *pulmonary opening* is circular and leads into the pulmonary artery. It is closed in by the *semilunar valves*, three in number, which are attached also to the tendinous cords. In the centre of each valve is often seen an elevation, the *corpus arantii*.

LEFT AURICLE.

Much similar in structure to that of the right side. It opens into the left ventricle, and has on its superior wall the openings

of four to eight pulmonary veins, which have no valves. The obliterated foramen ovale is also seen on the inter-auricular septum.

LEFT VENTRICLE.

The walls are on an average $1\frac{1}{2}$ to $1\frac{5}{8}$ inches in thickness; at the apex they are very thin and form the point of the heart.

The *auriculo-ventricular* opening, similar to that on the right side, is closed by the *mitral valve*, composed of two segments attached to chordæ tendinæ.

The *aortic opening* is similar to the one on the right, and is closed by the semilunar valves.

Structure.

Four fibrous rings around the openings.

At the junction of the aortic and auriculo-ventricular rings is a cartilaginous body.

The muscular tissue is striped and involuntary, but unlike all voluntary tissue, it inosculates and branches freely, has no sarcolemma, and its striæ are not well marked.

The *auricles* have two sets of fibres, one common to both, the other of fasciculi arranged in loops, rings, or as sphincters.

The *ventricles* have also two sets, one intrinsic running from the rings obliquely around the axis of the ventricle, the other common to both, running downward and from left to right, terminating internally in the *columnæ carneæ*.

The *endocardium* is a serous membrane lining the cavities of the heart, having a basement membrane covered with flattened endothelium, polygonal in form, each with a nucleus. Its reduplications form the valves.

Blood supply.

Coronary arteries, from trunk of the aorta, each following the horizontal and vertical furrows. The venous blood is returned to the right auricle by the *coronary vein*.

Nerves.

From pneumogastric and sympathetic. Probably also intracardiac sympathetic ganglia.

ARTERIES.

The arteries are the tubes that carry arterial blood from the heart over the body.

The *pulmonary* artery carries venous blood to the lungs, form-

ing with the corresponding veins the *pulmonary circulation*. The remainder of the arteries constitute the *general* or *systemic circulation*.

Structure of arteries.

They are more or less rigid and elastic, with three coats—(1) an external fibrous or *adventitia*, (2) a *middle* muscular or *media*, (3) an *internal* serous or *intima*, continuous with the endocardium.

The external tunic is nourished by *vasa vasorum*, and the muscular coat receives branches from the sympathetic system, called vasomotor nerves.

The capillaries are small vessels between the arterial and venous systems. They are composed of a basement membrane, covered by a layer of delicate cells, continuous with those of the arteries.

THE AORTA.

It is the beginning of the arterial system, given off from the left ventricle, and guarded by the semilunar valves. Just above the valves it shows three dilatations, the *sinuses of Valsalva*. It passes upward and forward for about two inches, when it divides into the *anterior and posterior aortas*.

Branches.

Right and left coronary to heart (see above).

ANTERIOR AORTA.

The smaller of the two passes forward and upward for two or two and a half inches, where it divides into the two *axillary arteries* or *brachial trunks*.

The right is much the larger, and gives off the carotid arteries.

Course.

They curve forward and outward over the anterior border of the first rib below the scaleni, accompanied by the brachial nerves to the space between the sub-scapularis and the adductor of the arm, where it becomes the *humeral artery*.

Branches.—From thoracic portion.

1. *Dorsal* or *transverse cervical*.

To muscles and integument of the withers, neck and shoulders.

It gives off the sub-costal, which sends branches to the second, third and fourth intercostal spaces.

2. *Superior* or *deep cervical*.

Passes between first two ribs to muscles of neck or back, to spinal cord and first intercostal space.

3. *Vertebral*.

Through foramina of the upper six cervical vertebræ, anastomosing with the occipital, and giving off muscular and spinal branches, called *superior*, *inferior*, *external* and *internal*.

4. *Internal thoracic* or *internal mammary*.

Given off near the first rib; runs above the costal cartilages to the xiphoid appendix.

Branches.

Superior to pericardium and mediastinum; *inferior* to pectoral muscles, *external* or intercostal; *anterior abdominal* passes into rectus muscle and anastomoses with post-abdominal.

Asternal artery to thirteenth intercostal space, anastomosing with artery; gives off *abdominal*, *intercostal* and *diaphragmatic* branches.

5. *External thoracic* or *external mammary*.

Given off in front of preceding, curving around first rib; supplies pectoral and other muscles of chest.

6. *Inferior cervical*.

Given off opposite the two preceding; divides into two branches, *superior* (ascending cervical) to muscles and glands of neck, and *inferior* (acromio-thoracic) to pectoral muscles.

7. *Superior scapular*.

Given off near sub-scapular tendon; passes up and terminates in scapular muscles and shoulder joint.

8. *Sub-scapular*.

Given off at junction of axillary portion with humeral artery; passes up and backward near the dorsal angle of scapula.

Branches.

One to *latissimus dorsi*.

Muscular branches to scapular muscles.

Scapulo-humeral to muscles of shoulder and arm.

HUMERAL ARTERY.

From posterior border of sub-scapularis muscle to above in-

ferior articular surface of the humerus, where it terminates in the anterior and posterior radial arteries.

It is in relation to the median nerve on the outside and the coraco-radialis on the inside.

Its **branches** are—

1. *Prehumeral* or *anterior circumflex of shoulder*.

To shoulder joint and muscles of upper humeral region, anastomosing with posterior circumflex.

2. *External collateral of elbow*.

To muscles in vicinity of elbow joint, where it anastomoses with anterior radial.

3. *Internal collateral* or *ulnar*.

To internal border of arm and forearm, to carpus, anastomosing with posterior radial, and accompanying the ulnar nerve and vein. It sends branches to muscles, to elbow joint and humerus.

4. *Coraco-radial*.

To muscle.

ANTERIOR RADIAL.

The smaller of two branches of humeral extends along front of radius to front of carpus, where it splits up into smaller branches, which supply the articulation, and anastomose with posterior radial and interosseous. It gives off branches also to elbow joint and muscles.

POSTERIOR RADIAL.

The larger of two subdivisions of humeral, passes to side on internal ligament of elbow, along inner side of radius, to its inferior portion, where it divides into the *common interosseous, metacarpal* and *collateral artery of the cannon*.

The branches in its course are to elbow and muscles of forearm.

INTEROSSEOUS OF FOREARM.

Arises near radia-ulnar arch, and passes along groove between ulnar and radius. Gives off branches to the elbow, anti-brachial muscles, and terminates at the carpus by numerous anastomoses.

FIG. 11.

COMMON INTEROSSEOUS OF METACARPUS.

Given off at inner side of, and descends behind, the carpus to the head of internal metacarpal, then passes outward, anastomosing with a descending branch from arch above between ulnar and common arteries, forming the *sub-carpal arch*. That above is the *supra-carpal arch*.

Branches.

Two posterior interosseous, arising at heads of metacarpus, pass downward, ending at the lower ends of metacarpus, anastomosing with the *collateral* of the *cannon*, and giving off branches to the suspensory ligament, skin and tendons.

Two anterior interosseous, arising with preceding, curve around heads of bones, become anterior, pass downward, anastomose with *artery of cannon*, and send branches to tendons and skin.

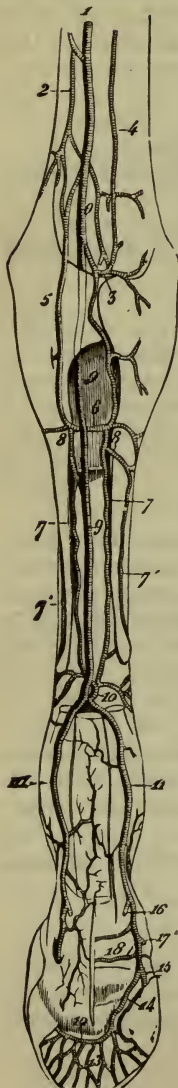
COLLATERAL ARTERY OF CANNON.

Passes under *carpal sheath* to inner side of flexor tendons, with internal plantar nerve, to top of great sesamoid bones, where it divides into the *digital arteries*.

FIG. 11.—ARTERIES OF THE FORE-FOOT, SEEN FROM BEHIND.

The muscles and tendons have been removed, only a small portion of the perforans tendon being left; the os pedis has been chiseled away on its plantar face to expose the semilunar anastomosis:

- 1, Posterior radial artery; 2, Innominate carpal branch; 3, Supra-carpal arch; 4, Epicondyloid (ulnar) artery; 5, Radio-palmar artery, or common trunk of the interosseous metacarpal arteries; 6, Sub-carpal arch; 7, 7, Posterior interosseous meta-carpal arteries; 7', 7', Anterior interosseous metacarpal arteries; 8, 8, Their origin; 9, Collateral artery of the cannon; 10, Its communicating branch with the interosseous arteries; 11, 11, Digital arteries; 12, Semilunar anastomosis in the os pedis; 13, Emergent branches of this anastomosis; 14, Plantar ungueal artery, forming this anastomotic arch; 15, Origin of the preplantar ungueal artery; 16, Origin of the plantar-cushion artery; 17, Origin of the anterior branch of the coronary circle; 18, Posterior branch of the same.



Branches.

An anastomosing branch, with the internal collateral forming the *supra-carpal* arch above the pisiform bone.

A few to the tendons and skin.

One passing upwards, anastomosing with the *interossei*. The digital vessels are similar to those of the posterior limb, with which they will be described.

COMMON CAROTIDS.

These two vessels supplying the head and neck, arise by a common trunk, from the *right axillary* at its origin, called the *cephalic*. This passes forward under the trachea to anterior entrance of the chest, where it divides into its two branches; each common carotid passes upward along the trachea to the larynx, where it divides into the *occipital*, *external* and *internal* carotids.

Branches.

Small ones to the muscles, œsophagus and trachea.

Thyro-laryngeal, to thyroid gland, larynx and pharynx.

Accessory thyroid, to thyroid and cervical muscles.

Occipital.

Passes alongside of internal carotid, under inferior arch of atlas, through anterior foramen in its transverse process, dividing into *occipito-muscular* and *cerebro-spinal*.

Branches.

Prevertebral, to muscles of neck and dura mater.

Mastoid, through parieto-temporal canal to dura and temporal muscles.

Atlido-muscular, passes backward to anastomose with vertebral.

Occipito-muscular, inward to muscles and skin of occipital region.

Cerebro-spinal.

Enters spinal canal and divides into two branches, one of which passes backward and unites with its fellow of the opposite side, forming the *median spinal artery*. The anterior branch unites with its fellow, forming the *basilar*.

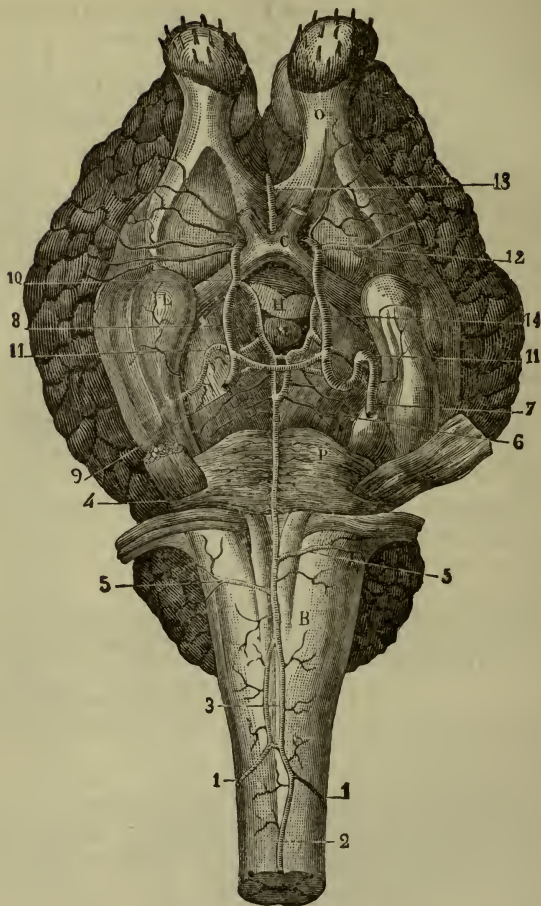
Basilar.

Passes under the medulla, runs forward to the anterior border of the pons.

Branches.

Small vessels to pons, medulla and cranial nerves.

FIG. 12.



ARTERIES OF THE BRAIN.

B, Medulla oblongata; p, Pons Varolii; L, Mastoid lobule; o, Olfactory lobule; c, Chiasma of the optic nerves; m, Mammillary, or pisiform tubercle; h, Pituitary gland; three-fourths have been excised. 1, 1, Cerebro-spinal arteries; 2, Median spinal artery; 3, Lozenge-shaped anastomosis of the two cerebro-spinal arteries, from which result, in front, 4, The basilar trunk (usually the cerebro-spinal arteries arrive in the middle of the lozenge); 5, 5, Posterior cerebellar arteries; 6, An-

terior ditto; 7, Internal carotid artery, with the two curves it makes in the cavernous sinus; 8, Internal carotid on the sides of the pituitary gland; 9, Transverse reticulated anastomosis thrown between the two internal carotids behind the pituitary gland; 10, Bifurcation of the internal carotid; 11, 11, Posterior-cerebral arteries anastomosing behind the pisiform tubercle, receiving in the middle of this anastomosis the two terminal branches of the basilar trunk; 12, Middle cerebral artery; 13, Anterior cerebral artery; 14, Posterior communicating artery.

Posterior cerebellar, to lateral and posterior borders of cerebellum:

Anterior cerebellar, two or three in number. To anterior portion of cerebellum.

Two anastomosing branches with internal carotid. They are not constant, and unite with carotids at second curvature.

Posterior cerebral are given off from the basilar terminal branches, pass outward and enter Bichat's fissure, where they terminate in the choroid plexus or on the surfaces of the cerebrum and cerebellum.

Median spinal artery passes along the inferior fissure of the cord from its beginning to its end. It receives branches from the vertebral, intercostal, lumbar and sacral arteries, and supplies the cord and its membranes.

INTERNAL CAROTID.

Passes up to base of skull through occipito-temporo-sphenoidal opening, enters the cavernous sinus, has two curves develop in its course; in the second, anastomosing with the basilar. They communicate with each other by a transverse branch, pass forward and bifurcate behind the optic tract, into the *posterior communicating* and the common trunk of the *anterior* and *middle cerebrals*.

Posterior communicating passes backward beside the pituitary body and unites with the posterior cerebral.

Middle cerebral passes outward into Sylvian fissure, and supplies the brain structure.

Anterior cerebral passes above optic commissure, unites with its fellow, curves around the corpus callosum, runs backward and supplies the brain structure. It anastomoses with post-cerebral and ophthalmic.

EXTERNAL CAROTID.

Passes forward and upward to great branch of hyoid, then ascends to neck of condyle of lower jaw, where it bifurcates into the *superficial temporal* and *internal maxillary*.

Branches.

A few to the guttural pouch and parotid gland.

1. *Glosso-facial or external maxillary.*

Passes downward, forward and upward, outside of lower jaw in front of masseter, where it divides, above the maxillary spine, into an *ascending* branch to the nasal muscles, and a *descending* branch to the nasal openings.

Branches.

Pharyngeal, to soft palate and pharynx.

Lingual, to tongue.

Sublingual, to sublingual gland, frænum linguæ, and buccal mucous membrane.

Inferior labial or coronary, to structures of lower lip, anastomosing with opposite.

Superior labial, to upper lip and nose.

2. *Maxillo-muscular.*

To pterygoid and masseter muscles.

3. *Posterior auricular.*

To external ear, to parotid and middle ear by stylo-mastoid foramen.

4. *Superficial temporal.*

Passes upward a short distance and divides into the *anterior auricular* and *sub-zygomatic*. The former supplies the external ear, parotid gland and temporal muscle; the latter passes across face, forming the *transverse facial*, and ends in the masseter muscle.

5. *Internal maxillary.*

Passes inward along the outer side of the guttural pouch, enters the sub-sphenoidal foramen, and orbital hiatus, passes through maxillary hiatus to the palatine canal, where it terminates in the *palato-labial*.

In the first or buccal part it gives off its first five branches, in its second or sphenoidal part two, and four from its third or infra-orbital part.

Branches.

1. *Inferior dental*, through inferior dental canal to lower jaw and teeth, giving off mental artery at the foramen.

2. *Pterygoid vessels*, to muscle.

3. *Tympanic*, through Glasserian fissure to tympanic cavity.

4. *Spheno-spinous, or great meningeal*, through anterior lacerated foramen to dura mater.

5. *Posterior temporal*, to muscle.

6. *Deep anterior temporal*, to temporal fossa.

7. *Ophthalmic*, passes into orbit, then out of it by the orbital foramen, and divides in the ethmoidal fossa. It gives off muscular and ciliary arteries to the eye, the *central artery of the retina*, the *supra-orbital* to the forehead, the *lachrymal* to the upper lid and gland, *cerebral* branches to the anterior lobes of the brain, and terminates by the *meningeal* branch to the dura and a *nasal* branch to the ethmoid and median septum.

8. *Buccal*, to superficial and deep facial muscles.

9. *Staphylin*, to soft palate, by posterior palatine groove.

10. *Superior dental*, passes through superior dental canal to infraorbital foramen, where it divides into one small branch to the face, and another to the incisor, canine and anterior molar teeth.

11. *Nasal*, to outer and inner walls of nasal cavity.

Palato-labial, passes along palatine groove to near central incisors, then up through the incisive foramen to the nose and structures of the upper lip and gum.

POSTERIOR AORTA.

Passes upward and backward to the seventh dorsal vertebra, forming its *arch*, thence to the space between the pillars of the diaphragm, where it becomes the abdominal aorta. At the last intervertebral articulation it ends in a double bifurcation, the two internal and two external iliac arteries.

THORACIC AORTA.

From seventh dorsal to pillars of diaphragm.

Branches.

Intercostals, 17, the first from the cervical, the next three from dorsal, and remainder from aorta. Divides into a superior branch to muscles, skin and cord, and an inferior or intercostal behind each rib, which anastomoses below with internal mammary.

Broncho-oesophageal.

By two branches to bronchi and lungs, by two to œsophagus, and small branches to trachea, glands and mediastinum.

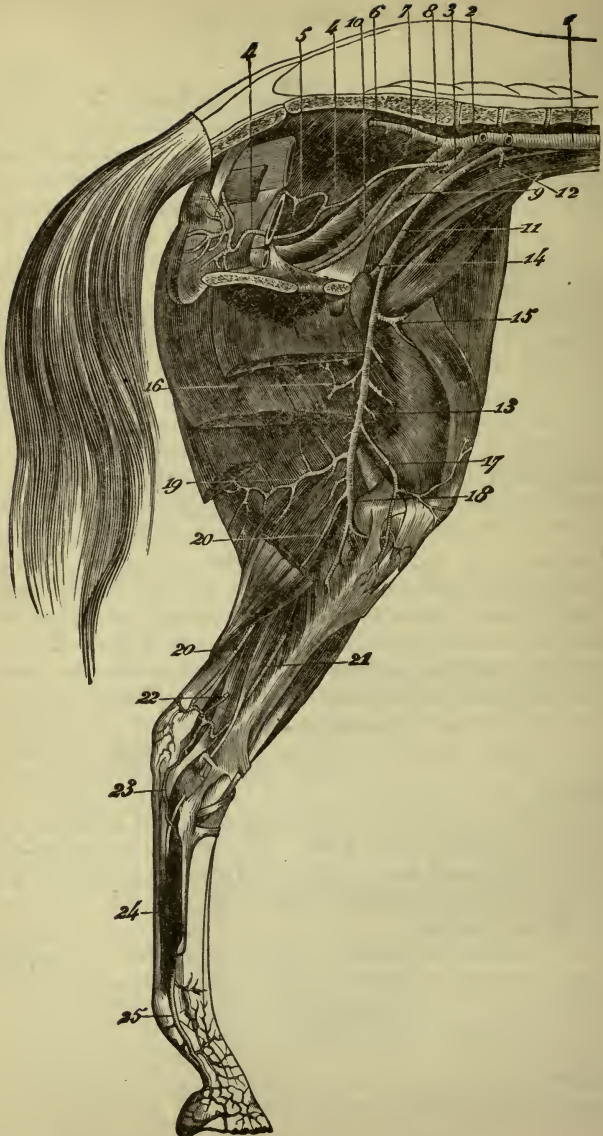
ABDOMINAL AORTA.

From diaphragm to bifurcation.

Branches.

Phrenic, two or three, to diaphragm.

FIG. 13.



Cæliac axis.

Below preceding, and divides after one-half of an inch, into *gastric*, *hepatic* and *splenic*.

Gastric, by two branches to stomach, gullet and lung.

Splenic, passes to left to spleen, and gives off branches to spleen, stomach and *left gastro-omental*.

Hepatic, passes forward and to right to liver and gives off *Pancreatic*, *pyloric* and *right gastro-omental branches*.

GREAT MESENTERIC.

Arises near renal vessels two inches behind the preceding, passes downward, and after a course of $1\frac{1}{2}$ inches divides into branches to small intestine, *ilio-cæcal*, *superior* and *inferior cæcal*, *right colic*, *left colic*, small colic and some twigs to supra-renal capsules, mesentery, etc.

SMALL MESENTERIC.

Arises four to six inches behind preceding, and sends branches to the small colon and rectum.

Renal, two.

Arise near great mesenteric, and supply the kidneys and supra-renal glands.

Spermatic, two in number.

In the male are called *great testicular*, in female *utero-ovarian*. Arise near small mesenteric and pass through inguinal canal to testicle, in the female to the ovaries and cornua of the uterus.

Small testicular, male; *uterine*, female. Two in number.

Arise from bifurcation of aorta or from internal iliacs, to spermatic cord in male, and uterus and vagina in female.

Lumbar, five or six.

DISTRIBUTION OF THE EXTERNAL AND INTERNAL ILIAC ARTÈRIES IN THE MARE.

- 1, Abdominal aorta; 2, Internal iliac artery; 3, Common origin of the internal pudic and the umbilical arteries—the latter is cut; 4, Internal pudic artery; 5, Vaginal artery; 6, Lateral sacral artery; 7, Origin of the gluteal artery, which springs in this instance from the lateral sacral, a circumstance most frequently observed in the Ass; 8, Origin of the ilio-muscular artery; 9, Origin of the iliaco-femoral artery; 10, Obturator artery; 11, External iliac artery; 12, Circumflex iliac artery, cut; 13, Femoral artery; 14, Common origin of the deep femoral and pre-pubic arteries; 15, Origin of the anterior great muscular artery; 16, Origin of the saphena artery, cut; 17, Innominate branch; 18, Popliteal artery; 19, Femoro-popliteal; 20, Satellite artery of the great femoro-popliteal nerve; 21, Posterior tibial artery; 22, Its communicating branch with the saphena; 23, External plantar artery; 24, Satellite artery of the internal plantar nerve; 25, Digital artery.

Divide into *superior* branch to lumbar muscles, cord, and *inferior* to abdominal and psoas muscles.

Sacra media.

A single vessel arising at bifurcation of aorta, passes along inferior face of sacrum and gives branches to parts in vicinity.

INTERNAL ILIAC.

From aorta to insertion of small psoas, dividing into *obturator* and *ilio-femoral*.

Umbilical.

A cord to top of bladder, giving off some vesical branches.

Internal pudic, to neck of bladder, bulb of urethra, prostate and seminal vesicles. In female to vagina and uterus.

Lateral sacral.

Passes backward alongside of sacrum, gives off *middle* and *lateral coccygeal* and *ischiatric* branches.

Ilio-lumbar, to sacro-iliac joint and muscles.

Gluteal, emerges from pelvis by great sciatic notch, and supplies gluteal muscles.

Obturator, emerges from pelvis by obturator foramen, and sends branches to muscles, bladder and the *artery of the corpus cavernosum*, giving off the *posterior dorsal artery of the penis*.

Ilio-femoral.

Passes out of the pelvis with the iliacus muscle, and ends in the muscles of the thigh.

EXTERNAL ILIAC.

From end of aorta to Poupart's ligament, where it ends in the *femoral*. The vein lies to the inner side.

Branches.

Small testicular. See before.

Circumflex iliac, passes outward and divides into an anterior branch to the abdominal muscles and a posterior to the iliac muscles and skin of thigh.

FEMORAL.

From Poupart's ligament to the opening in the great adductor of the thigh, where it becomes the popliteal.

Branches.

Prepubic, lies on anterior face of Poupart's ligament, and

divides into the *posterior abdominal* (epigastric), which passes forward into rectus abdominis muscle, anastomosing with the anterior abdominal and the *external pudic*, which passes through the inguinal canal, and divides into a subcutaneous vessel on the abdomen, and the *anterior dorsal artery of the penis*. In the female this supplies the mammary gland.

Profunda, passes back behind adductors and supplies muscles of thigh and coxo-femoral joint.

Superficial muscular, to anterior crural muscles.

Small muscular, to muscles, irregular in distribution, one giving off the nutrient vessel to femur, the largest in the body.

Saphena, accompanies the saphena vein to inner side of leg, thigh, and back.

POPLITEAL.

From opening in adductor magnus, passes beneath the gastrocnemii and popliteus, and bifurcates at the tibio-fibular arch after a course of eight inches into the *anterior* and *posterior tibials*.

Branches.

Articular, to femoro-tibial joint.

Muscular, to muscles of ham; one follows great femoro-popliteal nerve.

Femoro-popliteal, passes backward and supplies muscles and nerves.

-POSTERIOR TIBIAL.

From end of popliteal to side of astragalus, where it divides into the two plantar arteries.

Branches.

Muscular.

Tarsal articular.

Nutrient artery to tibia.

Plantar, lie along tendon of perforans, and end at the suspensory ligament of the fetlock, anastomosing with the perforating pedal; forming an *arch* which gives off the *external* and *internal plantar interosseous*, which supply the metatarsal region.

ANTERIOR TIBIAL.

Along front of tibia to tibio-tarsal joint, where it becomes the *pedal*. It gives off muscular branches and one along fibula, the analogue of the *peroneal* of man.

PEDAL.

Divides opposite the second tarsal row into the *perforating pedal*, which passes between cuboid and scaphoid to anastomose with plantars and *collateral artery* of the *cannon*. This passes downward, then backward between external and middle metatarsus, then down to top of fetlock, where it divides into the two *collateral arteries* of the *digits*, which pass downward to the basilar process of the pedal bone, dividing into the *plantar* and *preplantar unguis*.

Branches.

To upper bones of digits, joints, tendons, etc.

To *plantar cushion*.

Coronary circle, to structures around os coronæ.

Pre-plantar, enter foramina in os pedis.

Plantar, passes into plantar fissure, plantar canal and semilunar sinus, uniting with opposite to form the semilunar anastomosis.

PULMONARY ARTERY.

Arises from right ventricle, passes upward and backward dividing into two branches, which enter the lungs and ramify in them. At its middle is a fibrous cord, running to the arch of the aorta, the remains of the *ductus arteriosus* of foetal life.

The artery carries venous blood to the lungs for oxygenation.

THE VEINS.

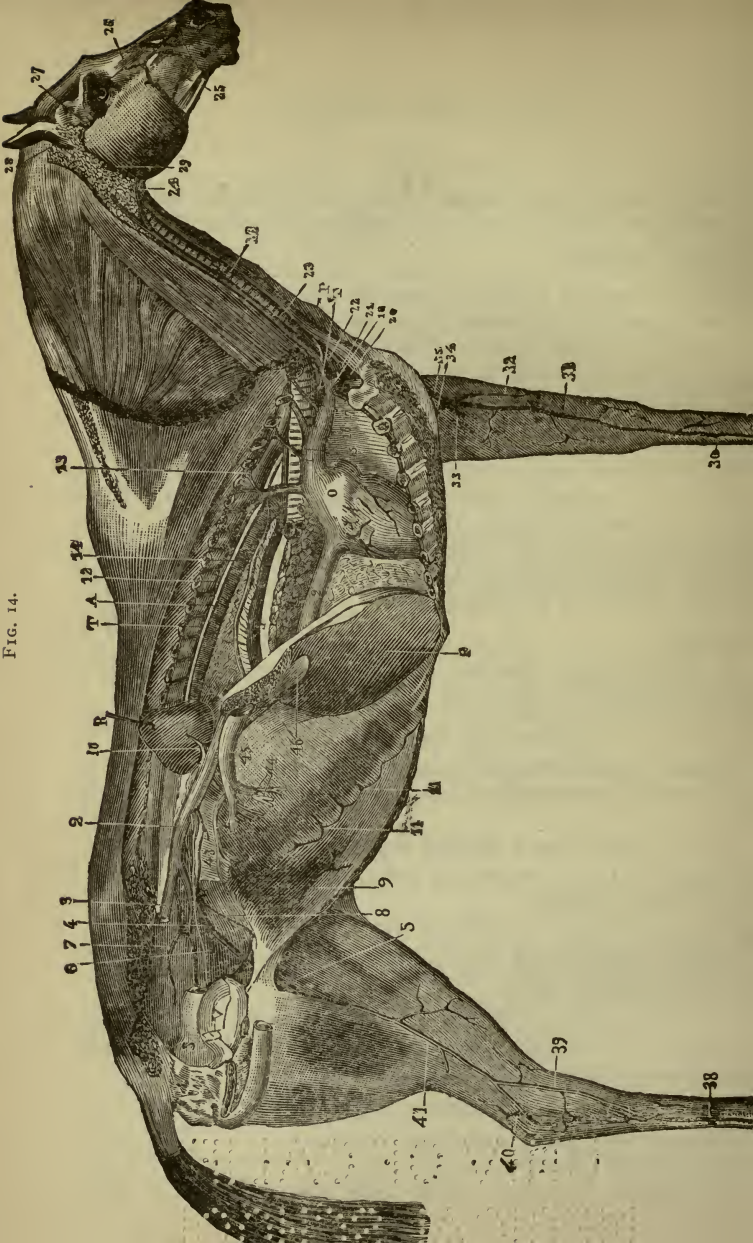
The veins carry venous blood from the periphery to the heart, except the pulmonary, that carry arterial blood to the left heart. They have three coats, an internal serous, middle muscular and external fibrous. In the lumen of the veins are valves with their concavity toward and their convexity away from the heart. They are absent in the pulmonary and portal veins and vena cava and very large and numerous in the extremities.

The *venæ comites* are two veins accompanying each small artery; the larger arteries have only one.

Coronary.

Small branches and *great coronary* empty into right auricle after receiving the bronchial veins.

FIG. 14.



FOREARM.

Anterior and posterior radial, ulnar, median ending in basilic, cephalic or plat, and subcutaneous radial. Into these empty the veins that accompany the corresponding small arteries of the metacarpal and digital regions.

POSTERIOR CAVA.

Begins at entrance of pelvis by union of common iliac veins, passes forward and to right, grooves liver, through diaphragm, and ends at the right auricle of heart.

Branches.

Phrenic, 3.

Portal vein.

Formed by junction of *small mesenteric, great mesenteric and splenic*, similar to the same arteries. It begins near the great mesenteric artery, passes through the pancreatic ring, and divides in the great posterior fissure of the liver to enter its structure.

The right gastro-epiploic vein and gastric enter the cava near the posterior fissure.

Renal, two, similar to arteries; left is longer.

FIG. 14.—GENERAL VIEW OF THE VEINS IN THE HORSE.

- 1, Anterior vena cava; 2, 2, Posterior vena cava; 3, Right pelvi-crural trunk, divided at the ilio-sacral articulation; 4, Left pelvi-crural trunk; 5, Femoral vein; 6, Obturator vein; 7, Sub-sacral vein; 8, Left testicular vein; 9, Posterior abdominal vein; 10, Renal vein; 11, 11, Ascending branches of the aternal vein; 12, Vena azygos, with its intercostal branches, and in front the sub-dorsal venous branch; 13; 14, Oesophageal vein; 15, Dorsal, or dorso-muscular vein; 16, Cervical, or cervico-muscular vein; 17, Vertebral vein; 18, Right axillary vein, cut at the anterior border of the first rib; 19, Sub-sternal, or internal mammary vein; 20, Left axillary artery; 21, Termination of the left cephalic vein; 22, Left jugular; 23, Right jugular; 24, External maxillary, or glosso-facial vein; 25, Coronary vein; 26, Angular vein of the eye; 27, Sub-zygomatic vein; 28, Posterior auricular vein; 29, Maxillo-muscular vein; 30, Internal metacarpal vein; 31, Median subcutaneous vein; 32, Radial subcutaneous vein; 33, Posterior radial vein; 34, Basilic vein; 35, Plat, or cephalic vein; 36, Coronary venous plexus; 37, Digital vein; 38, Internal metatarsal vein; 39, Anterior root of the internal saphena vein; 40, Posterior root of ditto; 41, Internal saphena; 42, Great coronary vein; 43, Small mesaraic vein; 44, Different branches of the great mesaraic vein; 45, Trunk of the vena portæ in its sub-lumbar portion, lodged in the pancreas; 46, The same in the posterior fissure of the liver; below it is seen entering the substance of the gland,—M, Subscapular hyoideus muscle cut obliquely in the direction of the trachea; P, Cervical panniculus turned down to expose the jugular channel; o, Right auricle of the heart; A, Posterior aorta; c, Section of the right lung; F, Left lobe of the liver behind the section of the diaphragm; R, Right kidney carried up and forward; L, Oesophagus; v, Bladder; s, Rectum; T, Thoracic duct; T', Termination of that duct in the confluent of the jugulars.

Spermatic, follow the artery in male or female.

Lumbar, follow arteries.

Common iliacs.

Unite under second lumbar body to form cava.

The *common* and *external iliacs* follow the course of the arteries and receive similar branches.

Femoral vein follows artery, as does the *popliteal, anterior* and *posterior* tibial.

Internal saphena.

Superficial in position from metatarsal veins, passes along inner side of leg and thigh, and empties into femoral or external pudic.

External saphena.

Begins outside calx and ends in popliteal vein.

Metatarsal.

Internal, external and middle.

Digital.

As in anterior limb.

PULMONARY VEINS.

Are four to eight in number and extend from root of lung to the left auricle. They carry arterial blood and are destitute of valves.

LYMPHATICS.

The lymphatics are vessels with very thin and transparent walls, found all over the body, except in blood-vessels, nervous tissue, bone, muscles, eyeball, cartilage, tendons, the membranes of ovum, placenta, umbilical cord, cuticle or hair. They possess nutrient vessels, no nerves, have valves, and carry lymph or chyle into the vascular system.

The *lymphatic glands* are small ovoid bodies in the course of lymph channels; they exist as groups in the *sub-lumbar, inguinal, popliteal, iliac, femoral, pre-pectoral, pharyngeal, pre-scapular, mediastinal* and *bronchial regions*.

They have a special capsule and are composed of reticular tissue. The lymphatics break up into smaller ones before reaching the gland, called the *afferent* vessels, and are united again on the opposite side as the *efferent* vessels.

THORACIC DUCT.

Receives all the lymphatics except those of the right side of

the head, neck, thorax and right anterior limb. Begins at the first lumbar vertebra as a cistern, the "*receptaculum chyli*." The duct then passes forward through the pillars of the diaphragm to the *sixth dorsal* vertebra, where it passes to the left and empties, after a dilatation, into the anterior cava at the junction of the jugulars.

RIGHT LYMPHATIC DUCT.

Opens at junction of jugulars and is guarded by a valve. It is about two inches long and receives all the lymphatics that do not empty into the great duct.

NERVOUS SYSTEM.

This system is divided into the *cerebro-spinal*, presiding over animal life, and *sympathetic*, over organic life.

It is composed of *white fibres*, *gray vesicles* in a stroma of *neuroglia* or connective tissue, and a *gelatinous* material in the sympathetic.

The *white* nervous tissue is composed of an outer envelope or *tubular membrane*, a middle coat called the *white substance of Schwann*, and a central portion which transmits nervous impulses, the *axis cylinder*. Outside a *nerve* which comprises a number of the preceding we find a covering, the *neurilemma*; sensory nerves terminate at the periphery in many different ways, motor nerves as small plexuses on the muscle cells.

CEREBRO-SPINAL SYSTEM.

Consists of the brain, spinal cord, ganglia and nerves.

SPINAL CORD.

The portion of the nervous system enclosed in the spinal canal and extending from the occipital foramen to the upper third of the spinal canal. Its weight is $10\frac{1}{2}$ ounces; it is flattened above and below, and has two enlargements in its course, one between the fifth cervical and second dorsal, the *brachial*, the other below, the *crural*.

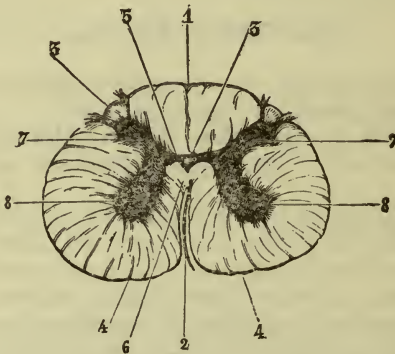
The *structure* is externally white matter, internally gray, arranged like two horns, the larger ends pointing down and out, not

reaching the surface; the smaller look upward and outward, reaching the surface. The two horns are connected by a transverse band, called the commissure, which shows in its middle the central canal of the cord.

Fissures.

Running the whole length of the cord above and below are two fissures; the superior longitudinal is narrower and more shallow than the inferior, which is separated from the *gray commissure* by a white band, the *white commissure*.

FIG. 15.



SECTION OF THE SPINAL CORD OF THE HORSE AT THE LUMBAR REGION; MAGNIFIED TWO DIAMETERS.

- 1, Superior median fissure; 2, Inferior median fissure; 3, 3, Superior collateral fissures; 4, 4, Inferior ditto; 5, Gray commissure; 6, White commissure; 7, 7, Superior gray cornua; 8, 8, Inferior gray cornua; 9, Central canal.

Columns.

The *superior column* lies between the superior fissure and superior or sensory nerve roots.

The *inferior*, between the inferior fissure and the inferior or motor roots.

The *lateral* lies between the two.

Membranes.

Dura mater, outer, is not adherent to bony canal.

Arachnoid, as in brain.

Pia mater, passes into fissures and on sides has festoons at-

tached to the *dura*, the *ligamentum dentata*. Its posterior extremity forms a narrow prolongation, the *filum terminale*.

BRAIN.

This is the central portion of the nervous system, situated in the cranial cavity.

Membranes.

The *dura mater*, externally is a strong fibrous membrane, adherent to the bony walls, giving off prolongations into the brain and forming depressions for the venous sinuses (see *Veins*). It also is prolonged on the nerves. The prolongations of the *dura* are the (A) *falx cerebri*, passing between the two hemispheres of the brain and attached to the *crista galli*. It contains in its meshes small tubercles, the *pacchionian bodies*.

(B) *Tentorium cerebelli*, which forms a horizontal partition between the cerebrum and cerebellum, and attached to the parieto-temporal crest, and parietal protuberance.

(C) *Pituitary fold*, circumscribes the *sella turcica* and envelops the pituitary gland.

The *arachnoid* is the middle membrane, composed of a basement membrane, attached to the *dura* externally and a covering of flattened endothelium internally. It is not properly a vascular membrane. It does not pass into the fissures or convolutions, and between it and the *pia* is a space filled with cerebro-spinal fluid, the sub-arachnoid space.

Pia mater.

The most internal of the membranes; is of thin structure, holding in its meshes a large number of blood-vessels which have perivascular lymph spaces about them. The *pia* passes into all the inequalities of the surface of the brain, and supplies it with blood.

Weight.

In the horse, 22 ounces, 15 drachms; ox, 16 ounces, 15 drachms.

In human male, 49½ ounces.

Parts of the brain.

Cerebrum, or large brain; *cerebellum*, or small brain; the *isthmus* and *medulla oblongata*.

Medulla Oblongata.

The medulla is the upper expanded portion of the cord, ending at the pons, and rests on the basilar process. It shows the *su-*

perior median and *inferior median fissures*, the latter separating to form the fourth ventricle, the point of divergence being called the *calamus scriptorius*.

Columns.

The inferior median columns are continued as the *pyramids*; outside these are two oblong elevations (the olivary bodies of man), in front of which arise the sixth, and behind, the twelfth nerves.

The *superior median column* is continued in the medulla as the *restiform body*.

The *lateral tracts* are the continuation of the lateral columns.

The Isthmus.

Is the prolongation of the medulla, supporting the cerebellum, and terminating in the cerebrum. Its component parts are the *pons Varolii* or *mesencephalon*, *crura cerebri* and *cerebelli*, *valve of Vieussens*, *corpora quadrigemina*, *thalami optici*, *pineal* and *pituitary glands*.

Pons varolii.

The *pons* is an elevated mass of white transverse fibres thrown between the two halves of the cerebellum; it rests in a depression on the basilar process, and below presents a longitudinal median groove for the basilar artery (see *Arteries*). The *crura* pass above it.

Crura cerebri.

The *crura* are two white bands continuous with the fibres of the medulla, entering the hemispheres of the cerebrum in front and in contact with the optic thalami and quadrate bodies above, the pons below. In front they pass under the optic tracts, which here unite and form the optic commissure. The *crura* also separate anteriorly to enclose the *corpus albicans*.

Crura cerebelli.

The cerebellar *crura* are composed of three fasciculi:—

1. *Crus cerebelli ad pontem*—the pons' transverse fibres.
2. *Crus ad medullam*—the restiform bodies of the medulla.
3. *Processus e cerebello ad testes*; or anterior *crura* to the testes of the *corpora quadrigemina*.

The *valve of Vieussens* is a thin, transverse layer, which passes between the anterior cerebellar *crura*. It forms part of the roof of the fourth ventricle.

The *corpora quadrigemina* are four small bodies which lie

above the *crura cerebri*; the anterior pair, or the *nates* are gray; the posterior, or *testes*, are white.

The *optic thalami* are two masses of gray matter placed above the *crura cerebri*; they are separated by a deep groove, and form the sides of the *third ventricle*. At their posterior border are found two projections, the *external* and *internal geniculate bodies*.

The *pineal gland* or *conarium* is a cone-shaped body, of a reddish brown color, situated in front of the *testes*, with two peduncles passing forward on the inner sides of the *optic thalami*. It is composed of amorphous tissue, holding salts of lime, etc.

The *pituitary gland* is a small, circular body attached by the *infundibulum* to the *tuber cinereum*, a layer of gray matter in the floor of the *third ventricle*. It has no cavity or definite structure. (For interior of isthmus see *Ventricles*.)

Cerebellum.

The cerebellum is that part of the brain situated behind and beneath the cerebrum, above the isthmus and separated from the cerebrum by the tentorium.

It is divided into three lobes by a median constriction, which is divided into the *superior* and *inferior vermiform processes*.

The lateral lobes are convex, and show many convolutions or depressions.

Structure.

Gray *externally*, white *internally*, with a tree-like arrangement called the *arbor vitæ*.

Cerebrum.

The cerebrum is composed of two portions, the hemispheres elongated antero-posteriorly, separated by a deep fissure running in the same direction and united by a transverse commissure—the *corpus callosum*.

The longitudinal fissure.

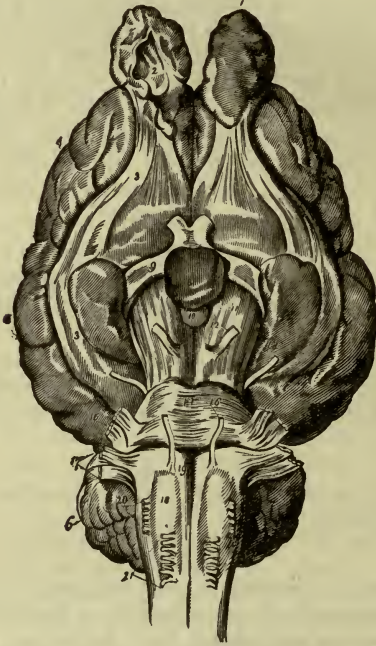
This passes antero-posteriorly, separating the two hemispheres, and bounded below by the *corpus callosum*. Behind, at the anterior and superior portion of the medulla, it changes its direction, transmits the *velum interpositum*, and is called the *fissure of Bichât* or *transverse fissure*. The longitudinal fissure lodges vessels and the *falx cerebri*.

The *fissure of Sylvius* is a transverse depression in front of the mastoid lobule, lodging the middle cerebral artery.

Lobes.

The *olfactory* or *ethmoid* is a detached portion lying below and in front of the anterior portion of the cerebrum. It arises by two

FIG. 16.



GENERAL VIEW OF THE BRAIN; LOWER SURFACE.

- 1, Olfactory lobe; 2, Cavity of the olfactory lobe; 3, External root of the olfactory lobe; 4, 5, Cerebral hemispheres; 6, Cerebellum; 7, Optic chiasma, or commissure; 8, Pituitary gland; 9, Optic nerves; 10, Tuber cinereum; 11, Crus cerebri; 12, Third cranial nerve; 13, Fourth nerve; 14, Pons Varolii; 15, Fifth nerve; 16, Sixth nerve; 17, Seventh and eighth nerves; 18, Medulla oblongata, the number being placed on the olivary body; 19, Anterior pyramid; 20, Roots of ninth, tenth, and eleventh nerves; 21, Twelfth nerve.

roots, one from the outside of the mastoid lobe and one near the optic chiasm. The enlargement or *bulb* lies on the ethmoidal fossa, and has an internal cavity communicating with the lateral ventricle (see *First Nerve*).

Mastoid or *sphenoid lobe* represents the middle lobe of man; its margins form the *transverse fissure* and *fissure of Sylvius*. Its interior forms a cavity, the reflexed portion of the lateral ventricles. The *convolutions* of the brain are numerous and distinct, but do not call for a detailed description.

INTERIOR OF THE BRAIN.

The *corpus callosum* is the transverse commissure between the hemispheres and seen on separating them. On its *top* are seen the *nerves of Lancisi* running on its long axis. Its *inferior* surface forms the roof of the lateral ventricles separated by the *septum lucidum*. Its *sides* end in the interior of its hemispheres. Its *hinder border* forms the *splenium* (or pad), turns forward as the *genu* (or knee), and is continuous with the fornix. Its *anterior portion* ends in the cerebral substance.

THE VENTRICLES.

These are cavities in the interior of the brain as follows—

Lateral Ventricles (two, below the callosum).

Third Ventricle, between the *thalami optici*.

Fourth Ventricle, between the diverging restiform bodies of medulla. (The cavity between the lamellæ of the *septum lucidum*, the *fifth ventricle* of man, is absent in the horse.)

LATERAL VENTRICLES.

Are lined by a serous membrane, the "*ependyma*," and bounded—

Above, by corpus callosum.

Below, by *corpus striatum*, *fornix*, *hippocampus*, and *choroid plexus*.

Internally, by septum lucidum.

Externally, by brain structure.

Anteriorly, continued into cavity of olfactory lobe.

Posteriorly, continued downward and upward into the mastoid lobe.

It communicates below and in front by two openings, the *foramina* of *Monro*, with the *third ventricle*.

The *septum lucidum* is a thin partition of white matter between the lateral ventricles.

The *fornix*, a single body between the third and lateral ventricles, is continuous behind with the *callosum*. It is composed of white matter, terminating behind in two prolongations, the poste-

rior pillars, ending in the hippocampus, in front by two similar ones, which form the *corpus albicans*. They form the anterior boundaries of the *foramina* of *Monro*.

The *hippocampi* are nuclei of gray, covered with white matter, on the floor of the lateral ventricle. They are formed by the bending in of the convolution above the corpus callosum and present a flattened border, the *corpus fimbriatum*.

The *corpus striati* are projections on the floor of the lateral ventricles, of gray and white tissue in lamellæ. They are separated from the thalami by long bands, the *tæniæ semicirculares*. They are divided into two parts, the intra-ventricular and extra-ventricular nuclei.

The *choroid plexus* is a process of the pia that passes in by the great transverse fissure, becomes the *velum interpositum*, passes from the lateral to the third ventricle and beneath the fornix. Their veins form the *venæ galeni*, which end in the sinus of the falx.

THE THIRD, OR VENTRICLE OF THE THALAMI OPTICI.

Boundaries.

Roof, optic thalami meet together.

Floor, lamina cinerea.

Sides, optic thalami and peduncles of pineal gland.

Communications.

In front, foramen of *Monro* with lateral ventricles.

Behind, the *iter a tertio ad quartum ventriculum*, or *aqueduct* of *Sylvius*, passing under the corpora quadrigemina to end in the fourth ventricle.

Running across the cavity are also seen the *anterior white commissure* between the corpora striata, and the *posterior white commissure* between the thalami, behind. *The gray commissure* is simply the coming together of the thalami forming the roof.

THE FOURTH, OR CEREBELLAR VENTRICLE (see *Medulla*).

Boundaries.

Roof, valve of *Vieussens* and cerebellum.

Floor, medulla and pons.

Sides, restiform body and *processus e cerebello ad medullam*.

Anteriorly, continuous with *aqueduct* of *Sylvius*.

Posteriorly, summit of *calamus scriptorius*.

Structure of the Brain.

Gray structure externally and dipping down into the convolutions. There are seven layers in the cortical substance (Kölliker).

The white substance is found internally and runs, as fibres, in various directions.

THE CRANIAL NERVES.

There are twelve in number (Sömmering).

1st, or Olfactory. Nerve of smell (see *Smell*).

Superficial Origin.—See *Olfactory lobe*.

Deep Origin.—Corpus striatum and transverse fibres of pons.

Exit.—Through cribriform plate of ethmoid.

Distribution.—To nasal septum and ethmoidal cells in upper third of nasal fossæ.

Function.—Well marked and presides over sense of smell.

2d, or Optic.

Origin.—From commissure and optic tracts which arise from thalamus and corpora quadrigemina.

Exit.—Optic foramen.

Distribution.—To retina (see *Eye*).

Function.—Nerve of sight.

3d, or Oculo-motor.

Superficial Origin.—From crura near to interpeduncular fissure.

Deep Origin.—Anterior border of pons.

Exit.—Smallest supra-sphenoidal foramen of orbit.

Distribution.—To all muscles of eye except external rectus, great oblique and part of the posterior rectus, and by ophthalmic ganglion to the iris.

4th, or Patheticus.

Superficial Origin.—Band of Reil behind corpora quadrigemina.

Deep Origin.—From interior isthmus.

Exit.—By smallest supra-sphenoidal foramen to orbit.

Distribution.—To great oblique muscle.

5th, or Trifacial.

Superficial Origin.—By two roots, the larger, or sensory, from the sides of the pons, the motor from pons, near the other.

Deep Origin.—Sensory root from restiform body of medulla, the interior cells of the isthmus and nuclei of other nerves. Motor root from antero-lateral fasciculus of medulla.

Course.—Has a large ganglion developed on the sensory root, the *Gasserian*, resting on the cartilage of the occipito-sphenotemporal hiatus, and divides into the (1) *ophthalmic*, (2) *superior maxillary* and (3) *inferior maxillary divisions*.

Exit.—The first branch passes through the smallest of the large supra-sphenoidal foramina to the orbit. The second passes through the foramen rotundum to the orbit. The third passes through the *foramen ovale* to the temporo-maxillary articulations.

1. *Ophthalmic Nerve.*—To skin of forehead, eyelid, lachrymal gland and nasal fossa.

2. *Superior Maxillary.*—Passes along infra-orbital canal, where it ends in small branches to the face and upper lip. It sends branches to the eyeball, palate, nose and teeth of the upper jaw.

3. *Inferior Maxillary.*—The motor root unites with this, passes down, enters inferior dental canal, supplies the muscles of mastication, teeth of lower jaw.

Branches are—

Muscular superficial, temporal, gustatory, to tongue, mylo-hyoid and mental.

Sympathetic Ganglia of Fifth.

OPHTHALMIC OR CILIARY.

Situation.—Near nerve to inferior oblique muscle of orbit.

Motor Root.—From third.

Sensory Root.—Nasal branch of ophthalmic.

Sympathetic Root.—Cavernous plexus.

Distribution.—Ciliary nerves to iris.

SPHENO-PALATINE OR MECKEL'S.

Situation.—In space between orbit and foramen rotundum.

Motor Root.—Vidian nerve of seventh.

Sensory Root.—Superior maxillary.

Sympathetic Root.—Cavernous plexus by Vidian.

Distribution.—To orbit and palate.

OTIC OR ARNOLD'S.

Situation.—Near origin of inferior maxillary nerve and Eustachian tube.

Motor Root.—Small petrosal from seventh.

Sensory Root.—Buccal nerve.

Sympathetic Root.—From plexus on inferior maxillary artery.

Distribution.—To tensor palati, tensor tympani, Eustachian tube and pterygoid muscles.

6th, or Abducens.

Superficial Origin.—From medulla, behind pons.

Deep Origin.—From inferior pyramid and lateral tract of medulla.

Exit.—With ophthalmic branch of fifth.

Distribution.—To external rectus muscle of eye.

7th, or Facial.

Superficial Origin.—From medulla, behind pons.

Deep Origin.—Floor of fourth ventricle.

Exit.—Through internal auditory meatus with eighth; enters the aqueduct of Fallopius; has a ganglion developed on it, the geniculate; passes out of the stylo-mastoid foramen to the muscles of face and subcutaneous of neck.

Branches.

Great petrosal, to Meckel's ganglion.

Small petrosal, to otic.

Tympanic, to stapedius.

Chorda tympani, to tongue and mouth.

Muscular, to occipito-styloid, digastric, stylo-hyoid and subcutaneous muscle of neck.

Auricular, to ear and face.

8th, or Auditory.

Superficial Origin.—Restiform body.

Deep Origin.—Below seventh.

Exit.—With seventh, by *cochlear* and *vestibular* branches to ear.

9th, or Glosso-pharyngeal.

Superficial Origin.—Medulla, below eighth.

Deep Origin.—Floor of fourth ventricle.

Exit.—By posterior foramen lacerum to back part of tongue and pharynx.

Branches.

Jacobson's nerve (tympanic), *carotid*.

Communicating with sympathetic, *pharyngeal*.

10th, or Pneumogastric.

Superficial Origin.—Antero-lateral tract of medulla.

Deep Origin.—Floor of fourth ventricle.

Exit.—By posterior lacerated foramen, above carotid artery, to front of thorax, dividing into *bronchial* and *æsoophageal*.

Branches.

Communicating to eleventh, superior and inferior cervical ganglia.

Superior laryngeal, to mucous membrane of larynx and crico-thyroid muscle.

Inferior laryngeal, to all muscles of larynx except crico-thyroid.

Bronchial, to bronchi and lungs.

Æsoophageal, to œsophagus, stomach, liver and solar plexus.

11th, or Spinal Accessory.

Superficial Origin.—Lateral tract of medulla, along whole cervical region of cord.

Deep Origin.—Fourth ventricle.

Exit.—Up through foramen magnum and foramen lacerum to neck, and follows mastoideo-humeralis.

Branches.

To *cervical sympathetic*, *sterno-maxillaris*, *mastoideo-humeralis*, *cervical* and *dorsal trapezius* and *cervical nerves*.

12th, or Hypoglossal.

Superficial Origin.—Side of medulla near inferior spinal roots.

Deep Origin.—From fourth ventricle.

Exit.—Condylod foramen.

Branches.

To muscles of tongue.

SPINAL NERVES.

They are 42 or 43 pairs that leave the spinal canal by the intervertebral foramina. The superior or sensory roots have a ganglion developed on them. The motor and sensory roots unite and soon after divide into a superior branch to the spinal muscles and integument, and an inferior to the lower part of the trunk and extremities. Their relative number in the different regions are—*cervical*, 8; *dorsal*, 18; *lumbar*, 6; *sacral*, 5; *coccygeal*, 6 or 7.

CERVICAL NERVES.

Eight in number. Divided into superior branches which anastomose freely, forming the *deep cervical plexus*, and send filaments to muscles, nerves and integument of sides and top of neck. The inferior branches supply the structures on the under side of the neck, forming the superficial cervical plexus, and the sixth, seventh and eighth form a portion of the brachial plexus.

Branches.

Phrenic nerves, from the fifth and sixth cervical, and branch from the brachial plexus, pass down inside thorax to front of *diaphragm*, which they supply.

BRACHIAL PLEXUS.

A large fasciculus of nerves which supply the anterior limb and anterior portion of the chest and neck.

Formation.—By inferior branches of sixth, seventh, and eighth cervical and first two dorsal nerves, which unite and subdivide opposite the scapulo-humeral joint into branches to the thorax and anterior extremity.

Branches.

Muscular, to *angularis scapulæ*, *rhomboideus*, *latissimus dorsi*, *teres major*, *subscapularis*.

Superior thoracic (or external respiratory of Bell), to *serratus magnus*.

Pectoral or *inferior thoracic*, to superficial and deep pectorals.

Subcutaneous thoracic, follows spur vein and supplies *panniculus carnosus* and subcutaneous muscles of neck.

Circumflex, to *abductors* of limb, *teres major*, *levator humeri*, shoulder-joint and integument about shoulder.

Super-scapular, from sixth and seventh cervical to antea- and postea-spinati.

Musculo-cutaneous, from seventh and eighth, crosses axillary artery, passes down front of arm between two insertions of *coraco-humeralis*, supplying it and the *coraco-radialis*.

Radial (largest branch of plexus), passes down parallel with humeral artery, follows short flexor of forearm and radial artery to *oblique extensor of metacarpus*.

FIG. 17.

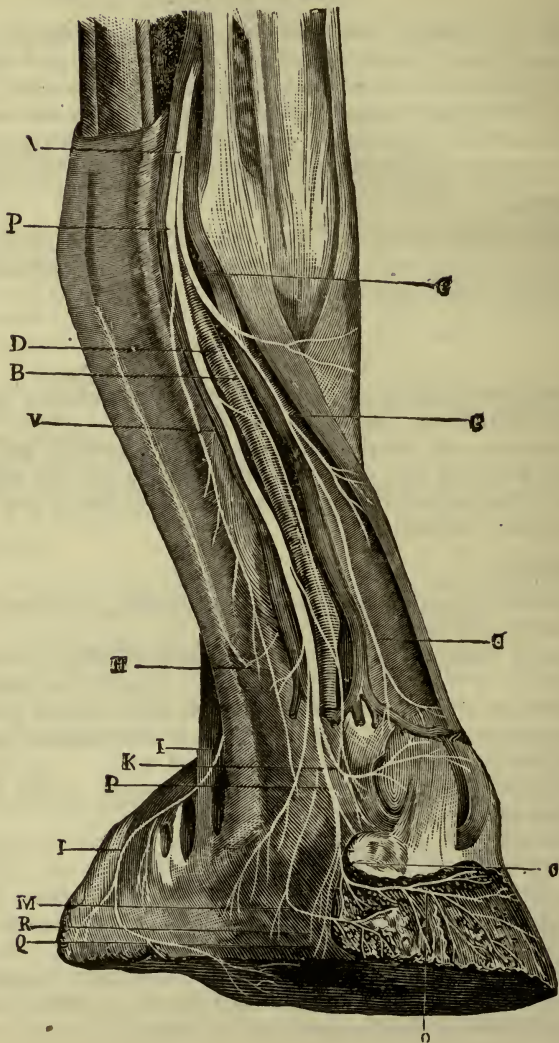


FIG. 17.—NERVES OF THE DIGIT.

p, Plantar nerve; b, Median branch; c, Anterior branch; d, Digital artery; h, Inconstant division given off to the cartilaginous bulbs; i, i, Branch to the plantar cushion; k, Transverse coronary branch; m, Podophyllous branch; o, Pre-plantar branch; q, Descending ramuscle to the fissure of the patilobes; r, Ramuscles accompanying the digital artery in the plantar fissure; v, Vein whose presence is not constant, and which sometimes accompanies the plantar nerve throughout its phlangeal course.

Branches.

To extensors of forearm, metacarpus and digit, and external flexor of metacarpus, and sensation to integument of anti-brachial region.

Ulnar, passes down behind humeral artery to inner side of elbow, follows oblique flexor of metacarpus to pisiform bone, where it divides into the *cutaneous* to skin of anti-brachial carpal and external metacarpal regions and *external plantar*. It gives off branches in its course to long extensor of forearm and pectorali, to all muscles of posterior brachial region, except external and internal flexors of metacarpus.

Median, arises from posterior part of plexus and a branch from musculo-cutaneous, passes down in front of humeral artery, along inner side of forearm, then lies anteriorly again and bifurcates at lower one-third of forearm into *external* and *internal plantar*.

Branches.

To *flexors of forearm* and subcutaneous region of forearm. The plantars give off the anterior, middle and posterior digital at the fetlock, which supply the phalangeal region.

LUMBO-SACRAL PLEXUS.

Formed by last two lumbar and first three sacral nerves. Divided into an anterior division lying under the *psoas parvus*, and a posterior behind the internal iliac artery. The *anterior* is formed by the last two lumbar, and gives off *ilio-muscular* to iliacus muscle.

Crural or *anterior femoral*, to muscles of thigh, and by *saphenous* branches to skin of inner side of thigh and leg.

Obturator, passes out of oval foramen to *adductors* of thigh, *pectineus*, *short adductor* of leg and *obturator externus*.

The *posterior* is formed by first three sacral, and gives off

small sciatic, which emerges from great ischiatic notch and divides into *anterior gluteal*, to *middle* and *small glutei*, *tensor vaginal femoris*, and *posterior gluteal* to *glutei*, *triceps cruris* and sensation to posterior part of thigh.

Great sciatic emerges from great sciatic opening, passes along posterior part of thigh on adductors, between two heads of gastrocnemii, along inner side of hock, and ends in *external* and *internal plantars*.

Branches.

Muscular to *obturator internus*, *gemelli*, *quadratus femoris*, *triceps cruris*, *semi-tendinosus*, *semi-membranosus*, *great adductor of thigh*, and *posterior tibial muscles*.

External popliteal arises near *gemelli* muscles, passes downward and outward to upper part of leg, where it terminates in the *musculo-cutaneous*, which supplies the extensors of the phalanges and skin of metatarsal region, and *anterior tibial*, which lies to outer side of artery, giving off muscular and cutaneous branches.

Branch.

Peroneal-cutaneous, with external saphenous vein to skin of leg.

Plantar nerves pass to outer and inner sides of metatarsus, and are distributed like the analogous structures in the anterior foot.

DORSAL NERVES.

Divided into *superior* branches, which supply skin and muscles of spinal region, and *inferior*, which send branches down into the intercostal spaces to muscles of chest, by first seven pairs, and muscles and skin of abdomen by remainder. In the middle of their course they give off a cutaneous branch, which supplies the skin and cutaneous muscles. The first and second form part of the brachial plexus.

THE SYMPATHETIC NERVOUS SYSTEM.

This consists of two long cords lying under the spinal column, from the head to the tail, probably ending in a ganglion under the coccygeal vertebræ.

In its course are many ganglia, which are composed of the *gelatinous fibres of Remak*, and send branches to the cerebro-

spinal system, viscera and blood-vessels, forming the *vasomotor system*.

The system is divided into *cephalic, cervical, dorsal, lumbar* and *sacral portions*.

CEPHALIC consists of three ganglia of fifth nerve (see same).

CERVICAL, two ganglia.

1. *One Superior*, lying in front of atlas, on carotid.

Branches.

Communicating, to ninth, tenth, eleventh and twelfth nerves, and fifth cervical.

Carotid, on internal carotid, also to cavernous sinus. Vidian nerve and cephalic ganglia.

Inferior carotid, to external carotid, guttural pouch, salivary glands and pharynx.

2. *One Inferior*, near insertion of scaleni on first rib.

Communicating, to tenth and cervical nerves.

Cardiac nerves, 5; two from left and three from right, to heart, bronchi and lungs.

DORSAL consists of 17 ganglia, below vertebro-costal joints.

Branches.

Small ones to chest and pleura.

Great splanchnic.

From the sixth to fifteenth, to abdomen through arch of psoas parvus, and near cœliac axis, and ends in *solar plexus*, which sends branches to stomach, liver, spleen, intestine, kidneys and their capsules.

Lesser splanchnic.

From fifteenth, sixteenth and seventeenth, to solar plexus, to kidney and supra-renal bodies.

LUMBAR, six in number, lie on psoas parvus.

Branches.

Posterior mesenteric plexus, to small colon and rectum.

Spermatic plexus, to spermatic vessels.

Pelvic plexus, to pelvic viscera.

SACRAL, four in number beneath sacrum. Small branches to sacral regions and vessels.

VISCERAL ANATOMY.

DIGESTIVE SYSTEM.

The digestive system is that part in which the great processes of digestion and absorption take place, as well as the expulsion of the residue after the latter.

The parts included are named from before, backward, the *mouth*, *pharynx* and *œsophagus*, that carry the food to the abdominal organs, the *stomach* and *intestines*.

The annexed organs are the *salivary glands* to the mouth, the *liver* and *pancreas* to the intestines.

THE MOUTH.

The mouth is a cavity between the two jaws, and having an *anterior opening* between the lips and a *posterior*, the soft palate separating it from the pharynx. On the *sides* are the cheeks; *below*, the tongue.

Tongue.

This is a flattened muscular organ, elongated antero-posteriorly and fixed to the hyoid and inferior maxilla. It presents *calyciform papillæ* on the dorsum near the base, arranged in a V shape. At the apex of this are two depressions, the *foramina cæca*. *Filiform papillæ* at the middle of dorsum of tongue. *Fungiform papillæ*, club-shaped, on posterior $\frac{1}{3}$ of dorsum. A *fibrous cord* (the cartilage of the tongue), 3 or 4 inches long, under the mucous membrane.

Muscles.

Intrinsic, of vertical, longitudinal and transverse fibres. *Extrinsic*, see *stylo-glossus*, *hyo-glossus*, *genio-glossus* and *hyo-glossus minimus*.

Action.—See *Deglutition*.

Nerves.—Lingual, ninth and twelfth.

Blood Supply.—Lingual and sublingual.

Palate.

See *Muscles*.

Blood Supply.—Ascending pharyngeal and internal maxillary.

Nerves.—From superior maxillary and Meckel's ganglion of the fifth.

Teeth.

They are passive agents in mastication, and are in number 40 in the male, 36 in the female—viz., in each jaw 6 incisors, 12 molars, in male two canines in addition.

Parts.

Crown, fang, neck and dental pulp.

Structure.

Ivory or dentine, outside of pulp cavity.

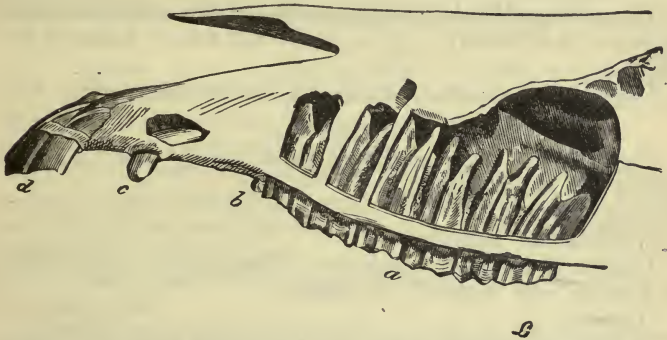
Cement, covering the dentine.

Enamel, covers free portion of tooth, formed of small rods.

Incisors.

Are pyramidal, flattened from before, backward, with a single

FIG. 18.



PROFILE OF THE UPPER TEETH OF THE HORSE, MORE ESPECIALLY INTENDED TO SHOW THE MOLARS; THE FANGS HAVE BEEN EXPOSED.

a, Molar teeth; *b*, Supplementary molar; *c*, Tusk; *d*, Incisors.

fang; they are called in each half of a jaw, the *pincer*, *intermediate* and *lateral* from within outward.

Canines, fangs or tusks.

Found only in male, between the incisors and molars, the space between them and the latter is called the *bar*. They are pointed, have a single fang and grow but once.

Molars.

The crowns are flattened and undulated, and communicate with the interior of the fangs, which are at first hollow, then filled with dentine.

The fangs are three in number; in the terminal molars, both above and below, the intermediate four in the upper and two in the lower.

SALIVARY GLANDS.

These secrete saliva, which exerts a chemical and mechanical action on the food in the mouth, into which the secretion is poured.

They are the parotid, sub-maxillary, sublingual, molar, labial, lingual and palatine.

The *parotid* lies behind the angle of the lower jaw, is the largest, and its duct (Steno's) opens opposite the third upper molar.

The *sub-maxillary*, lies in the intermaxillary space outside the larynx, its duct (Wharton's) opens at the side of the frænum on a small tubercle, the *barb*.

The *sublingual* lies in the intermaxillary space, under the tongue, its ducts (of Rivinian), 15 to 20, open near that of Wharton on a ridge.

The *molar* are two on each side opposite the molar teeth.

PHARYNX.

The pharynx is an elongated cavity behind and above the mouth and nasal cavities.

Coats.

Muscular, see *Muscles*.

Mucous of basement membrane, covered above with ciliated and below with flattened epithelium.

Openings, 7.

In front two *posterior nares*, two *Eustachian tubes*, and *isthmus of the fauces*.

Below, the tops of the *œsophagus* and *larynx*.

Vessels.—Pharyngeal and thyroidal arteries.

Nerves.—Ninth, tenth and sympathetic.

ÆSOPHAGUS.

The œsophagus is a long, narrow muscular canal beginning at the pharynx, passes through the thorax, deviating to the left, channels the lungs, passes through a special opening in the diaphragm, and ends in the *cardiac* extremity of the stomach.

Coats.

Muscular.—Superficial, longitudinal and deep circular fibres, the upper half are striped, the remainder unstriped.

Mucous.—Has flattened epithelium and is thrown into numerous and marked folds.

Blood Supply.—External carotid, bronchial and œsophageal.

Nerve Supply.—Tenth.

ABDOMINAL CAVITY.

The abdomen is that part of the great cavity of the trunk behind the diaphragm. It is bounded above by the lumbar and sacral vertebræ, laterally and below by the abdominal muscles, behind by the pelvic brim.

Regions.

(a) *Superior* or *sub-lumbar*, under the psoas muscles and lumbar vertebræ.

(b) *Inferior*, from xiphoid cartilage to pubes, and includes recti muscles laterally. It is divided from before, backward, into the *supra-sternal*, *umbilical* and *pre-pubic* regions.

(c) *Inguinal*, about inguinal canals.

(d) *Lateral*, from ribs to pelvis, and superior border of small oblique to outer border of rectus. The *hypochondrium* is that part behind the costal free borders. The *flank* is that part covered by the internal oblique.

(e) *Diaphragmatic* is the space included in the concavity of the diaphragm.

(f) *Pelvic*, bounded *above* by sacrum, below by pubes, ischium, and obturator internus, laterally by the os innominati and sacro-schiatic ligaments. *Behind* are placed the rectum and genito-urinary organs.

STOMACH.

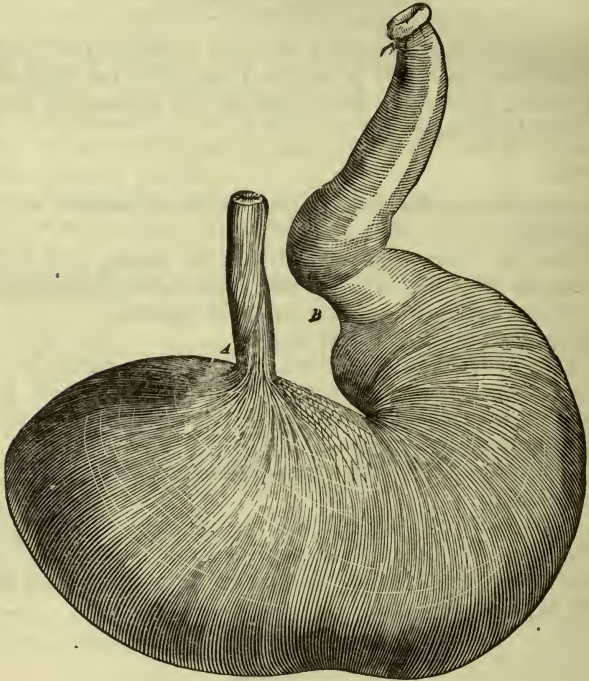
The stomach is a muscular organ, situated in the diaphragmatic region, in whose cavity the principal acts of digestion take place. Its *capacity* is 3 to 3½ gallons, its *weight* 3 or 4 pounds. In form it is elongated, often constricted in the middle, and presents an *anterior* and *posterior face*, a *great curvature* below, to which is attached the great omentum, a *lesser curvature*, to which is attached the gastro-hepatic omentum; a left dilatation, the *jun-*

cus, a *cardiac extremity* continuous with the gullet, and a *pyloric extremity*, forming a species of valve opening into the duodenum.

Coats.

Serous.—Most external, from the peritoneum, and completely covering the viscus, except at the greater and lesser curvatures.

FIG. 19.



STOMACH OF THE HORSE.

A, Cardiac extremity of the œsophagus; B, Pyloric ring.

It has three folds derived from it, the *cardiac* from the cardia to the diaphragm, the *gastro-hepatic* from lesser curvature to transverse fissure of liver, and the *great* or *gastro-colic omentum* from great curvature to sub-lumbar region, end of large and beginning of small colon.

Muscular.—Three layers, *external*, over right sac and also left one; *middle*, circular over whole organ, aggregated at the pyloric orifice to form the pyloric valve; *internal*, looped around left sac.

Mucous.—This is thrown into folds in the right, but not in the left sac. It has a muscular layer, the *muscularis mucosæ*, and is covered with flattened epithelium in the left and cylindrical in the right sac.

Glands.

Infrequent on left side and like those of œsophagus. Common on right sac, and are of two varieties.

(a) *Peptic*, with a narrow neck opening into two or three cul-de-sacs, lined with rounded epithelium at the periphery and small cells next to the lumen. The neck is lined with cylindrical cells.

(b) *Mucous*, similar in structure, but the whole gland is lined with cylindrical epithelium.

Blood Supply.—Gastric, splenic, pyloric, œsophageal, right and left gastro-epiploic vessels.

Nerves.—Tenth and solar plexus.

INTESTINES.

The terminal portion of the alimentary system, beginning at the pylorus, ending at the anus by the rectum. It is a narrowed tube, twisted and curved upon itself, and divided into small and large divisions. Their entire length is about 98 feet—72 feet for the small and 26 for the large.

SMALL INTESTINES.

These begin at the pylorus, form a loop over the base of the cæcum, turn transversely to the left, then form numerous folds, being suspended by a process of peritoneum, the *mesentery*, finally terminating in the cæcum at the right hypochondrium.

Length, 24 yards; diameter, 1-1 $\frac{3}{4}$ inches.

Divisions.—*Duodenum*, the first curved portion.

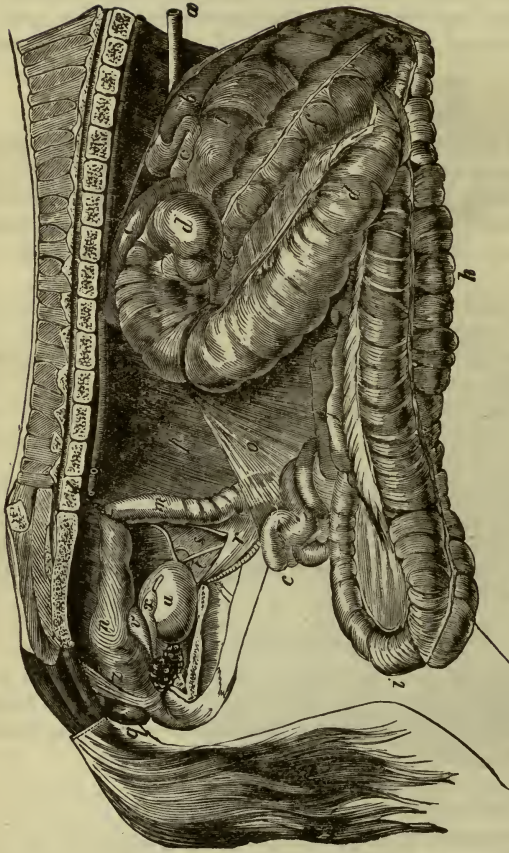
Jejunum (empty), the greater part.

Ileum (twisted), the terminal portion.

Coats, from without inward, are—

Serous, from peritoneum, covering all the small intestine completely, except a portion of the duodenum.

FIG. 20.



GENERAL VIEW OF THE INTESTINES OF THE HORSE; SEEN FROM THE RIGHT SIDE, WITH THE PELVIC CURVATURE AND A PORTION OF THE SMALL INTESTINE CARRIED BEYOND THE ABDOMINAL CAVITY.

a, Œsophagus; *b*, Right sac of the stomach; *c*, Small intestine, showing its origin, or duodenal portion encircling the base of the cæcum; *d*, Cæcum; *e*, Origin of the large colon; *f*, First portion of the large colon; *g*, Suprasternal flexure; *h*, Second portion of the large colon; *i*, Pelvic flexure; *j*, Third portion of the large colon; *k*, Diaphragmatic flexure; *l*, Fourth portion of the large colon; *m*, Termination of the free colon; *n*, Rectum; *o*, Mesentery proper; *p*, Colic mesentery (meso-colon); *q*, Neck of the vaginal canal; *r*, Spermatic vessels; *s*, Deferent canal; *t*, Bladder; *u*, Vesiculae seminales; *v*, Pelvic enlargement of the deferent canal; *y*, Prostate; *z*, Suspensory ligament of the penis.

Mucous.—Soft and covered with columnar epithelium.

Blood Supply.—Great mesenteric and cœliac axis.

Nerves.—From solar plexus.

LARGE INTESTINE.

Twenty-six feet in length, and consists of the *cæcum*, *large colon*, small or *floating colon*, and *rectum*.

CÆCUM.

An elongated sac, three feet in length, with a capacity of $7\frac{1}{2}$ gallons, lying in the right hypochondrium. Its superior extremity (or crook) lies under the right kidney, and shows the two openings of the ileum and beginning of the colon; it is encircled by the curve of the duodenum.

Coats.

Serous, from peritoneum.

Muscular, four external longitudinal layers, which are inserted into the circular, forming a number of transverse folds.

Mucous, thicker than small intestine; it contains no *Brünnerian* glands or patches of Peyer.

Muscular, of non-striated fibres, an external longitudinal, and internal circular coat.

Points of Interest.

Valvulæ conniventes, folds of mucous membrane with fibrous tissue between, in duodenal portion, to retard passage of food.

Openings of bile and pancreatic ducts, or a common orifice, five to eight inches from pylorus, and a separate one for the accessory pancreatic duct.

Villi, elevations which allow of passage of food principles in absorption, connected with lacteals.

Brünner's glands, found in the duodenum; are racemose in character, with a short duct. They secrete intestinal juice.

Crypts of Lieberkühn, over all parts of membrane; are simply depressions lined with columnar epithelium.

Solitary glands are lymphoid tissue with no duct, and are more abundant in the large intestine.

Glands of Peyer are groups of the preceding, found for the most part in the ileum; they are one hundred in number; the largest are $1\frac{1}{2}$ inch square, oval in shape, and situated opposite the mesenteric attachment.

Blood Supply.—Cæcal vessels.

Nerves.—Sympathetic.

LARGE COLON.

About twelve feet long; it begins at the cæcum, passes forward, then bends backward and to the left, forming the *supra-sternal curvature*, lying above the sternum, then backward, turns again, forming *pelvic flexure*; runs forward to the *diaphragm*, forming a flexure of the same name, then passes back with first portion, terminating in the small colon, after diminishing in calibre.

Coats.

Serous does not completely cover it.

Muscular and *mucous* same as *cæcum*.

Blood Supply.—Colic vessels.

Nerves.—Sympathetic.

SMALL COLON.

About ten feet long ending in the rectum. Has two longitudinal bands of fibres, and is lodged in the left flank.

Coats.

Same as preceding.

Interior shows folds like large colon which mould fæces.

Vessels, small and great mesenteric.

RECTUM.

About two feet long, from the pelvic inlet to its outlet, ending in the *anus*.

It is very dilatable; has no ridges, and is in relation to the sacrum above and the genito-urinary organs below. The suspensory ligaments of the penis form a ring around its posterior portion.

Coats.

Serous is incomplete behind.

The other coats are like those of colon.

ANUS.

The posterior opening of the alimentary canal; is situated under the base of the tail. It receives an aggregation of the circular fibres, which form the *internal sphincter*.

External Sphincter arises from the base of the tail, includes anus, and ends in perineal muscles.

Action, by constant tension, keeping anus closed.

Retractor Ani arises from the sacro-ischiatic ligament and is inserted into sides of rectum.

Action, pulls rectum forward after defecation.

LIVER.

The liver is situated in the abdomen, in the right diaphragmatic region. Its weight is eleven pounds. It has anterior and posterior flattened surfaces; thick at its centre, thin on its edges.

Lobes.

Left (largest), *right*, *Spigelian* and *middle*.

Fissures.

(1) A deep one for the posterior cava; (2) another in the centre of its posterior surface for the portal vein and vessels; (3) one for the œsophagus; (4) and one dividing the right and left lobes.

Ligaments.

(a) *Anterior* or *coronary*, from fissure for cava to phrenic centre.

(b) *Of left lobe*, from left lobe to side of œsophageal orifice.

(c) *Of right lobe*, from lumbar wall to right lobe.

(d) *Broad* or *suspensory*, from middle lobe to upper part of inferior abdominal wall.

(e) Round, from umbilicus to middle lobe. It is a fibrous cord, formed by the obliterated umbilical vein.

Structure.

Serous coat externally, covering it completely, except at the anterior and posterior fissures and forming ligaments.

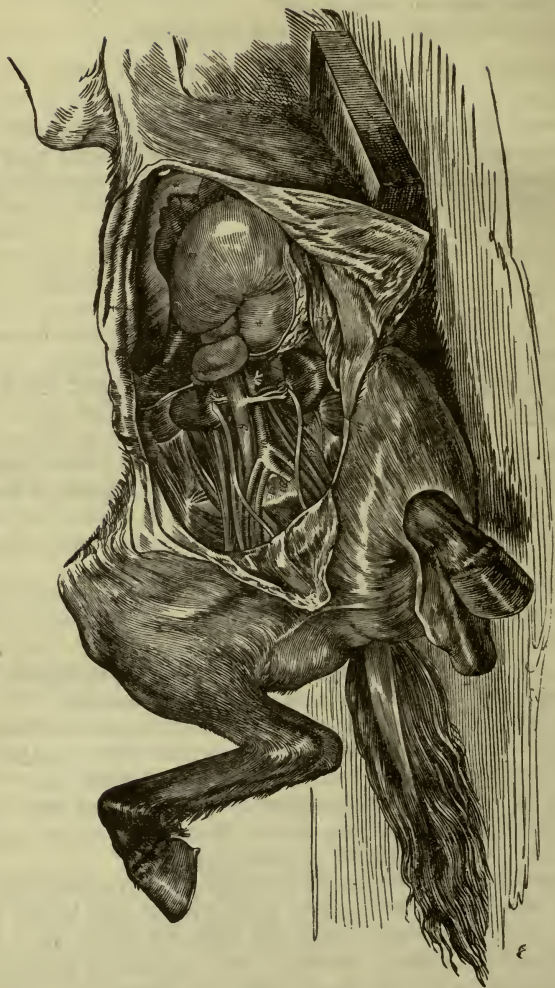
Fibrous (Glisson's capsule), enters posterior fissure and follows vessels, after forming an outer envelope for the whole organ.

Parenchyma or essential secreting portion, consists of:

Lobules ($\frac{1}{20}$ to $\frac{1}{10}$ inch in diameter), which comprise *liver cells*, polygonal in shape, $\frac{1}{500}$ to $\frac{1}{200}$ inch in diameter, with one or two nuclei. They lie in a network of small vessels.

Hepatic ducts begin between the liver cells, enter the peri-lobular connective tissue, unite with others getting constantly larger, and finally, by several branches from the different lobes, form the *ductus choledochus* or great bile-duct. This ascends in the *gastro-hepatic omentum* to the duodenum, which it penetrates six inches from the pylorus, surrounded by a circular fold of mucous mem-

FIG. 21.



THE ABDOMINAL CAVITY, WITH THE LIVER AND OTHER ORGANS.

1, Right lobe of the liver; 2, Middle lobe; 3, Right extremity, or ventriculus of stomach; 4, Right extremity; Left abdominal wall

brane, the *ampulla of Vater*, in common with the *pancreatic* duct. The horse *has no gall bladder*.

Course of blood through the liver.

The portal vein enters the posterior fissure, forming *inter-lobular* veins; these form a network of veins between the cells, then uniting, form the *intra-lobular* or central vein.

The intra-lobular unite in the *sub-lobular* vessels, which are quite numerous, ending as *hepatic* veins by opening into the posterior cava.

Lymphatics.

Follow the vessels forming lymph spaces which, uniting, end in the *receptaculum*.

Arteries.

Hepatic, from cœliac axis, ending in the lobular centres.

Nerves.—Solar plexus, tenth and phrenic.

PANCREAS.

This viscus resembles the salivary gland in structure, is situated in the sub-lumbar region, under the *aorta* and *cava*, and behind the stomach and liver.

Form, elongated, triangular or curved on itself.

Weight, seventeen ounces.

It has a superior and inferior *surface*, an *anterior* and *posterior border*, a *right extremity* or *head*, and a *left* or *tail*, toward the spleen. The posterior border is notched for the portal vein.

Structure.

Like the salivary glands, though its epithelium is rounded, not columnar.

Ducts.

Principal (duct of Wirsung) runs along nearer anterior border from tail to head, receives a number of branches, and opens into duodenum in common with the bile duct. The accessory duct opens alone after receiving several branches.

Vessels.—Hepatic and great mesenteric.

Nerves.—Solar plexus.

SPLEEN.

This is not properly an annexed gland of digestion, but from its position it is discussed in this section. It has no duct and is therefore, a *ductless gland*.

It is situated in the diaphragmatic and left hypochondriac regions, and suspended from the sub-lumbar. Its shape is falciform, and directed downward and backward.

Weight, thirty-two ounces.

It has an *external* convex face, an *internal* concave, a convex *posterior* and concave and sharp *anterior border*, a base or *superior extremity*, and a *point* or *inferior extremity*.

Ligaments.

Suspensory, from sub-lumbar region and left kidney to base.

Gastro-splenic omentum, a process of peritoneum enveloping whole organ except at anterior fissure.

Structure.

Serous coat, from peritoneum, most external.

Fibrous coat, thick and strong, sending prolongations or trabeculæ into the interior which support the splenic pulp.

Splenic pulp, reddish material which fills the interior of the organ; composed of pigment, broken down corpuscles, etc.

Malpighian corpuscles, small rounded bodies of lymphoid structure enveloped by the outer tunic of the small arteries. They are large in well fed, and small in starved animals.

Vessels.—Splenic.

Nerves.—Solar plexus.

THE PERITONEUM.

The peritoneum is a serous membrane with a *visceral* and *parietal* layer, and enveloping nearly all the organs of the abdominal cavity more or less completely.

Beginning at liver it forms the ligaments already described, a fold, the *gastro-hepatic omentum*, which separates, to enclose the stomach, and sending reflections to the duodenum and cæcum on the right, and the spleen on the left, forming the *gastro-splenic omentum*. Its median portion descends in front of the intestines, having a large amount of fat developed in its structure, the *great*

omentum. This is confounded laterally with the mesenteries of the colon.

The great omentum communicates with the general peritoneal cavity behind the stomach by an opening, the *foramen of Winslow*, bounded by the *vena portæ, cava, pancreas* and lesser curvature of the stomach.

It is then reflected over the small and large intestines, forming their *mesenteries*, the ligaments of the bladder, broad ligaments of the uterus, and then from the rectum and front of the bladder is reflected to the superior and inferior abdominal wall, forming the parietal layers. The inferior abdominal portion continues forward and forms the suspensory ligament of the liver. The superior abdominal portion passes beneath the kidney, giving it support, and after forming the mesenteries is continued to the diaphragm, as the upper layer of the suspensory and gastro-hepatic ligaments.

Structure.

A basement membrane covered with flattened polygonal endothelial cells.

RESPIRATORY SYSTEM.

In this system, the great process of oxygenation of the blood takes place, as well as the throwing off of excrementitious substances, viz., carbonic acid gas, solids, etc.

The air passages are from above, downward, the *nasal fossæ, larynx, trachea, bronchi* and *lungs*.

For a description of *nasal fossæ*, see special senses.

LARYNX.

The larynx is a cartilaginous box, being the organ of voice. Its anterior opening is at the bottom of the pharynx, its posterior continuous with the trachea.

Structure.

Five cartilages, twelve muscles, and a mucous membrane.

Cartilages.

Thyroid, cricoid and *epiglottis*, single ones and one pair, the arytenoids.

Thyroid.

(Shield-like.) Composed of two portions united in front and above to form its *body*; to its superior part the epiglottis is attached. The lateral portions have an *external surface*, covered by muscles; an *internal*, covered by mucous membrane; an *anterior* or superior *border*, to which the great cornua of the hyoid and the thyrohyoid membrane is attached; a *posterior* border, showing in front the attachment of the crico-thyroid membrane, and behind an articulating facet with the cricoid.

Cricoid.

(Like a ring.) Shaped like a seal ring with the seal upward, and shows an *external face*, smooth, and on its flattened portion spaces for the origin of the *posterior crico-arytenoids*, outside these the articular facets for the thyroid; an internal face, covered by mucous membrane; a *superior border*, with facets for the *arytenoids* and attachment of crico-thyroid membrane; an *inferior border*, responding to the trachea.

Epiglottis.

A soft, flexible lid that covers the entrance to the larynx. It has an *anterior face*, which gives attachment to the hyo-epiglottideus; a *posterior*, covered by mucous membrane; a *circumference* and base attached to the thyroid.

Arytenoids (two).

(Like a pitcher.) Are situated above the cricoid and near the top of the larynx. They are irregularly quadrilateral and show an *internal face* lined with mucous membrane; an *external*, giving attachment to *arytenoid*, *thyro-arytenoid* and *lateral crico-arytenoid* muscles; a *superior border*, united with the opposite; an *inferior*, giving attachment to the vocal cord; an *anterior*, joining with its fellow and giving the pitcher appearance; a *posterior*, which articulates with cricoid.

Articulations of Cartilages.

Thyroid, with *cornua* of *hyoid*, by *thyro-hyoid ligament* and thyro-hyoid membrane.

Thyroid with cricoid.

Capsular ligaments for facets and crico-thyroid membrane.

Arytenoids with cricoid.

By capsular ligaments for facets.

Arytenoids with thyroid.

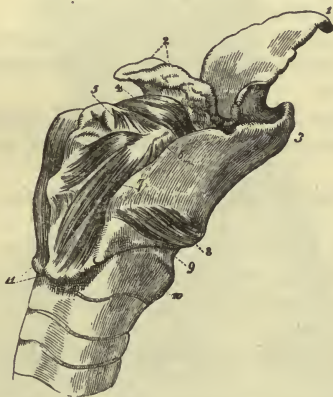
By *vocal cords*, a pair of fibrous bands which enclose a triangular

space, the *glottis*, attached in front to thyroid, behind to arytenoids.

Epiglottis with *thyroid*, by simple ligamentous bands.

Epiglottis with *arytenoids*, by some bands, sometimes called the superior or false vocal cords; they contain some cartilaginous bodies (of Wrisberg).

FIG. 22.



POSTERO-LATERAL VIEW OF THE LARYNX.

- 1, Epiglottis; 2, Arytenoid cartilages; 3, Thyroid cartilage; 4, Arytenoideus muscle; 5, Crico-arytenoideus lateralis; 6, Thyro-arytenoideus; 7, Crico-arytenoideus posterior; 8, Crico-thyroideus; 9, Ligament between the cricoid cartilage and first ring of trachea; 10, 11, Infero-posterior extremities of crico-thyroid cartilages.

Muscles.

Thyro-hyoid.

Origin.—Outer surface of thyroid cartilage.

Insertion.—Whole hyoid cornua.

Action.—Carries larynx forward and upward.

Hyo-epiglottideus.

Origin.—Body of hyoid.

Insertion.—Superior face of epiglottis.

Action.—Restores epiglottis to erect position.

Crico-thyroid.

Origin.—External face of cricoid.

Insertion.—Posterior border of thyroid.

Action.—Brings two cartilages together.

Posterior crico-arytenoid.

Origin.—Posterior flattened part of cricoid.

Insertion.—Posterior tubercle of arytenoid.

Action.—Rotates the arytenoids outward, thus separating vocal cords.

Lateral crico-arytenoid.

Origin.—Anterior border of side of cricoid.

Insertion.—Outside the preceding on tubercle of arytenoid.

Action.—Antagonist to preceding, approximating cords.

Thyro-arytenoid.

Origin.—By two fasciculi, near angle of thyroid.

Insertion.—Lies on vocal cord, to external crest of arytenoid and muscles.

Action.—Constrictor and regulator of tension of larynx.

Arytenoid.

Origin.—From external face of one cartilage.

Insertion.—Into the analogous point of the other.

Action.—Brings vocal cords in apposition.

Mucous Membrane.

Covered by flattened epithelium on cords and glottis; elsewhere is ciliated.

The glands are racemose and numerous posteriorly.

Vessels.

Laryngeal arteries.

Nerves.

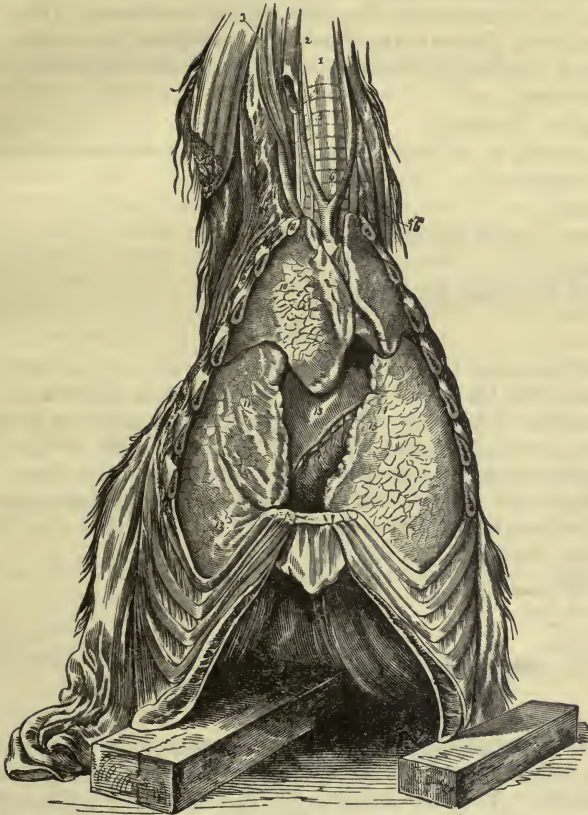
Superior laryngeal supplies mucous membrane with sensation and crico-thyroid muscle. The inferior laryngeal supplies the remainder.

In the *mule* and *ass* there exists a deep depression, the *sub-epiglottic sinus*, capable of great vibration.

TRACHEA.

This is a long tube composed of about fifty cartilaginous rings, beginning at the *cricoid* and ending at the right side of the posterior aorta opposite the left auricle of the heart. It lies under the œsophagus and between the two carotids in the neck. At its end it bifurcates into the two bronchi.

FIG. 23.



THE RESPIRATORY ORGANS; INFERIOR, OR FRONT VIEW.

- 1, Trachea; 2, Jugular vein; 3, Great rectus anticus muscle; 4, Carotid artery; 5, Longus colli muscle; 6, Origin of the common carotids; 7, Vertebral artery; 8, Section of first rib; 9, Cephalic trunk of right axillary artery; 10, Anterior lobe of right lung; 11, Middle, or supplementary lobe of ditto; 12, Posterior portion or lobe of ditto; 13, Heart; 14, Cardiac artery; 15, Ventricular branch of cardiac vein; 16, Oesophagus.

Structure.

The *cartilaginous rings* are incomplete above, where the space is filled in by transverse muscular and fibrous bands. The rings are united by fibrous tissue which fills the intervening space. The last ring is often divided into two segments for the bronchi by a median spur.

Mucous Membrane.

Is covered by ciliated epithelium, and its glands are very numerous posteriorly.

Vessels.

From carotid and axillary.

Nerves.

From recurrent laryngeal.

BRONCHI.

The *right* and *left primary bronchi* are the continuation of the trachea, enter the *root* of each lung with the bronchial artery, veins and nerves. They then subdivide into a large number of branches which go on subdividing further. They are round, composed of cartilaginous circles joined to each other by muscular fibre. The cartilages and muscles disappear when the tubes become small. The mucous membrane is much more sensitive than that of the trachea, otherwise like it.

Vessels.

Bronchial.

Nerves.

From sympathetic and tenth.

THE LUNGS

Are the essential organs of respiration, situated in the thorax on either side of the heart and enveloped by a serous membrane—the pleuræ. They are described as two lungs, the right and left. Each lung is cone-shaped and has an *external face* lying against the ribs; an *internal*, forming the side of the mediastinum, which shows notches for the œsophagus and aorta; the *root* of the lung, where the bronchi, vessels and nerves enter its structure, and the attachment of the *ligamentum latum pulmonis*, a process of the pleura passing backward to the diaphragm; a *base*, concave and in contact with the diaphragm; it shows a small lobule on the right

side which represents the middle lobe of man, and also a notch for the *posterior cava*. The *apex* or *summit* lies behind the first rib and is somewhat detached, forming the anterior lobe. Thus the right lung has *three lobes*, an *anterior*, *middle* and *posterior*, the left two, an anterior and posterior. The *superior border* lies near the vertebræ; the *inferior* is notched deeply for the heart.

Structure.

Serous from *pleura*. (See below.)

Parenchyma.—This is rose-colored, soft, strong and elastic. It is divided into *lobules*, each of which receives a small bronchus, and is further subdivided into *alveoli*, spaces with which a number of smaller spaces communicate, the *air cells*. The walls of the *air cells* have a thin basement membrane, covered with flattened epithelium $\frac{1}{1600}$ to $\frac{1}{2200}$ of an inch in diameter. Between the air cells is yellow elastic connective tissue.

Vessels.

The vessels are derived from the pulmonary and bronchial arteries and the pulmonary vein. They form a plexus under the walls of the air cells, which allows the passage of oxygen.

Nerves.

Tenth and sympathetic.

THE PLEURÆ.

The pleuræ are two shut serous sacs, which form the borders of the mediastinæ, or space in centre of the chest.

Structure.

Basement membrane covered by flattened epithelium and lubricated by a serous fluid.

Attachment.

It is attached to the root of the lung, there giving off the *ligamentum latum*, then envelops the whole lung, forming the *visceral* layer. It then passes to the chest wall, forming its *costal* portion, to the *diaphragm*, and at its middle is in contact with that of the opposite side, forming its mediastinal portion; encloses the heart, and divides the chest into the *anterior* and *posterior mediastinæ*.

Nerves.

Diaphragmatic, intercostal, tenth and sympathetic.

Vessels.

Bronchial and intercostal,

THORAX.

This cavity is bounded *in front* by the *first ribs* and *longus colli*, and has passing through this opening *lymphatic glands, trachea, œsophagus, axillary and carotid vessels, anterior cava, tenth, sympathetic, inferior laryngeal and phrenic nerves*; *behind*, by the *diaphragm*; *above*, the *vertebræ, ribs, longus colli, thoracic duct, aorta, vena azygos and sympathetic*; *below*, by *sternum, costal cartilages and the triangularis sterni*; *laterally*, by *ribs and deep intercostal muscles*.

The *contents* are heart and great vessels, lungs, œsophagus, trachea, nerves, thoracic duct, etc.

THE MEDIASTINÆ.

The portion of the thorax in front of the heart is called the *anterior mediastinum*, that behind, the *posterior*. The former contains the trachea, œsophagus, anterior aorta and divisions, anterior cava, thoracic duct, tenth, cardiac, recurrent and phrenic nerves, and thymus gland in young animal.

The latter contains the posterior aorta, vena azygos, thoracic duct, œsophagus, tenth and left phrenic nerves, and ligamentum latum.

DUCTLESS GLANDS.

Spleen, see *Abdomen*; *supra-renal bodies*, see *Kidney*; *pituitary gland*, see *Brain*.

THYROID GLAND.

The thyroid is a gland lying in the neck under the first two tracheal rings, composed of *two lateral lobes*, a right and left, united by a median portion, the *isthmus*.

Structure.

Fibrous coat, which covers it, and sends in prolongations, as in the spleen.

Parenchyma.—This is divided into lobules, which contain round *vesicles*, lined with polygonal cells, and containing albuminous matter.

Vessels.

Thyro-laryngeal.

Nerves.

First and second cervical and sympathetic.

THYMUS GLAND.

This is a gland lying at the back part of the neck, under the trachea, and partly within the thorax. It has two lateral lobes in contact with each other, and is only found in the fœtus and young animal.

Structure.

Of lobules, which contain spaces filled with granular matter. The *lymphatics* are well marked.

URINARY ORGANS.

They comprise the *kidneys*, *ureters*, *bladder* and *urethra* (in the male this is also genital).

THE KIDNEYS.

The essential organs of the urinary system are two in number, situated in the abdomen, to the right and left of the sub-lumbar region, against the *psoas* muscles. The peritoneum passes under them. The right is heart-shaped and more anterior than the left, which is bean-shaped.

Weight.—*Right*, twenty-seven ounces; *left*, twenty-five.

Each kidney has a *superior* and *inferior* flattened surface, an *external* convex border and an *internal* concave one, which is deeply notched, and called the *hilum*. The *hilum* lodges the vessels, nerves and beginning of the ureter.

Interior.

A section shows that at the *hilum* is found a cavity, called the *pelvis*, the beginning of the ureter, elongated from before backward. Opposite this, in the proper tissue of the kidney, is seen a ridge, on which empty the uriniferous tubes. The *pelvis* is lined with mucous membrane.

Structure.

Fibrous coat or *capsule*, most external, and sending prolongations into its interior.

Parenchyma.—Divided into an *external* or *cortical* and *internal* or *medullary* layer. The *cortical* layer is darker, and contains small, round bodies, the *Malpighian corpuscles*. The *medullary* is lighter, and contains the uriniferous tubules. There is also some connective tissue supporting the tubes, vessels, etc.

FIG. 24.

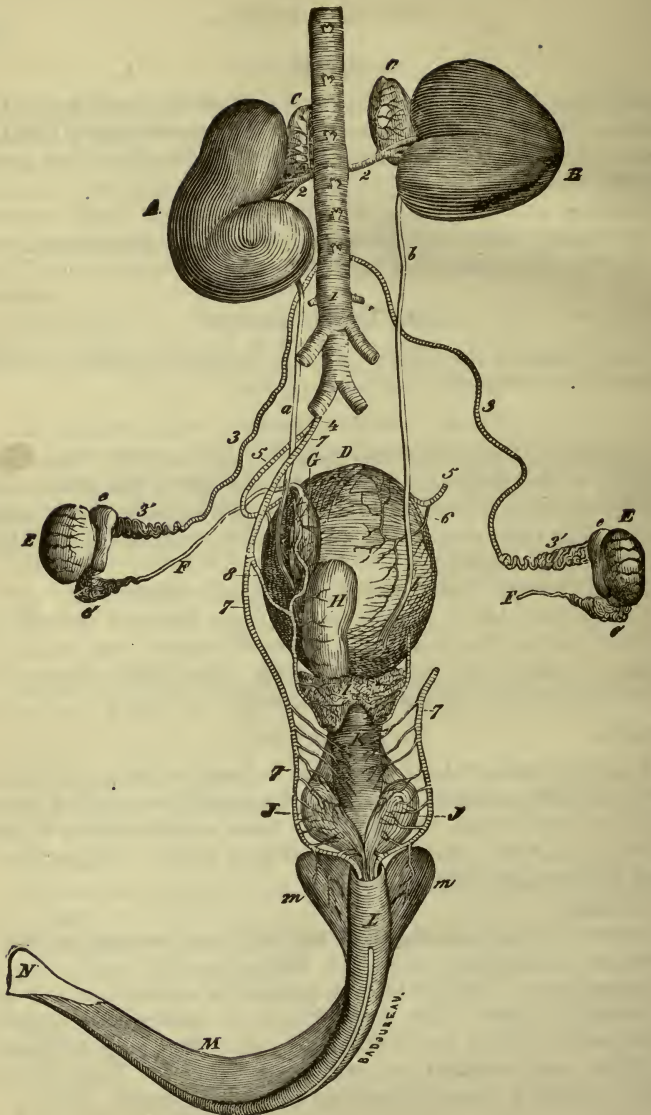


FIG. 24.—SUPERIOR AND GENERAL VIEW OF THE GENITO-URINARY APPARATUS IN THE MALE, WITH THE ARTERIES.

A, Left kidney; B, Right kidney; a, b, Ureters; c, c, Supra-renal capsules; D, Bladder; E, E, Testicles; e, Head of the epididymis; e', Tail of the epididymis; F, Deferent canal; G, Pelvic dilatation of the deferent canal; H, Left vesicula seminales; the right has been removed, along with the deferent canal of the same side to show the insertion of the ureters into the bladder; I, Prostate; J, Cowper's glands; K, Membranous, or intra-pelvic portion of the urethral canal; L, Its bulbous portion; M, Cavernous body of the penis; m, m, Its roots; N, Head of the penis. 1, Abdominal aorta; 2, 2, Arteries (renal) giving off the principal capsular artery; 3, Spermatic artery; 4, Common origin of the umbilical and arteries of the bulb; 5, Umbilical artery; 6, Its vesical branch; 7, Internal artery of the bulb; 8, Its vesico-prostatic branch.

Malpighian Bodies.

These are small, round vesicles found in the cortex, lined with cylindrical epithelium, and containing a tuft of blood vessels (the glomerulus), also covered by epithelium. There are two openings,—one, the beginning of the uriniferous tubule, the other opposite it, showing the entrance of a small artery and the emergence of a vein, which afterward forms a plexus around the tube.

Uriniferous Tubes.

These are small canals running through the medullary structure of the viscus, beginning at the Malpighian corpuscle, and ending on the ridge of the pelvis. They are first single, but soon subdivide into *straight tubules*, then descend into the medulla as the *loop of Henle*, in a U shape, turn on themselves and run back to the cortex. Then dilating, have several bends, pass down again through the medulla, narrow and empty on the ridge of the pelvis, as the *convoluted tube*.

Structure.

Amorphous basement membrane covered with flattened, polygonal or polyhedral epithelium in different localities.

Vessels.

The *renal* artery divides into several which give off branches to cortex and medulla, glomeruli and tubes.

The branches to the medulla descend between the tubes.

The *veins* of the *capsule* are collected in a stellate manner, the *stars* of *Verheyen*. They also form arches at the junction of the cortex and medulla, and finally uniting form the renal vein.

The *nerves* are from the solar plexus.

SUPRA-RENAL CAPSULES.

The supra-renal capsules are two small elongated bodies lying to the under and inner side of the pelvis of the kidney.

Form.—Elongated and flattened, two inches long; right larger.

Structure.

External fibrous coat, which projects inward, forming spaces.

Parenchyma.

(a) *Cortical* substance. Dark-brown in color, and consists of granular nucleated cells.

(b) *Medullary* substance. Yellow and soft, of a delicate reticular structure filled with cells and nerve structures.

Vessels.—Mesenterics and renal.

Nerves.—In large numbers from solar plexus.

THE URETERS.

The ureters are two in number, beginning at the pelvis of the kidney, run back and downward to the superior and posterior portion of the bladder, where they penetrate its muscular coat for an inch before opening into its interior. It is the size of a goose quill.

Structure.

External, fibrous layer; *middle*, of external, circular and internal longitudinal muscular fibre, and an *internal*, mucous, ridged in its long axis, and covered with stratified pavement epithelium.

THE BLADDER.

This is a muscular bag in which the urine is accumulated before being discharged from the body. It occupies the inferior part of the pelvic cavity, and has three openings, the orifices of the two ureters and beginning of the urethra.

Weight, sixteen ounces.

Parts.

Near the urethral opening, the *neck*; between the urethral opening and the openings of the two ureters a triangular space, the *trigone*. It rests by its inferior surface, or *base*, on the pubischial symphysis. Its anterior extremity or *fundus* is in relation to the large colon. Above, it is in relation with the uterus and vagina in the *female*, the seminal vesicles and rectum in the *male*.

Coats.

Peritoneal or *serous* (external), covers only its anterior half; passes back farther superiorly. Forms three ligaments, one anterior, two lateral.

Muscular, of unstriped tissue of longitudinal, oblique and circular fibres. The latter very marked at the neck, the sphincter.

Mucous.—Pale, covered with stratified and flattened epithelium, and contains simple glands.

Vessels.—Internal pudic and umbilical.

Nerves.—Pelvic plexus and last two sacral.

For *urethra* in *male*, see *Penis*; in *female*, see *External Genitals*.

MALE GENITAL ORGANS.**THE TESTICLES.**

The testicles are two oval tubular glands lying on either side of the penis and enveloped in a double bag of the abdominal skin and fascia, the scrotum.

Coverings.

1. *Scrotum*, of skin, with many sebaceous glands.

2. *Dartos*, two pouches of contractile tissue, in contact in the median line, the *septum scroti*.

3. *Cremaster*, from the ilio-lumbar aponeurosis to the outer side of the next covering.

4. *Fibrous tunic* (infundibuliform fascia), covers the whole testis, and is a process of the transversalis fascia.

5. *Tunica vaginalis* is a short serous sac, enveloping each testicle, derived from the peritoneum. It forms a covering for the spermatic cord, and below is divided into a *visceral* layer, covering the testicle and epididymis, and a *parietal* lying inside the fibrous covering.

Its cavity contains some fluid, serous in character.

Parenchyma.—This consists of the testis proper and a number of seminal tubes, which together form a body lying on top of the testis—the epididymis.

Fibrous membrane (or *tunica albuginea*) is a strong fibrous envelope, which sends in prolongations or trabeculæ to its interior, dividing it into lobules. At its upper border and in front

it is thickened, and called the *corpus highmorianum* or *mediastinum testis*: through this the seminal tubules pass from the interior.

The *tubules* are divided into groups or *lobules*, about 200 or 300 in number, each lobule being found between prolongations of the fibrous tunic, and about one or two yards in length.

The *tubules* are about $\frac{1}{200}$ of an inch in diameter; have a basement membrane, covered by several layers of epithelium, which fill the tube, spermatozoids being found in the lumen.

The *lobuli testis* consists simply of these tubes much convoluted; passing through the mediastinum, they unite in about twenty tubes—the *vasa recta*; forming a network, the *rete testis*, and are continued into the epididymis and the *vasa efferentia*.

THE EPIDIDYMIS.

The epididymis is an elongated body lying on top of the testicle, and composed of the seminal duct, much convoluted, the *vasa efferentia* uniting to form it at its anterior portion—the *head*, or *globus major*. The posterior extremity, or *tail*, is called the *globus minor*. Between the *globi* is the *body*. The seminal duct, or *vas deferens*, is continuous with the *globus minor*.

Structure.

Externally a circular and longitudinal muscular layer, with fibrous covering, covered by a mucous membrane lined with ciliated epithelium.

Arteries.

Spermatic, from the aorta.

Veins are markedly spread out on the cord, the *pampiniform plexus*, which finally empties into the posterior cava.

Nerves.

From sympathetic.

Descent of the Testis.

The testicle remains in the abdominal cavity, in the sub-lumbar region, till after birth, usually reaching the scrotum at the age of six months. The active part in the descent is taken by the *gubernaculum testis*, a fibrous cord continuous below with the dartos and ending above in the abdominal cavity. It pulls the testis downward, carrying the peritoneum before it, which becomes inverted over it, forming the *tunica vaginalis*. The portion at the upper

part of the scrotum becomes obliterated and cut off from the peritoneal cavity.

The *semen*, the combined secretion of the testicles and glands of the urethral canal, is a white, viscid, alkaline fluid, holding in solution the essential elements formed by the testicles—the *spermatozoa*—which are elongated bodies $\frac{1}{800}$ to $\frac{1}{1000}$ inch long, with an oval *head* and a filamentous tail.

VAS DEFERENS.

This is an elongated canal, as large as a goose quill, beginning at the epididymis and ending at the seminal reservoirs. It passes upward through the inguinal canal, backward into the pelvis, crossing the ureters, and ends by uniting with the vesicles to form the ejaculatory ducts.

Structure.

External, fibrous layer.

Middle, muscular, of two longitudinal and one circular, layer.

Internal, mucous, covered with columnar epithelium.

THE VESICULÆ SEMINALES.

These are two elongated pouches, which store up the semen for the copulative act; they lie above the bladder, receiving a peritoneal fold. They have a *body* and an *anterior* and *posterior extremity*. Their posterior extremity is tapering and unites with the *vas* to form the ejaculatory duct.

Structure.

1. *Serous* coat, incomplete.

2. *Fibrous*.

3. *Muscular*, like bladder, with also some *compressor* fibres to evacuate the pouch.

4. *Mucous membrane*, continuous with ejaculatory ducts, thrown into folds with numerous glands, which furnish a part of the seminal fluid.

THE EJACULATORY DUCTS

Are two very short canals succeeding the vesicles, and formed by their junction with the *vasa deferentia*. They pass above the prostate, finally emptying into the urethra on either side of an elevation, the *veru montanum*. In front of this is the opening which runs backward into the sac lying between the *vesicles* and inside the peritoneal pouch. The opening is the *sinus pocularis*,

and the pouch the *third* seminal vesicle (this is not present in man to nearly the same extent).

THE PROSTATE GLAND.

The prostate is situated behind the neck of the bladder, and embraces the beginning of the urethra, being divided into two lateral lobes. It contains a number of conglomerate glands, whose secretion is poured into the urethra on the sides of the *veru montanum*. It also contains fibrous structure.

THE URETHRA.

This is an elongated canal continuing through the whole penis, and beginning at the neck of the bladder as the *meatus internus*.

It first passes backward, curves around the ischial symphysis, and then downward and forward in the structure of the penis, between the two *corpora cavernosa*.

Divisions.

Prostatic region, dilated, contains *veru montanum*, *sinus pocularis*, and openings of prostatic glands.

Membranous, from prostate to beginning of the spongy tissue (*corpus spongiosum*).

Spongy or extra pelvic.

Begins near exit from pelvis, is narrowed and terminates on the *glans*, as the *urethral tube*. Just before this, it is dilated, the *fossa navicularis*. Behind the prostate are also the openings of *Cowper's glands*.

Structure.

Mucous membrane, thin and covered by columnar epithelium; in some parts flattened.

Erectile tissue.

Commences at ischial symphysis as the bulb, spreading out in front to form the *glans penis*, into which the *cavernosa* are inserted.

Its structure consists of fibrous spaces with some elastic tissue, which cause erection mechanically, by their distention with blood. (For muscles see *Perineum*.)

COWPER'S GLANDS.

These are two in number, of about the same structure as, and smaller than the prostate, situated near the outlet of the pelvis, on each side of the urethra, and throwing their secretion into it.

PENIS.

The penis is the organ of copulation, attached behind to the ischium and extending forward between the thighs, under the abdomen, where it ends in a free extremity, the *glans*, the anterior termination of the spongy body.

It consists of three portions, the two *corpora cavernosa*, between and below which is the *urethra*, enclosed in its spongy tissue. The free portion is lodged in the *sheath* or *prepuce*.

Urethra, see above.

Corpora Cavernosa.

Are divided only posteriorly where they are attached to the ischial rami, but are blended in front, ending by entering depressions in the glans. Underneath is the groove which lodges the urethra.

Structure.

An external thick *fibrous coat*, giving off a median prolongation, the *septum pectiniforme*, which separates the two portions.

The *interior* is composed of cavernous or erectile tissue like the spongiosum. At its base are found bouquet-shaped arterial tufts, called *arteriæ hellicinæ*.

The free portion of the *penis* has an enlarged *base*, and an anterior extremity, the *glans*, which is rounded and limited behind by a marked elevation, the *corona glandis*. It receives behind the insertion of the *corpus cavernosum*. Below this the *urethral tube*, encircled by the urethral fossa; under this a marked notch. The glans is covered by a dark smooth skin, with many papillæ.

Suspensory ligaments of penis (2).

Arise beneath sacrum, pass downward, encircling rectum, and inserted into the *accelerator*.

Prepuce or *sheath*.

A fold of the abdominal integument encircling the penis. It contains internally a number of sebaceous glands. It has in its structure two fibrous bands, the *suspensory ligaments* of the prepuce.

Blood Supply.—*Bulbo-urethral*, *dorsal arteries* and of *corpora cavernosa*.

Nerves.—Internal pudic and sympathetic.

THE PERINEUM.

The *perineum* is the space lying below the rectum, and on the sides of the external genitals in both sexes.

Superficial fascia.

Arises from the inner sides of thighs. *Inserted* on muscles of perineum and sphincter ani.

Deep fascia.

Arises from ischial tuberosities, rectal muscles and thighs.

Inserted, between *ischio-cavernosus* and *semi-membranosus*, into perineal muscles and fascia.

Muscles.(a) *Wilson's muscle.*

Origin.—From sides of pelvis.

Insertion.—By superior and inferior fasciculi into urethra in its membranous portion.

(b) *Accelerator urinæ.*

Origin.—From under surface of the urethra.

Inserted.—Into top of urethra often passing around it; extending from ischium to end of penis by transverse fibres.

(c) *Ischio-urethral* (compressor urethræ).

Origin.—From ischial arch.

Insertion.—Into lower face of Cowper's gland and Wilson's muscle.

(d) *Transversus perinei.*

Origin.—Ischial spine.

Insertion.—Into median perineal line.

Action of Muscles.

The first and third compress the urethra.

The second acts more especially in emptying it of urine, or semen.

The fourth dilates the urethra.

FEMALE GENITALS.

THE VULVA.

The external orifice of the female genitals is situated below the anus in the perineum. It is a slit-like opening, extending vertically, terminated above and below in the *superior* and *inferior commissures*. The sides are formed by the *labiæ* (or lips), of

skin externally, and mucous membrane internally. The different structures composing it are the *clitoris*, *urethra* and *hymen*.

The Clitoris.

This is a body two or three inches long; lies at the inferior commissure; is composed of erectile tissue, two crura, a prepuce and glans.

The Female Urethra.

Is very short, and opens by its *meatus* about three or four inches from the vulva on its inferior wall. It is guarded by a mucous valve which directs the urine backward. Its calibre is greater than in the male. Its coats are an internal *mucous* and external *muscular*, of circular fibres.

The Hymen.

Rare. A thin, fibrous structure, shutting off the vaginal from the vulvar cavities. It is perforated by several openings.

Structure of Vulva.

Mucous membrane, with many mucous and sebaceous glands.

Bulb of Vulva.—Consists of two lateral lobes of erectile tissue, communicating with the vessels of the clitoris, lying on either side of the vulva.

Muscles.

Constrictor vulvæ.

Attachments.—*Above* to sacrum and sphincter, and *below* to clitoris; *laterally* to muscles of thigh.

Action.—Constricts vulvar orifice.

Constrictor vaginæ.

Attachments.—To sides of rectum and vagina at junction with vulva.

Action.—Constricts vagina.

THE VAGINA.

The vagina is a long, membranous tube, extending from the vulva to the uterus, and serves the purposes of coition and passage of the foetus.

Relations.

Above, rectum; *below*, bladder; *laterally*, ureters and connective-tissue.

Structure.

Inner or Mucous Coat.—Pale; a basement membrane, covered

with a flattened epithelium. Is covered with an abundance of mucus, and has longitudinal folds (*rugæ*).

Outer or Muscular.—Of circular and longitudinal unstriped fibres.

Serous or Peritoneal.—Only in its anterior part.

Vessels.

Internal pudic.

Nerves.

Pelvic plexus.

THE UTERUS.

The uterus is a hollow, muscular organ, in which the ovum is received, and the foetus developed. It is situated in the abdominal cavity in the sub-lumbar region, its posterior extremity ending in the pelvic cavity.

Relations.

Above, to rectum; *below*, with bladder; *anteriorly* and *laterally* with intestinal convolutions; *behind*, with vagina.

Parts.

Behind is a constriction, the *cervix* (or neck), with a circular opening, the *os*. In front is the *fundus*, directly continuous with the *two cornua*. These have a *superior* or convex, and *posterior* or concave curvature, a *base* continuous with the uterus, and a *summit* continuous with the oviducts.

Ligaments.

Two *broad*, descending from the sub-lumbar region to the sides of the uterus and cornua and enveloping the ovaries and their ducts.

Two *rudimentary, round ligaments*, running from the sides of the uterus to the beginning of the inguinal canal.

Structure.

Serous coat, complete, from peritoneum.

Muscular coat, *longitudinal* (external) and *circular* (deep) unstriped fibres. The latter most marked about the cervix.

Some muscular fibres pass into the broad ligaments.

Mucous coat, of basement membrane covered with ciliated epithelium, except at the cervical canal, where it is columnar, and at the *os*, where it is flattened. It is thrown into folds at the cervix and is divided into two *canals*—those of the cervix and body. It is supplied with mucus by numerous simple and cylindrical glands.

Blood Supply.

Uterine and utero-ovarian vessels.

Nerves.

Mesenteric and pelvic plexuses.

THE OVIDUCTS, OR FALLOPIAN TUBES.

The *oviducts* are two tubes, lying on either side of the uterus, in the broad ligaments, which serve for the passage of the ovum from the ovary to the uterine cavity, with which they are continuous, and open into the cornua, by a narrowed orifice on a tubercle. In its middle it is narrow, and at its ovarian extremity it is dilated and divided into several narrow prolongations, the fimbriated extremity, one of these communicating with the ovary.

Structure.

Serous coat, from broad ligament.

Muscular, of circular and longitudinal fibres.

Mucous, continuous with that of the uterus, covered by ciliated epithelium and thrown into longitudinal folds.

THE OVARIES.

The ovaries are two small ovoid bodies, situated in the sublumbar region, with a deep notch or *hilus* on their upper surface which receives the oviduct. Into this the ovum is discharged. It is attached by the ovarian ligament to the uterus, and supported by the broad ligament.

Structure.

Serous coat, complete except at hilus.

Fibrous coat (or *tunica albuginea*), very strong.

Stroma, hard and grayish-red. Is divided into an external *cortical* and internal *medullary* portion.

Medulla, red and spongy, of connective tissue and vessels.

Cortex, of connective tissue, holding large numbers of *Graafian vesicles* or ovisacs which contain the ova. In the fully formed state they project on the surface and are composed of a *tunica fibrosa*, *tunica granulosa* and *discus proligerus*, a collection of cells about the ovum.

FIG. 25.—GENERATIVE ORGANS OF THE MARE, ISOLATED AND PARTLY OPENED.

- 1, 1, Ovaries; 2, 2, Fallopian tubes; 3, Pavilion of the tube, external face; 4, Ibid, inner face, showing the opening in the middle; 5, Ligament of the ovary; 6, Intact horn of the uterus; 7, A horn thrown open; 8, Body of the uterus, upper face; 9, Broad ligament; 10, Cervix, with its mucous folds; 11, *Cul-de-sac* of the vagina; 12, Interior of the vagina, with its folds of mucous membrane; 13, Urinary meatus, and its valve, 14; 15, Mucous fold, a vestige of the hymen; 16, Interior of the vulva; 17, Clitoris; 18, 18, Labia of the vulva; 19, Inferior commissure of the vulva.

Blood Supply.

Utero-ovarian.

Nerve.

Mesenteric plexus.

THE MAMMARY GLANDS.

The mammæ are two glandular bodies situated in the posterior and inferior abdominal region, in the position of the scrotum in the male. They are hemispherical in shape, terminating below in a small prominence, the *nipple* or *teat*.

Structure.

Skin, of abdominal region, thin and soft.

Fibrous coat, of elastic fibrous tissue, which sends prolongations into its interior.

Parenchyma of *vesicles* or acini, opening into lactiferous ducts. These unite and form several canals. These form two, three or four sinuses opening by several canals on the nipple. The acini are lined with polyhedral epithelium which become rounded and fatty in lactation.

Blood Supply.

External pudic.

Nerves.

First lumbar.

ORGANS OF SPECIAL SENSE.

Smell.—Located in the nasal cavities.

THE NASAL CAVITIES.

Bony walls.

Floor.

Two *superior maxillary*, two *inter-maxillary* and two *palate* bones.

Roof.

Nasal, frontal, ethmoid and sphenoid.

Sides.

Nasal, inter-maxillary, superior maxillary, palate and turbinated.

Median Septum.

Perpendicular plate of *ethmoid, vomer* and *mesial cartilage*.

Openings of Communication.

Anteriorly, two nostrils.

Posteriorly, two posterior nares, with pharynx.

Laterally, by a common opening into the middle meatus, the *superior maxillary, sphenoidal, ethmoidal* and *frontal sinuses*. The *inferior maxillary* opens alone.

Above, the openings of the cribriform plate transmitting the olfactory nerves.

Below, the incisive canal, leading to the mouth.

THE NOSTRILS,

Are the two oblong openings in the anterior and inferior portion of the nose.

Structure.

Of three cartilages, the first one prolonged from the tip of the nasal bones, two lateral cartilages meeting in the median line in an x shape and attached at the side to the inter-maxillary bones by a broad expanded portion; the lower extremity forms the curve of the nostril.

Muscles.

Already described.

Skin.

Thin and sensitive.

Mucous Membrane.

Covers the whole surface of the nasal cavities and continued into the sinuses.

Divided into two portions. The *olfactory* in the upper one-third, which is thin, with columnar and stratified epithelium, and the *cells* of *Schultze*. These are fusiform in shape, with a deep prolongation, continuous with the olfactory nerve, and a superficial near the free surface of the membrane. It is supplied by the first nerve.

The *Schneiderian* is thick, soft and spongy, with numerous

vessels and glands. The epithelium is *ciliated* and supplied by the fifth nerve and its superior maxillary branch.

Meatuses (three).

Superior, above superior turbinated.

Middle, between two turbinated.

Inferior, below inferior turbinated.

Blood Supply.

Superior coronary, external nasal, palato-labial and ophthalmic arteries.

Taste.

The mucous membrane of the tongue is the seat of this sense. The tongue and the mucous membrane have been already described. (See *Mouth*.)

Nerve Supply.

Posterior third by *ninth nerve (glosso-pharyngeal)*.

Anterior two-thirds by *chorda tympani* (from seventh).

The nerves end in the *taste (or gustative) bulbs*, which are found about the *calciform* and *jungiform* papillæ. They are fusiform in shape, the upper extremity reaching the mucous membrane. The nerve is found in the centre, and on the sides are *protective cells*, fusiform in shape, each with a special nucleus.

Auditory Apparatus.

Divided into three parts, the external, middle and internal ears, which collect, transmit and take cognizance of sound. The internal ear, the essential part of the apparatus, being enclosed in the petrous portion of the temporal bone.

EXTERNAL EAR.

This consists of the external auditory canal and the concha or widened appendage.

The Concha.

This is pyramidal in shape, its apex directed forward and upward, convex externally, concave internally. It consists of three cartilages, ten muscles, a fatty cushion and integument.

Cartilages.

(1) *Conchal*.—Of the general shape of the whole concha, and attached by the (2) *Annular* cartilage to the beginning of the external auditory meatus.

(3) *Scutiform*.—A small plate lying in front of the base of the concha and attached to it.

Muscles.

There are a few *intrinsic* muscular fibres of little importance.

Extrinsic are—

1. *Zygomatico-auricularis*.

Origin.—Zygomatic process of temporal.

Insertion.—Outer side of base of concha.

Action.—Carries ear forward.

2. *Temporo-auricularis externus*.

Origin.—Parietal ridge.

Insertion.—Conchal and scutiform cartilages.

Action.—Draws ear forward and inward.

3. *Scuto-auricularis externus*.

Origin.—Scutiform cartilage.

Insertion.—Inner side of concha.

Action.—Rotates concha.

4. *Cervico-auricularis superior*.

Origin.—From external temporo-auricular.

Insertion.—Posterior face of concha.

Action.—Draws it back.

5. *Cervico-auricularis medius*.

Origin.—Preceding and following.

Insertion.—Base of concha.

Action.—Rotates concha out and back.

6. *Deep cervico-auricularis*.

Origin.—Under and upper extremity of parotid.

Insertion.—Base of concha.

Action.—Like preceding.

7. *Parotido-auricularis*.

Origin.—Outer surface of parotid.

Insertion.—Base of and outside of concha.

Action.—Adducts ear.

8. *Temporo-auricularis internus*.

Origin.—Under superficial of same name, from intra-parietal ridge.

Insertion.—Inner side of concha.

Action.—Adductor.

9. *Scuto-auricularis internus.*

Origin.—Beneath scutiform.

Insertion.—Base of concha.

Action.—Antagonizes No. 3. Turns ear outward and backward.

10. *Mastoido-auricularis.*

Origin.—Margin of auditory meatus.

Insertion.—Into base of concha.

Action.—Constricts meatus.

Skin.—Thin, vascular, and covered with fine hairs.

EXTERNAL AUDITORY CANAL.

This is a short canal lodged in the petrous portion of the temporal bone, commencing at the external meatus and ending at the middle ear, being shut off from that cavity by the *membrana tympani*. The canal is lined with thin skin which contains a number of *ceruminous glands* which secrete *cerumen* or *wax*.

MIDDLE EAR OR TYMPANUM.

The tympanum is a cavity situated in the interior of the temporal bone at the junction of its mastoid and petrous portions, communicating with the pharynx by a canal lined with mucous membrane, the *Eustachian tube*. It has an *external* wall formed by the *membrana tympani*, an *internal*, shutting it off from the internal ear, showing two openings, the *fenestra ovalis* and *fenestra rotunda*, separated by an elevation, the *promontory*, and a *circumference*, which shows the openings of many mastoid cells. It is lined with mucous membrane continuous with that of the pharynx, and covered with pavement epithelium.

The **Membrana Tympani** shuts off the external meatus from the tympanum, is concave externally, convex internally, set strongly in a bony depression and adherent internally to the handle of the malleus. It consists of three layers, a *middle* fibrous and muscular, an *external* of skin, and an *internal* of mucous membrane.

The **Fenestra Ovalis**, lying in front of the promontory, is oval in shape, closed by the base of the stapes, and communicates with the vestibule.

The **Fenestra Rotunda** communicates with the *scala tympani* and is closed in by a membrane.

The **Mastoid Cells** are small cavities communicating with the tympanum and lined by a reduplication of its mucous membrane.

The **Ossicles** of the tympanum are four in number, the *malleus*, *incus*, *os orbiculare* and *stapes*.

The *malleus* (hammer) shows a *head* for articulation for the *incus*, a *handle* for articulation with the membrane, and a *neck* showing two processes of insertion (*processes gracilis* and *brevis*).

The *incus* (anvil) shows a *body* and *two processes*, the *superior* ending in a blunt point, the *inferior* being attached to the *orbicular bone*.

The *os orbiculare*, a small, disk-shaped bone, lies between the *incus* and *stapes*.

The *stapes* (stirrup) is shaped like a stirrup and has a head articulating with the preceding, *two branches*, united at a *base*, which fills in the fenestra ovalis. They are held together by unimportant *ligaments*.

Muscles.—(Two of importance only.)

Tensor tympani.

Origin.—From Eustachian tube.

Insertion.—Into neck of malleus.

Action.—Carries handle of malleus inward, thus making *membrana tympani* tense.

Stapedius.

Origin.—Wall of tympanum, near f. vestibuli.

Insertion.—Head of stapes.

Action.—Tensor of *membrana*.

The *Eustachian tube* is a canal of cartilaginous material running from the tympanum downward for a distance of *four inches*, to near the guttural openings of nasal cavity, where it is expanded into the *guttural pouches*. It is covered by the stylo-pharyngeus.

Function.—Maintains the equilibrium of air inside the *membrana tympani*.

The *guttural pouches* are two elongated cavities communicating with the pharynx, and lying on its sides.

They are in relation externally to the carotid and parotid glands, and have a capacity of three-fourths of a pint, though capable of much greater distention.

The mucous membrane is thick, strong and well lubricated with mucus.

Function.—Probably connected with hearing in some way, and also with phonation.

THE INTERNAL EAR.

The structures of the internal ear are contained in the petrous portion of the temporal bone forming the *bony labyrinth*, the parts themselves being called the *membranous labyrinth*.

The **Bony Labyrinth** consists of the *vestibule*, *semicircular canals* and *cochlea*.

The *vestibule* lies inside the inner wall of the tympanum, receiving the *fenestra ovalis*, the five openings of the *semicircular canals* above, the commencement of the *scala cochleæ* and the openings for the *vestibular branches* of the *eighth nerve*.

The *semicircular canals* are three in number, opening at five points. They are named the *superior*, *posterior*, and *external*.

The **Cochlea** (or snail shell) is situated outside and below the vestibule, consisting of a central stem, the *modiolus*, with a twisted partition, the *lamina spiralis*, running about it, and dividing the cochlea into two portions, that above the partition, the *scala tympani*, communicating with the tympanum by the *fenestrum rotundum*; that below, the *scala vestibuli*, entering the vestibule. The lamina does not quite reach the outer wall of the cochlea.

The **Membranous Labyrinth** consists also of the *vestibule*, *semicircular canals* and *cochlea*.

The *vestibule* consists of two thin sacs, a superior or *utricle*, communicating with the semicircular canals, and inferior or *sacculus*, in contact with the former.

The *structure* of the *vestibule* is an *external* fibrous coat and *internal* epithelial lining, with some calcareous particles (the otoliths) at the entrance of the nerves.

The **Membranous Semicircular Canals** fill the bony canals, and are of the same structure as the vestibule.

One of their extremities is dilated, the *ampulla*.

The **Membranous Cochlea**.

The *lamina spiralis* is continued by two membranes to the periphery of the cochlea, dividing it into the two already described—the *s. tympani* below and *s. vestibuli* above—and a *median* one between the two, the *auditive*, which contains the organ of Corti, a large number of small epithelial elements, resting on the *membrana basilaris*, and having above the *membrane of Corti*.

The organ of Corti is very intimately connected with the perception of sound. The *scala vestibuli* is again divided by the membrane of *Reissner* into two more canals.

The **Fluids** of the internal ear are the endolymph, limpid and watery, inside the membranous labyrinth, and the *perilymph* outside the membranous portion.

The *Nerve Supply* is from the eighth or auditory nerve, which splits up into *vestibular branches*, to the *utricle*, *sacculæ* and *ampullæ* and cochlear branches to the different *scalæ* of the cochlea.

SIGHT.

The *eyes* are two globular bodies, situated in the orbital cavities, that collect impressions of light, these impressions being carried to the brain by the optic or second pair of nerves.

THE ORBITS.

Two bony cavities, situated at the upper and anterior part of the face, containing the organs of vision. The bones entering into their formation are at its base the *zygoma*, the *zygomatic process* of the *temporal*, *malar*, *frontal* and *lachrymal*.

On the inner side are found the *sphenoid*, *palate* and *superior maxilla*. The orbit is continuous behind, with the temporal fossa. On its inner side, anteriorly, is seen the *lachrymal fossa*.

The *foramina* opening into it are the palatine, sphenopalatine, superior dental, optic, pathetic, lacerated and rotundum.

THE EYE.

The organs of vision consist of the two *eyeballs* and *appendages*.

The eyeball is spheroidal in shape, a little longer in its antero-posterior diameter, where it is continued by the cornea. It lies in the fat of the orbit, held in position by its muscles, and consists of three tunics surrounding the humors.

TUNICS.

The tunics of the eye are the (1) *sclerotic* and *cornea*, (2) *choroid* and *iris*, and (3) *retina*.

The **Sclerotic** is the white, dense, outer coat into which the muscles are inserted. The choroid lies in contact with it inter-

nally. It is continued in front as the cornea, and is pierced behind for the optic and ciliary nerves and central artery.

The **Cornea** is the anterior one-sixth of the sclera. It is shaped like a watch-glass, convex in front, and transparent. It is composed of a *middle proper* structure of connective tissue, an *anterior* layer from the conjunctiva, and a *posterior*, elastic in structure, the membrane of *Descemet*.

The **Choroid** lies between the sclera and retina, and is a thin, brownish, vascular membrane.

Its coats from without inward (Strangeways) are—

1. *Membrana fusca*, of connective tissue, vessels and nerves.
2. *Vascular layer*, containing many veins, the *venæ vorticosæ*.
3. *Tunica Ruyschiana*, of capillary vessels from ciliary arteries.

(The pigment layer of the retina was formerly included as a layer of the choroid.)

The **Ciliary Muscle** is a band of circular unstriped fibres running from the junction of the cornea and sclera to the iris. Its function is connected with accommodation.

The **Ciliary Processes** are folds of the choroid anteriorly, about sixty to eighty in number and $\frac{1}{10}$ inch in length.

The **Iris** is a circular curtain, a continuation of the choroid anteriorly, yellowish-brown in color, with a central opening, the pupil.

• *Structure.*

(1) *Anterior epithelial layer*, continuous with the posterior corneal layer; (2) *middle muscular*, of circular and radiated unstriped muscular fibres, supplied by the ciliary ganglion; (3) *posterior epithelial* or *uvea*, with numerous pigment cells.

The **Retina**, or internal tunic, is the expansion of the optic nerve ending in a number of folds anteriorly, the *zone of Zinn*. Its layers from without inward are—

1. *Pigmentary*, of hexagonal, pigment cells, formerly ascribed to choroid.

2. Layer of *rods* and *cones*.

3. *External granular layer*.

4. *Intermediate layer*.

5. *Inner granular layer*.

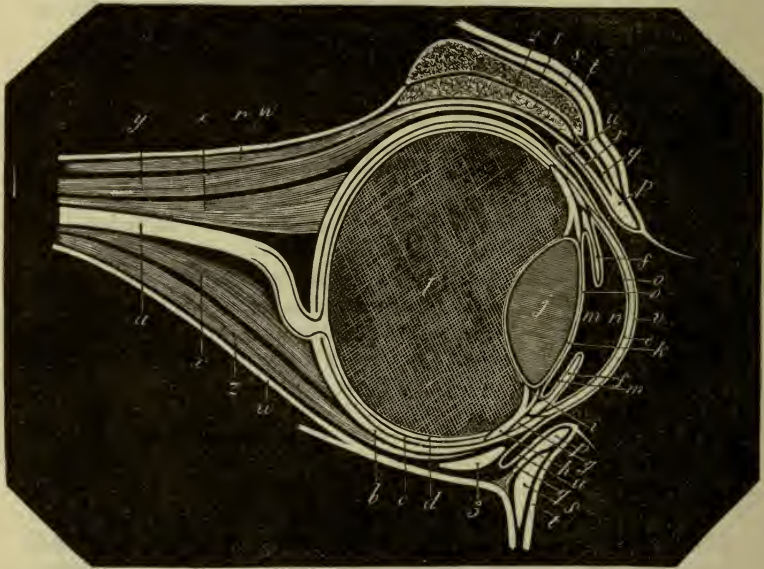
6. *Molecular layer*.

7. *Ganglionic layer*.

8. *Optic nerve fibres*.

At the point of entrance of the optic nerve, there is an oval point $\frac{1}{5}$ inch in diameter, where all nerve elements are absent; this is the blind spot.

FIG. 26.



THEORETICAL SECTION OF THE HORSE'S EYE.

- a*, Optic nerve; *b*, Sclerotic; *c*, Choroid; *d*, Retina; *e*, Cornea; *f*, Iris; *g*, *h*, Ciliary circle (or ligament) and processes given off by the choroid, though represented as isolated from it, in order to indicate their limits more clearly; *i*, Insertion of the ciliary processes on the crystalline lens; *j*, Crystalline lens; *k*, Crystalline capsule; *l*, Vitreous body; *m*, *n*, Anterior and posterior chambers; *o*, Theoretical indication of the membrane of the aqueous humor; *p*, *p*, Tarsi; *q*, *q*, Fibrous membrane of the eyelids; *r*, Elevator muscle of the upper eyelid; *s*, *s*, Orbicularis muscle of the eyelids; *t*, *t*, Skin of the eyelids; *u*, Conjunctiva; *v*, Epidermic layer of this membrane covering the cornea; *x*, Posterior rectus muscle; *y*, Superior rectus muscle; *z*, Inferior rectus muscle; *w*, Fibrous sheath of the orbit (or orbital membrane).

HUMORS.

These are the aqueous and vitreous humors, and crystalline humors.

The **Aqueous** humor fills up the space lying between the

cornea, pupil and iris (anterior chamber), is alkaline in reaction, consisting of water with $\frac{1}{50}$ solids.

The **Vitreous** fills up the space inside the retina and lens. It consists of gelatinous tissue.

The *crystalline lens* is $\frac{5}{10}$ by $\frac{6}{10}$ inches, lies behind the pupil and in front of the vitreous. It is a double convex lens of concentric layers, with an external capsule.

MUSCLES OF THE EYELID.

Orbicularis palpebrarum.

Origin.—Lachrymal tubercle.

Insertion.—Skin of both eyelids.

Action.—Sphincter of lids.

Levator palpebræ superioris externus.

Origin.—External surface of frontal near supra-orbital foramen.

Insertion.—Into orbicularis.

Action.—Wrinkles skin of upper lid.

Levator palpebræ superioris internus.

Origin.—Superior border of optic foramen.

Insertion.—Inner surface of upper lid and tarsal cartilage.

Action.—Raises upper lid.

Nerve Supply.

The latter by motor oculi, the others by facial.

MUSCLES OF GLOBE.

Retractor oculi.

Origin.—Optic foramen.

Insertion.—Outer and back part of sclera.

Superior, inferior, external and internal recti.

Origin.—Margin of optic foramen.

Insertion.—Above, below, outside and inside sclera.

Superior oblique.

Origin.—Optic foramen, passes to internal wall of orbit through a cartilaginous loop.

Insertion.—Into sclera, between superior and external recti.

Inferior oblique.

Origin.—Lachrymal fossa.

Insertion.—Under sclera.

Action.—The *superior rectus* turns the globe upward, the *inferior* down, the *external* out, the *internal* in, the *superior oblique*

upward and outward, the *inferior oblique* downward and inward, and the *retractor oculi*, as its name implies.

Nerves.—The sixth nerve supplies the *external rectus* and *retractor oculi*, the fourth the *superior oblique*, and the third the remainder.

APPENDAGES OF THE EYE.

The **Eyebrows** are small and furnished with long hairs.

The **Eyelids** are two in number, superior and inferior. The angles of *continuation* are called the *external* and *internal canthi*. They are covered with skin externally and conjunctiva internally, with long hairs and orifices of Meibomian glands on the edges. Their framework is made up of muscles and *tarsal cartilages*, two thin plates, the upper being the larger.

The **Meibomian Glands** pour out a sebaceous matter to lubricate the lids. They lie between the cartilage and conjunctiva and are tubular in character.

The **Conjunctiva** is a mucous membrane, thin and vascular, lining the lids and covering the anterior part of the globe.

The **Membrana Nictitans** is an accessory lid lying at the nasal angle of the orbit, composed of elastic cartilage. It serves to remove foreign bodies from the eye.

The **Caruncle** is a small, red elevation at the inner canthus, which directs the tears toward the puncta.

The **Tear Apparatus** consists of the *lachrymal gland*, *canaliculi*, *lachrymal sac* and *nasal duct*.

The *lachrymal gland* is conglomerate, lying under the roof of the orbit, and secretes the tears, which empty on the inner surface of the upper lid.

The excess of tears enter the *canaliculi*, two small canals in the upper and inner lids, which run from openings on the lids, the *puncta* to the *lachrymal sac*, a dilatation in the lachrymal fossa. This sac forms the beginning of the *nasal duct*, which runs down in the lachrymal bone as a membranous canal, to end near the nostril on its inner side.

The **Ocular Sheath** is a firm, fibrous membrane binding the structures of the orbit together.

Blood Supply.

Ophthalmic from *internal maxillary*, giving off *ciliary*, *arteria centralis retinae*, *supra-orbital*, and *lachrymal* to the gland.

THE SENSE OF TOUCH.

The special sense of touch is located in the skin, being more marked in the lips and extremities.

THE SKIN.

The *skin* is the outer, enveloping membrane of the body, and continuous with the outer limits of the internal mucous membranes. It is divided into the *derma* or *cutis vera*, internally, and the *epidermis*, externally.

The **Derma** forms the greater part of the thickness of the skin, being continuous with the subcutaneous connective tissue, internally, and the epidermis, externally, where it contains little elevations, the *papillæ*. It is composed internally of loose meshed tissue, the *corium*, and externally of the *papillæ*, arranged in parallel rows about $\frac{1}{150}$ of an inch in length.

The **Epidermis**, or cuticle, lying upon the derma, is more or less pigmented, and consists of an internal deep layer or *rete mucosum*, containing soft pigment cells and a superficial or *horny layer* of condensed, horny, flattened cells.

The **Appendages of the Skin** are the hairs, *sudoriferous* and *sebaceous* glands and *horny parts*.

THE HAIRS.

The *hairs* are modifications of skin, and are divided into the *hair proper*, forming the coat, and *horse hair*, long and flowing, found in the *forelock*, *mane*, *tail*, *eyelashes*, *lips* and *fetlock*.

Structure.

Hairs consist of a free, projecting portion, the *shaft*, of three layers, an *external* of flattened epidermal scales, a *middle* or *cortical* of narrow, epithelial lamellæ, pigment and air globules, and an *internal* or *medullary* of rectangular cells with fat and air globules; a *root* lying imbedded in the skin, in an involution, the *hair follicle* with *external* and *internal sheaths* and resting on the *papilla*, from which it takes its nutrition and growth.

The **SUDORIFEROUS GLANDS** are attached to the skin, consisting of a curled tubule lying in the corium and a spiral duct passing up through the derma and epidermis, lined with epithelium. Their function is the regulation of animal heat, and also are connected with excretion.

The **SEBACEOUS GLANDS** empty into the hair follicles or on the skin independently. They consist of vesicles filled with fatty and epithelial tissue, opening into a common duct. Their *function* is lubrication and protection, as well as preservation of the elasticity of the hair.

THE HORNY PARTS.

These comprise the *chestnuts*, *ergot* and *hoofs*.

The *Chestnut* is a small growth of epithelial tissue, oval in form, at the inner side of the upper metatarsal region, where it is smaller, and at the inner side of the forearm.

The *Ergot* is a similar structure attached to the skin of the fetlock.

The *Hoof*.—The hoof is the complicated apparatus surrounding the *third* or *distal phalanx*, *navicular bone*, and part of the *second phalanx*. The bones, articulations, muscles, nerves and vessels may all be found under their headings. It also consists of the *complementary apparatus*, *keratogenous membrane* and *hoof proper*.

THE COMPLEMENTARY APPARATUS.

This consists of the *fibro-cartilages*, two in number, united behind and below by the *plantar cushion*.

The **Cartilages** are two in number, attached in front to the anterior lateral ligament, behind to the basilar and retrorsal processes and plantar cushion; they are thin above, with a notch behind for vessels, thick below, concave internally, with vascular foramina, and convex externally, also with foramina for vessels.

They are composed of fibrous and cartilaginous tissue.

The **Plantar Cushion** is wedge-shaped, lying between the cartilages and below the insertion of the perforans.

The superior surface lies on the expansion of the perforans, and is attached by bands to the ergot, metacarpus and os pedis. The *inferior surface* is covered by the keratogenous membrane, and shows the *pyramidal body* moulded on the *frog* with its apex forward and two diverging arms behind. Its *base* terminates in *two bulbs*.

The *summit* is attached to the plantar surface of the os pedis.

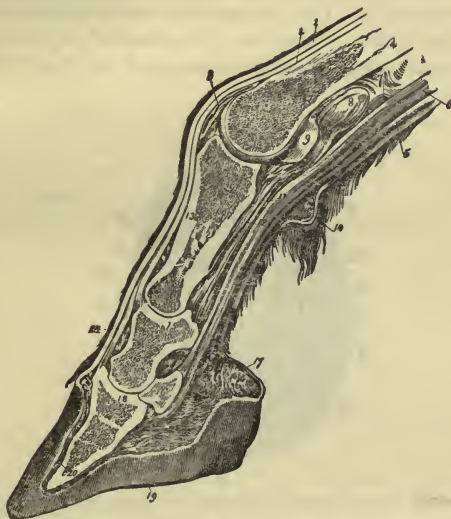
The *lateral borders* are attached to the cartilages.

Its *structure* is of fibrous, elastic and adipose tissue, with vessels and nerves.

The **Keratogenous Membrane** encloses the whole of the preceding structures, being itself enclosed by the hoof.

It consists of the *coronary cushion*, *velvety* and *laminal tissues*.

FIG. 27.



LONGITUDINAL MEDIAN SECTION OF THE FOOT.

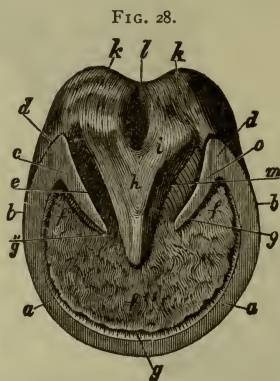
- 1, Anterior extensor of the phalanges, or extensor pedis; 2, Lateral extensor, or extensor suffraginis; 3, Capsule of metacarpo-phalangeal articulation; 4, Large metacarpal bone; 5, Superior flexor of the phalanges, or perforatus; 6, Deep flexor, or perforans; 7, Sheath; 8, Bursa; 9, Sesamoid bone; 10, Ergot and fatty cushion of fetlock; 11, Crucial ligament; 12, Short sesamoid ligament; 13, First phalanx; 14, Bursa; 15, Second phalanx; 16, Navicular bone; 17, Plantar cushion; 18, Third phalanx; 19, Plantar surface of hoof; 20, Sensitive or keratogenous membrane of third phalanx.

The **Coronary Cushion** resembles the derma, and forms the upper border of the membrane. Its inferior boundary is a white ring. Its superior has a margin, the *perioplic* ring. The extremities end behind in the velvety tissue. On its surface are numerous papillæ.

The **Velvety Tissue** is also papillary in structure, covering the plantar surface of the third phalanx and plantar cushion. At

its centre it is in relation with the pyramidal body and frogs, externally with the horny sole.

The **Laminal** (or **Podophyllous**) **Tissue** consists of 500 or 600 leaves on the front and sides of the os pedis, ending below in the plantar cushion, each one having five or six villi lodged in depressions in the sole. The laminae have secondary folds attached to them at their sides. They are composed of papillary structure, like the remainder of the membrane, and are the principal seat of the tactile sense.



PLANTAR OR GROUND SURFACE OF A HOOF; RIGHT FOOT.

The interval from *a* to *a* represents the toe. From *a* to *b*, *b*, outside and inside quarters; *c, o*, Commencement of bars; *d, d*, Inflexions of wall at the heels, or buttresses; *e*, Lateral lacuna; *f, f, f*, Sole; *g*, White line; *g', g'*, Ditto between the sole and bar; *h*, Body of frog; *i, i*, Branch of frog; *k, k*, Glomes, or heels of frog; *l*, Median lacuna.

The Hoof.

The box that envelops the foot is divided into three parts, the *wall*, *sole* and *frog*.

The *wall*, or *crust*, covers the front of the foot, and terminates behind by turning into the plantar cushion. Its front is called the *toe*, the sides of the toe being either the *inner* or *outer toe*, its lateral regions the *quarters*, the angle behind, where it turns into the plantar cushion, the *heels*, and these terminations the *bars*.

The *external surface* is smooth and convex, covered by a thin, horny layer, the *periople*.

The *internal surface* is continuous with the laminal tissue.

The *superior border* shows depressions for the villosities of the coronary tissue.

The *inferior border* is continuous with the sole, and behind is carried inward as the *bars*.

The **Sole** is a thick, horny plate, forming the inferior face of the hoof. Its *inferior* face is concave, and its *superior* has apertures for the villi above it. Its *outer border* is continuous with the external surface of the wall, its inner, as the *bars*, lie outside the *frog*.

The **Frog** is V-shaped, its base behind, apex in front, separated by a median depression. On either side are lateral depressions; at its base are two lateral elevations, the *glomes*. It lies between the bars and below the plantar cushion.

Structure of Hoof.—Horny tissue, a modification of the epidermis.

EQUINE PHYSIOLOGY.

Physiology is the study of the functions or actions of living structures or organs.

Equine Physiology treats of its application to the horse.

THE CIRCULATION.

The circulatory system consists of a central organ, the heart, *arteries*, *veins*, and *lymphatics* (for anatomical structure see above), the blood and lymph.

THE BLOOD.

The blood, the great nutritive fluid of the body, is about $\frac{1}{18}$ of the bodily weight in amount.

Its composition in 100 parts venous blood—

Corpuscles,	32.62
Plasma,	67.38
	<hr/>
	100.00

The corpuscles consist of—

Water,	56
Solids,	43
	<hr/>
	99

The plasma consists of—

Solids,	9.16
Water,	90.84
	<hr/>
	100.00

The solids of plasma are—

Fibrin,	1.91
Albumin,	7.76
Fats,12
Extractives,40
Soluble salts,64
Insoluble salts,17

10.10

The *Specific Gravity* of the horse's blood is 1055, its *Reaction* alkaline, and its *Temperature* 36.5 to 37.8 Cent. (Charles.)

The *corpuscles* are found in two forms, the *red* and *white*.

The *red corpuscles* are bi-concave disks, with no nuclei, tending to adhere in rolls, with a diameter of .005 mm. They contain the coloring matter, the hæmoglobin, which in the horse contains 43 per cent. of iron, and also C, H, N, O, and S (Preyer). The hæmoglobin forms about 90 per cent. of the red disks (Smith). Their function is to absorb and carry oxygen.

The *white corpuscles* are much less numerous than the red, the proportion being on an average one white to 300 red. They are globular in shape and are 0.01 mm. in diameter, and contain several nuclei. They are derived from lymphoid tissue, and are probably developed into red corpuscles. They have the power of *amœboid* movement by pushing out processes, and of passing through the walls of vessels.

COAGULATION OF BLOOD.

When blood is placed in a vessel after removal from the body, it goes through a process called *coagulation*: First, in a few minutes a yellow scum appears on top, the *buffy coat*; second, the corpuscles settle to the bottom, forming a reddish layer. Then drops of serum are seen on the sides and top. In 12 or 15 hours the serum and clot are completely separated.

The *serum* differs from *plasma* in not containing fibrin.

The specific gravity of *plasma* is 1027-1028.

Theory of Coagulation (Schmidt).

Fibrinogen and *fibrinoplastin*, with the fibrin-ferment, derived probably from white corpuscles, come together and cause coagulation.

Coagulation is hastened by a temperature of 100° F., contact

with air, rough surfaces and rest, and *retarded* by cold, neutral salts in excess, exclusion of air, etc. (Brubaker.)

Arterial Blood contains more oxygen and less carbon dioxide than venous; is scarlet in color, from the presence of oxy-hæmoglobin. *Venous* blood is purple in color.

The blood of the *portal vein* is rich in water, albuminous matter and sugar, and the *hepatic* is rich in corpuscles and sugar.

CIRCULATION OF THE BLOOD.

The blood may be traced from the left ventricle, through the aorta, to the capillaries, where it passes into the veins, being returned to the right auricle by the anterior and posterior cavas. From there it passes to the right ventricle, through the pulmonary artery, to the lungs, where it is oxygenated. It is then returned to the left auricle by the pulmonary veins, and from there to the ventricle. By this it is seen that the heart is the central organ of the circulation, and propels the blood by alternate contractions and dilatations. The contraction is known as the *systole*, the dilatation as the *diastole*.

The *phenomena attending the systole* are a hardening, shortening, a movement of the apex downward, and a twisting of the heart from left to right.

If the heart's cycle is divided into ten-tenths, during the first four-tenths the *ventricles contract* simultaneously and the *auricles* are *passive*; in the second four-tenths the *auricles dilate* and the *ventricles* are *passive*; in the last two-tenths the *auricles contract* and the *ventricles dilate*.

The **sounds** of the heart are known as the first and second, with an interval of silence after the latter. The *first sound* occupies four-tenths, the *second* three-tenths, the *interval of silence* three-tenths.

The *first sound* is longer, louder, lower in pitch and more booming than the second, and is *caused* by (1) the closing of the auriculo-ventricular valves; (2) the apex striking against the chest; (3) the contraction of the muscular fibres; (4) the sound of the blood passing through the interior.

The *second sound* is shorter, higher in pitch, and clicking, and is caused by the *closure* of the mitral and tricuspid valves.

The force of the heart, or *vis a tergo*, is more than sufficient to carry the blood through the system.

The **number of pulsations** of the heart per minute are from 36 to 40. In the new born horse they are 120, and at the end of the first year from 48 to 56.

Their relation to the respiratory movements are on an average one to four (the number of respiratory acts being ten per minute, usually).

The *capacity* of the ventricles is each about 20 ounces.

The *entire blood in the body* would pass through the left ventricle in 66 seconds in an animal of 1000 pounds weight, assuming the amount of blood to be $55\frac{5}{10}$ pounds ($\frac{1}{8}$ of the bodily weight), and requiring 44.4 pulsations.

Arterial Pressure is the force exerted by the blood on the vessels, and is measured by a tube introduced into some of the large vessels. In the carotid the blood pressure equals 32 mm. of mercury; in the brachial 150 mm.

The **Arteries** may be divided into three sets (Flint), the *largest* ending at the carotid and iliacs, with elastic walls; the *medium* from these to $\frac{1}{2}$ of an inch in diameter; the *smallest* from $\frac{1}{2}$ of an inch to the capillaries. The median are elastic and contractile, the smallest only contractile.

The *velocity of the arterial current* varies in the different arteries; it is the greatest during systole, least during diastole. In the *carotid* it is 300 mm. per second; in the maxillary 165 mm. per second; metatarsal 56 mm.

The **Capillaries** form the communication between the arterial and venous vessels, and the current of blood is much slower, only $\frac{5}{10}$ to $\frac{8}{10}$ mm. per second, the blood pressure being only 35 mm. In the capillaries the oxygen is absorbed by the tissues.

The *velocity of the venous current* varies: in the jugular vein being 100 mm., and in the vena cava 110 mm. per second. The blood pressure of the venous system is much less and the capacity much more than the arterial.

Vierordt showed that 31.5 seconds after injection of a salt solution into one jugular, it could be detected in the vein of the opposite side.

The valves of veins prevent damming back of blood.

The flow of blood is kept up in the veins—

- 1st. By the *vis a tergo* of the heart.
- 2d. By the *vis a fronte* or suction force of the thorax.
- 3d. By muscular contraction on the walls of the veins.

Action of the nervous system on circulation.

The heart is under control of both the cerebro-spinal and sympathetic nervous systems, being supplied by the pneumogastric nerve and the cervical sympathetic, there being also probably some intracardiac sympathetic ganglia.

The *pneumogastric* has an *inhibitory action* on the heart, as shown by section of the nerves, which is followed by an increased frequency of the heart's action.

The *sympathetic* has an *accelerative action* on the heart, as shown by the previous experiment, and also by stimulation of the fibres, which is followed by an increased number of pulsations. Stimulation of the tenth nerve is followed by decreased pulsations, and if a strong current is used, by paralysis of the heart in diastole, by stimulation of its inhibitory action.

Local circulation is regulated by the vaso-motor nerves of the sympathetic system. They are known as *vaso-dilators* and *vaso-contractors*.

RESPIRATION.

Respiration consists of an appropriation of oxygen by the tissues and a giving off of carbonic oxide gas.

The respiratory organs consist, from above downward, of the (1) *nasal fossæ*, (2) *pharynx*, (3) *larynx*, (4) *trachea*, (5) *bronchi*, and (6) *lungs*. (For anatomical descriptions, see *Viscera*.)

The different steps of respiration consist—

1st. Of the introduction of atmospheric air into the lungs in inspiration.

2d. Of the taking up of oxygen by the blood.

3d. Of the appropriation of oxygen by the tissues.

4th. Of the exhalation of carbonic acid gas in expiration.

In **Inspiration** the air passes through the mouth or nasal cavities to the larynx, the glottis being dilated, then to the alveoli of the lungs, which it distends.

Muscles of Inspiration.

The *diaphragm* is the most important, becoming flattened, and at the convexity decreased.

The *external intercostals* and *supercostals* raise the ribs and carry them forward, thus enlarging the lateral diameter of the thorax.

In *forced inspiration* we have coming into action the *latissimus dorsi*, *serratus anticus minor* and *scaleni*.

In **Expiration** the air is forced out of the air passages, and is in a passive condition usually, except in forced expiration.

The **Muscles of Expiration** are the *diaphragm*, coming forward in a dome-shape, decreasing the antero-posterior diameter of the thorax.

The *internal intercostals*, *triangularis sterni* and *serratus posticus minor* act by carrying the ribs backward.

In *forced expiration* we have coming to action the *ilio-spinalis*, *external* and *internal oblique*, *transversalis* and *rectus* of the abdominal tunic, by depressing and retracting the posterior ribs.

Number of Respirations per Minute.

Ordinary movements,	10
Walking two hundred yards,	28
Trotting five minutes,	52
After five minutes' gallop,	52

(Colin-Smith.)

Capacity of the Lungs.

In man the extreme breathing capacity of the lungs is over three hundred cubic inches, but the ordinary capacity is only about two hundred cubic inches.

The *tidal* air is that breathed in and out in tranquil respiration.

The *reserve* air is that remaining after an ordinary expiration, but which can be expelled in a full expiration.

The *residual* air is that which always remains after a forced expiration.

The *complemental* air is that which can be taken into the lung in a forced inspiration.

The measurements of the capacity of the horse's lungs are unimportant, but are probably about five or six times as extensive as those of man.

Changes in the Air in its Passage through the Lungs.

Atmospheric air consists of—

Nitrogen,	79.15 parts.
Oxygen,	20.81 “
Carbon dioxide,04 “
	100.00

In its passage through the lungs it loses oxygen and gains CO_2 , expired air consisting of—

Nitrogen,	79.557
Oxygen,	16.033
CO_2	4.38
	<hr/>
	99.970

The taking up of oxygen and giving off of CO_2 takes place by the law of diffusion of gases, illustrated by simple experiments. That expired air contains CO_2 may be shown by blowing into a jar of lime-water, the liquid becoming turbid from the change into carbonate of lime, and giving off of CO_2 in form of bubbles. These bubbles, when collected, will not support combustion, and turn blue litmus red.

The greater part of the oxygen consumed is returned in the form of CO_2 , about eight out of ten parts, the remainder being thrown off by the urine and skin, or uniting with hydrogen in the body. Solids and moisture in varying proportions are also thrown off.

Changes in the Blood during Respiration.

Arterial blood contains in one hundred parts—

Oxygen	20	volumes.
Carbonic dioxide	36	“
Nitrogen	1-2	“

Venous blood contains in one hundred parts—

Oxygen	8-12	volumes.
Carbonic dioxide	46	“
Nitrogen	1-2	“

The oxygen exists in the blood in the red blood corpuscles as *oxy-hæmoglobin*, being given off in the peripheral capillaries, and then is known as *reduced hæmoglobin*.

The carbon dioxide exists in serum in a loose state or as soluble carbonates.

The nitrogen exists in solution in the blood serum, and can be expressed by a small vacuum.

The gases compose about 60 per cent. of the volume of the blood.

Nervous Mechanism of Respiration.

Respiration is involuntary usually, as it is carried on during

sleep and in unconsciousness from drugs, though it is also modified by the will.

It is under the control of the cerebro-spinal nervous system, though the sympathetic forms plexuses at the root of the lung.

The *respiratory centre* is in the floor of the fourth ventricle and a puncture at that point stops respiration immediately. If the brain is removed above the medulla, the act still goes on. If the carotid and vertebral arteries are ligated, the animal develops dyspnœa at once, owing to a deficiency of oxygen at the centre. The nerves of respiration are the two *phrenics*, two *pneumogastriks*, *intercostals* to the muscles of the chest, the *cervical* and *lumbar* to the muscles of the neck, back and abdomen.

The **Phrenics**.—If the phrenics are both cut, the diaphragm is paralyzed; if a single one, that side only remains passive. If a section is made of the cord above the fifth cervical nerve, we have instant stopping of respiration, due to paralysis of the diaphragm and thoracic muscles, and immediate death. Life may be continued a short time after both phrenics have been divided, as the intercostal muscles still act.

The **Intercostals** act very simply by supplying the ordinary muscles of expiration and inspiration. If a single one is divided, the remainder do its work.

The **Cervical** and **Lumbar** nerves supply the muscles generally of forced inspiration and expiration.

The **Pneumogastriks**.—These are distributed at the roots of the lungs, and if one is cut, respiration becomes very slow. Section of both causes marked decrease in respirations, and death in four or five days. A weak galvanic current applied to the nerve increases the number and force of the respiratory acts. Stimulation of the central end of its divided superior laryngeal branch causes slow respiration; and if strong, paralyzes it in forced expiration.

ALIMENTATION.

Alimentation is the process of receiving or taking nourishment; it may be divided into *digestion* and *absorption*.

Digestion is the preparation of food for absorption.

Absorption is the process by which the digested food enters the circulation.

Nourishment or *food* is necessary to repair waste and for the growth of the animal.

The *food* of the horse, being herbivorous, consists of the following:

(a) *Cereals*, as wheat, barley, corn, rice, and oats. They contain over eighty per cent. of solids, which consist of albumin, small amounts of fat, carbohydrates, and non-nitrogenous extractives. Corn and rye are rich in starch, but poor in albumin. Oats are very rich in starch, about fifty per cent., and also contain nine per cent. of albumin and six per cent. of fat. Oats also contain ferments, which digest starch and proteids as well as forming lactic acid; assisting the stomach very materially in digestion.

(b) *Bulbs and roots*, as potatoes, containing large amounts of water and starch; fodder and sugar beets; cabbages, containing a large amount of starch, sugar and cellulose in small amounts.

(c) *Leguminous plants*, as peas and beans.

(d) *Grasses*, as prairie-hay, rye-straw, grass, clover, etc. Green grass contains seventy-five per cent. water, clover sixty per cent.

(e) *Inorganic matter* as *water, common salt, lime and potassium salts, and iron.*

Sodium chloride, or common salt, is essential, and regulates endosmosis and exosmosis. Other salts are deposited in bone. The iron forms the coloring matter of the blood.

The Amount of Food Required.

The horse needs daily 7500 grammes of hay and 2270 of oats, or 10 kilos (22 lbs.) of hay, and 2 kilos (4.4 lbs.) of oats to every 100 kilo (220 lbs.) of body weight. Colin says that the horse will eat 26 kinds of plants, and reject 212 (Meade-Smith).

It should receive daily about two per cent. of its body weight in solid food, and should be in the proportion of 1 to 4 of nitrogenous and non-nitrogenous material. The different steps of digestion are *prehension, mastication, salivary digestion, deglutition, gastric and intestinal digestion, absorption and defecation*, or expulsion from the body of the residue not required for alimentation.

PREHENSION.

Prehension is the process of transferring the food to the mouth, and is the first or primary act of digestion.

The upper lip carries the food to the teeth, the long neck and

head being carried to the ground; the head then makes a quick movement to the side, and the food is carried to the side of the mouth to be ground up by the molars (see *Teeth*).

Liquid may be taken in by (a) sucking, in the young; (b) pumping by piston action of tongue, (c) aspiration; by an inspiratory movement. The second one is the most often used by the horse.

MASTICATION.

Mastication is a complex act, in which the food is triturated in the mouth between the two jaws and teeth. (For anatomical considerations, see *Teeth*.)

Movements of the jaws.

In the horse these are *depression*, *elevation* and *rotation*, and in mastication make eighty strokes per minute. The *incisors* serve to bite off a portion of food, which is then, by the tongue and muscles of the face, carried between the molars, where it is comminuted to a much greater degree.

THE TIME OF THE APPEARANCE OF THE TEETH.

Meade-Smith, from Kreutzer.

	ERUPTION.	CHANGE.
<i>Incisors:—</i>		
Central,	Before or few days after birth.	2 years.
Middle,	4 to 6 weeks.	3½ years.
Outer,	6 to 9 months.	4½ years.
<i>Canines,</i>		
	4 to 5 years.	
<i>Molars:—</i>		
1,	Before or few days after birth.	2½ years.
2,	Before or few days after birth.	2½ years.
3,	Before or few days after birth.	3 years.
4,	10 to 12 months.	3 years.
5,	1½ to 2 years.	3 years.
6,	4 to 5 years.	3 years.

SALIVARY DIGESTION.

For anatomical considerations, see *Mouth*.

Saliva is alkaline in reaction, its specific gravity is 1004.5, and its amount in 24 hours is 84 pounds. Its composition (Meade-Smith, from Lassaigue) is as follows for mixed saliva—

Water	992.00
Mucus and albumin.....	2.00
Carbonates	1.08
Chlorides	4.92
Phosphates, etc.	traces.
	1000.00

It also contains epithelium, mucin, ptyalin, serum, albumin, globulin and sulpho-cyanide of potassium.

The parotid saliva is the largest in amount and most watery.

The sub-maxillary is viscid and contains no albumin, and the sub-lingual is very viscid and contains a large amount of solids.

Action of the Saliva.—It has a *mechanical action*, by lubricating the bolus of food, and a *chemical* by the action of its ferment, *ptyalin*. This converts starch into sugar, and cane sugar into grape sugar. As this process takes several minutes, it continues going on in the stomach.

DEGLUTITION.

The act of deglutition consists of the passage of the food from the mouth to the stomach; it is divided into three stages; the *first stage* comprises the passage of the bolus from the mouth through the fauces to the pharynx; the *second*, its passage through the pharynx, and the *third* when it passes through the œsophagus.

In the first stage, the tip, body and base of the tongue press against the hard palate, and push the bolus along toward the pharynx, the teeth being closed. The *palato-glossi* and *pharyngei* then contract and force the bolus into the pharynx, the palatal curtain being carried against the superior pharyngeal wall.

In the *second stage* the constrictors contract, the epiglottis closes the top of the larynx, and the bolus is passed into the œsophagus.

In the *third stage* the œsophagus contracts on the bolus, and

by the movement of its circular and longitudinal fibres forces it through the cardiac orifice of the stomach into that viscus.

The first stage is voluntary, the others involuntary.

The horse can make from 65 to 90 motions of deglutition per minute for fluids.

GASTRIC DIGESTION.

From the difficulty or impossibility of making a gastric fistula in the horse, the amount and composition of the gastric juice is hard to estimate. Its specific gravity is about 1010, its reaction acid and its composition is as follows—

Fluids,	{ Water Hydrochloric acid..... Lactic acid	} 982.80
Solids		17.20
		1000.00

The solids are—

Pepsin,
 Milk-curdling ferment,
 Chlorides,
 Phosphates,
 Iron.

The amount of acids varies from 0.084 per cent. to 0.2 per cent.

The juice from the fundus of the stomach contains more ferment, more acid and more mucus than that from the pylorus.

Action of Gastric Juice.

The gastric juice changes starch into sugar, not of itself, but by the saliva, which still continues its action, converts vegetable albumin into peptones, and digests cellulose by fermentation to some extent. In feeding the horse the food should be taken in the following order: *first* water, *second* hay, *third* oats, as the water if given last would wash the food into the intestine before it was acted upon by the gastric juice, while if hay was given after oats, it would carry them along with it, as it is principally digested in the intestines, the oats being acted upon by the stomach for the most part. The stomach is never completely empty, as some food remains after 24 hours.

Vomiting in the horse is very infrequent and difficult, on account of there being no dilatation of the stomach at the point where the œsophagus enters, the œsophagus being very narrow at its termination and being nearly filled by folds of its mucous membrane.

It takes place by a deep inspiration, forcing the diaphragm down and fixing it; then a relaxation of the œsophageal orifice, with a spasmodic contraction of the abdominal muscles, completes the act.

THE BILE.

The bile, secreted by the liver, acts upon the food in the upper part of the small intestine. It is brownish-green in color, alkaline in action, bitter in taste. Its specific gravity is higher than the gastric and lower than the pancreatic juice, and its amount in 24 hours is from 11 to 13½ pounds.

Its composition is as follows:—

Water.	
Mucin.	
Bile salts	{ Glycocholate of Soda.
	{ Taurocholate of Soda.
Bile coloring matter	{ Bilirubin.
	{ Biliverdin.
Cholesterin.	
Iron and salts.	

The *Mucin* comes from the biliary passages, not from the liver cells.

Gmelin's Test for Biliary Pigment.

Spread a drop of diluted bile on a porcelain plate and add a drop of yellow nitric acid to it. A play of colors results, green, blue, violet and yellow. (Charles.)

Pettenkofer's Test for Biliary Acids.

Add a little sugar to the fluid, then shake and add a few drops of strong sulphuric acid. A beautiful purple or violet coloration will appear.

Cholesterin is excreted by the liver, and is derived from broken-down nerve-tissue. Under the microscope it appears as delicate, thin, flattened, super-imposed plates, with one corner broken off.

Action of the Bile in Digestion.

1. It dissolves and emulsifies fats and liberates fatty acids in small amounts.
2. It acts as a stimulus to peristalsis by its irritant action on the intestinal mucous membrane.
3. It prevents decomposition of fæces, the fæces being colored by the bile pigments in the form of hydro-bilirubin.
4. It is said to contain a ferment in small amount, capable of converting starch into sugar.

Glycogenic Function.

From observation it has been found that the liver has another function—the changing of the carbohydrates and albumin into a new substance, glycogen, $C_6H_{10}O_5$, whitish in color, inodorous, amorphous, insoluble in alcohol or ether, but imperfectly soluble in boiling water (Charles). It is taken up in the form of glucose, then stored up as glycogen, and then changed into glucose again, when it is carried away from the liver.

Uses of Glycogen.—It is probably burned up in the lungs, circulation and muscles in generating animal heat, and in muscular action.

Puncture of the floor of the medulla causes glycosuria, as shown by Bernard. *An animal deprived of bile* by a fistula dies of starvation after losing four-tenths of its bodily weight.

THE PANCREATIC JUICE.

The secretion of the pancreas is colorless and alkaline in reaction. It is coagulated by heat, metallic salts, tannic acid, etc.; is easily decomposed, emitting an offensive odor. Its specific gravity is about 1020, and amount in 24 hours is about $12\frac{1}{2}$ pounds. Its composition is as follows:—

Water,	982.05
Organic matter,	8.88
Ash,	8.59

The ash consists of phosphates, chlorides, iron and magnesium. The organic matter consists of four ferments—an amyolytic, a proteolytic, one acting on fats, and a milk-curdling ferment. The first may be extracted by a solution of arseniate of potas-

sium with a little ammonia added; the second by potassium iodide, and the third by a solution of bicarbonate of soda with a little caustic soda.

Action of the Pancreatic Juice.

1. It changes starch and glucose into sugar rapidly and completely. Cane-sugar not acted upon.
2. It emulsifies and saponifies fats completely with the aid of the bile.
3. It converts albumin into peptones.
4. It, by means of a special ferment, curdles milk. This ferment can be extracted by a solution of common salt, but has not yet been isolated in the horse.

THE INTESTINAL JUICE.

This is secreted by Brunner's glands and the crypts of Lieberkuhn. Its specific gravity is about 1010, alkaline in reaction, and its composition is as follows (Charles, from Colin):

Water	98.10
Solids.....	1.90
	<hr/>
Albumin and other organic matters.....	0.45
Carbonate of soda	1.45
	<hr/>

Its amount in 24 hours is difficult to estimate, Colin having found about 12 ounces an hour in about six feet of gut. This may be increased by injection into the gut of irritants.

Its **Action** is much the same as the pancreas, dissolving proteids and albumin, and converting starch into sugar.

The gases found in the intestine are oxygen, nitrogen, carbon dioxide, hydrogen, ammonia, carburetted and sulphuretted hydrogen. About 60 per cent. of the proteids have to be digested in the small intestine.

DIGESTION IN THE LARGE INTESTINE.

The **Cæcum** serves as a reservoir for the food after about 24 hours, the fermentative changes of the small intestine still going on in an alkaline medium. About 20 per cent. of the food is digested in that viscus, and about 40 per cent. of the cellulose.

The **Colon** acts principally as an absorbing area, the food passing through its several curvatures and the floating colon before reaching the rectum. The diaphragmatic curvature contains large amounts of fluid.

THE FÆCES.

The residue of aliment after digestion is expelled from the rectum in rounded balls as fæces. Horses defecate every three hours, and will pass about 17 kilos or 37.4 pounds, or 5.8 of solids.

About 13 per cent. are inorganic materials.

DEFECATION.

Defecation is the process of evacuation of the rectum. The presence of fecal matter in the rectum leads to the desire to expel it. The brain then sends an inhibitory action to the reflex centre in the lumbar cord, which causes a relaxation of the sphincter muscles. Contraction of the abdominal muscles and small colon, with the circular fibres of the rectum, then take place, causing a propulsion of the fæces through the anus. The mucous membrane of the opening is everted, then pulled back by the retractor muscles.

INTESTINAL MOVEMENTS.

The food is carried along by peristalsis, a worm-like motion of the intestine due to involuntary contraction of both the longitudinal and circular muscular fibres. The irritation of the bile is an active factor in keeping it up.

ABSORPTION.

Absorption is the process of taking up the food principles after digestion, also water and salts that have not been acted upon. It takes place by means of lymphatics and veins.

By veins.—The water, salts, sugar, soaps and peptones are absorbed quickly by osmosis, and also by some special function of the epithelial cells of the villi.

By lymphatics.—This takes place by the villi (see *Intestines*); the emulsified food elements passing into their interior by the intercellular connective tissue, then by the lymph channels of the

mesentery to the receptaculum. *Lymph* is an alkaline, viscid fluid of a specific gravity of about 1030; its amount in 24 hours, 72 kilos or 158 pounds. Its composition is (Smith, from C. Schmidt):

Water,	963.93
Solids,	36.07
	1000.00

Solids are—

Fibrin, }	28.84
Albumin, }	
Fats, etc., }	
Inorganic salts	7.22
	36.06

It contains lymph corpuscles, identical with white blood corpuscles in structure.

The *course* of the lymph is from the various lymphatics of the periphery to the receptaculum, then through the thoracic duct into the confluence of the jugulars. *Chyle* is lymph during digestion, and contains emulsified fats in addition to its usual composition. It passes through the villi to the thoracic duct. Its composition (Charles, from Schmidt) is—

Serum,	96.74
Clot,	3.25
Water,	88.7
Solids,	11.2

Solids are—

Fats,	0.15
Soaps,	0.03
Fibrin,	3.89
Albumin, sugar, etc.,	6.59
Hæmatin, salts,	—

After a meal the chyle is very abundant, during fasting very small in amount. The flow of lymph is kept up by the contraction of their walls, by the aspiration of the diaphragm, contraction of the abdominal muscles, and the peristalsis of the intestines.

ANIMAL HEAT.

The process of nutrition and oxidation of food products is accompanied by the evolution of heat. This gives the body an average temperature which, in the horse, varies between 37.5° C. and 38° C.

Sources of Animal Heat.

This is the result of oxidation of the hydrocarbons and carbohydrates as well as the combination of hydrogen and oxygen forming water.

Heat Units.—The English heat unit is the amount of heat requisite to raise one pound of water, 1° F. In the horse for each kilo of weight, 2.1 heat units are set free per hour, or for an animal of 500 kilos, as an example, 1050 heat units per hour, or in a day $2.1 \times 500 \times 24 = 25,200$ heat units. In a man of 140 pounds, 13,440 heat units are thrown off in the same time.

The temperature is raised by exercise, due to increased tissue metabolism, and the urea is increased.

The temperature of the blood of the portal vein is usually several degrees higher than the average temperature of the body.

SECRETION.

Secretion (Flint) is the act by which fluids holding certain principles in solution are separated from the blood, or are manufactured by special organs from materials furnished by the blood. These have a function to perform.

An *Excretion* contains elements not formed in the substance of the gland which have no function to perform and are extracted from the blood.

There are always two periods in every secreting organ—

1st, The *period of repose*, or period of no secretion; though the manufacture of the solid elements is constantly going on.

2d, The *period of functional activity*, in which the formed elements are washed out by the water from the blood, which is eight times as abundant in this stage.

Classes of secreting organs.

1. The most simple is a basement membrane covered with flattened cells, as the peritoneum.

2. The next is more secreting surface with not much more space, as the simple depressions of Lieberkühn in the small intestines.

3. The second variety have two or more branches leading into a common duct, as in Brunner's glands.

4. Where a number of the third variety open into a common duct, the compound racemose glands, as the salivary and pancreatic glands.

5. Tubular glands composed of a number of elongated tubes, as in the testicle and kidney.

6. The ductless glands, as the spleen and supra-renal capsules.

7. Unclassified glands, as the liver.

The *Permanent fluids* are the *aqueous* and *vitreous humors* of the eye, *synovial*, *serous*, *cerebro-spinal* and fluid of the *internal ear*.

The *Transitory fluids* are *mucus*, *cerumen*, *sebaceous matter*, *Meibomian*, *tears*, *milk* and all the *digestive fluids*.

The *Excretions* are the *urine*, *sweat*, *fæces*, and *bile*, which is also a secretion in part.

THE PERSPIRATION.

(For anatomy of skin, see *Sense of Touch*.)

The perspiration is of low specific gravity, about 1004, alkaline or neutral in reaction, and contains about 2 per cent. of solids, consisting of urea, fats, cholesterin and salts. Its amount varies with exercise and in different parts of the body, being most abundant in the inguinal region. When it is secreted in small amounts not to be seen by the eye it is called *insensible*; when in large amounts, *sensible* perspiration.

Its *functions* are the regulation of animal heat and also excretion of urea, etc.

Section of the cervical sympathetic increases the secretion in that part, and certain drugs, as Jaborandi, have a like action.

The *Sabaceous matter* of the skin consists of about $\frac{1}{3}$ water and $\frac{2}{3}$ solids, of albumin, epithelium, fat, soaps and salts.

It acts as a lubricant to the skin and hair.

THE MAMMARY SECRETION.

Milk is secreted soon after the birth of the foal, obtained by suction, is alkaline in reaction and of a specific gravity of about 1030. It consists of (Charles, from Gorup-Besanez):

Water	82.84
Solids	17.16

100.00

Casein, }	1.64
Albumin, }	
Butter,	6.87
Milk sugar, }	8.65
Organic salts, }	
	17.16

The gases of milk (Pflüger) are carbonic anhydride, oxygen and nitrogen.

Colostrum is the milk secreted a short time after parturition. It is yellow in color, of a higher specific gravity, slightly acid, contains large oil globules covered with casein, and has purgative properties.

The mammæ at the time of gestation become enlarged, pendent, soft. The epithelium becomes rounded, and contains a large amount of fat.

Milk can be coagulated by acids, tannin and mineral salts by coagulating the casein.

Mare's milk contains a large amount of *sugar*, which, by the addition of an acid takes on a lactic acid fermentation, as in the preparation of *koumiss*.

The rapidity and amount of the mammary secretion are dependent on arterial pressure. Certain drugs have more or less action upon it.

URINE.

Urine, the excretion of the kidneys, is a watery, yellowish fluid, holding in suspension many solids, which are excreted in this form. It is alkaline in reaction when the animal feeds on vegetable food, and its specific gravity varies from 1016 to 1060, usually about 1050. Its composition is (Smith, from Boussingault):

Urea.....	31.
Potass. hippurate.	4.7
Alkaline lactates.....	20.1
Potass. bicarb.....	15.5
Magn. carb.....	4.2
Calcium carb.....	10.8
Potass. sulph.	4.2
Sodium chloride.....	0.7
Silica	1.0
Water	910.0
	1000.0

Mucin is abundant. The urea is dependent on the amount of oats, grain and roots ingested, the hippuric acid ($C_9H_9NO_3$), to which and phenol the odor is due, on the amount of green stuff, hay and straw.

The amount in twenty-four hours is five or six litres, varying with the amount of fluid excreted by the sweat glands.

The secretion of urine takes place—

1. By *filtration*, the water and soluble salts passing out into the interior of the glomerulus.

2. By *active secretion*, urea being secreted by the epithelial cells of the convoluted tubules. The latter process has been proved by injecting *indigo carmine* into the blood after section of the spinal cord to prevent filtration. The carmine can be found in the cells of the convoluted tubes, and also in the urine, none being found in the glomerulus.

Urine is decreased in summer, due to the increased amount of secretion by the skin, by slowing the heart, by sleep and rest.

It is *increased* by cold weather, stimulation of the heart, after eating, and also by stimulation of the medulla.

After secretion, the urine passes into the pelvis of the kidney, through the ureter, drop by drop, into the bladder, where it is accumulated till discharged, the bladder being emptied three or four times in twenty-four hours.

Nervous mechanism of micturition.

The centre for micturition is located in the lumbar enlargement of the cord. The sensation of fullness is carried to this centre, which sends back an impulse, relaxing the contracted sphincter, and causing a contraction of the longitudinal (or *detrusor*) fibres. This forces the contents into the urethra, the contraction of its fibres terminating the act.

After section of the spinal cord, a condition known as *retention with overflow* takes place, the bladder is distended, and soon also the *sphincter vesicæ* by mechanical means, the urine escaping drop by drop and soon becoming ammoniacal.

THE DUCTLESS GLANDS.

These are the *spleen*, see *Abdomen*; the *thyroid* and *thymus*, see *Thorax*; and the *supra-renal capsules*, see *Kidney*.

The **Supra-renal capsules** are relatively larger before birth, can be extirpated with no apparent result, are probably connected

in some way with the sympathetic system, but their function is not known.

The **Spleen** probably influences digestion, and Shiff and Herzon claim that the secretion of trypsin, one of the pancreatic ferments, is dependent on it.

In its structure are found pigment, broken-down red corpuscles and many leucocytes. It also serves as a reservoir for the abdominal circulation. It can be removed without loss of life, and is a blood gland.

The **Thyroid** and **Thymus** have to do with the elaboration of blood, otherwise their function is unknown.

The **Pituitary Body** and **Conarium** also properly belong in this category, but their function is unknown.

THE NERVOUS SYSTEM.

The nervous system connects into a coördinated organism all parts of the body. It receives all impressions, regulates all movements, voluntary and involuntary, and the functions of secretion, nutrition, calorification and all processes of animal life. (Flint.) The *cerebro-spinal system* consists of the brain, cord and the various nerves, and presides over *animal life*. The *sympathetic* presides over nutrition or *organic life*.

(For structure of nerves, see *Anatomy of Nervous System*.)

Termination of nerves.

To *voluntary muscular fibres* the nerve divides and spreads out into plaques.

To *involuntary fibres*, it loses its tubular membrane and terminates in the nucleus as the axis cylinder.

The *Sensory nerves* terminate—

(a) As minute plexuses with no fixed arrangement.

(b) As the *tactile corpuscles* or *end bulbs of Krause*, found most abundantly in the lip, hoof, sheath and glans penis. These are small capsules of connective tissue, the nerve terminating in a plexus or bulbous extremity. They have also a *central termination* either in the brain or cord, connected to a cell pole by an axis cylinder. After its origin a nerve does not inosculate but passes to its terminus.

Nerves are divided into *motor* and *sensory*, the former ending

in muscles and conducting the stimulus by which the muscle acts, the latter carrying sensation from the periphery to the centre.

Nerves act as conductors, but do not produce anything.

A nerve's function is manifested at its terminus.

Nerve stimulation can be accomplished mechanically, chemically or thermically, also by a mild current of electricity.

Rate of nervous conduction is 250 feet per second (electrotonus, for lack of space, will not be described).

The *Spinal nerves* are 42 or 43 in number, arranged in pairs (for description, see Nerves). The superior or sensory nerves end in the superior or sensory horns of the gray matter of the cord, the inferior or motors end in the inferior or motor horns. *Stimulation* of the former causes pain at its peripheral distribution, and *section* loss of sensation at the same point. Stimulation of the latter causes contraction of the muscles to which it is supplied, and *section* motor paralysis of the same.

THE CRANIAL NERVES.

The **First** or **Olfactory** will be discussed under *Smell*.

The **Second** or **Optic** terminates in the retina, the fibres decussating.

Section of one tract before discussion, causes total blindness of the outer half of the eye of the same side and the inner half of the opposite. Injuries of the visual centre produce the same result.

The **Third** or **Oculo-motor** is entirely motor, and supplies all the muscles of the eye, except the external rectus, great oblique and part of the posterior rectus, the pupil with contractility and movements of the ciliary muscles. *Section* causes external strabismus, ptosis, dilation of the pupil, and inability to rotate the globe in a vertical direction.

The **Fourth** or **Patheticus** is entirely motor, and paralysis causes inability to rotate the eye laterally.

The **Fifth** or **Trifacial** is a mixed nerve, viz., both sensory and motor. The ophthalmic and superior maxillary branches are entirely sensory, the inferior maxillary both sensory and motor. Division of the nerve in front of the Gasserian ganglion causes loss of sensation in its course and also trophic changes in the eye-

ball, the latter not taking place if the action is made behind the ganglion, by leaving the sympathetic attachments intact. Stimulation causes exquisite pain, as it is the most sensitive nerve in the body. Section of the inferior maxillary branch causes paralysis of the muscles of mastication on the same side, and loss of sensation in one lateral half of the tongue. Stimulation causes a spasm of the same muscles.

The **Sixth** or **Abducens** is purely motor, and, if cut, we have an inability to carry the eye outward.

The **Seventh** or **Facial** is motor, and also sends the chorda tympani as a special nerve of taste to the anterior two-thirds of the tongue.

Section causes paralysis of the superficial muscles of the face, stapedius, occipito-styloid, digastric, stylo-hyoid, subcutaneous muscle of the neck and soft palate through the great petrosal to Meckel's ganglion. There is also loss of taste on the anterior two-thirds of the tongue on the same side.

Stimulation causes contraction of the same muscles.

The **Eighth** or **Auditory** is a nerve of special sense purely.

Section produces deafness on the same side.

The **Ninth** or **Glosso-pharyngeal** is a mixed nerve, being one of general sensation to the pharynx and fauces, of special sense of taste to the back part of the tongue, and of motion to the pharyngeal muscles in part. It is concerned obviously in deglutition.

The **Tenth** or **Pneumogastric**.

The *auricular* branch gives sensation to the external ear.

The *pharyngeal* gives sensation to pharynx and to muscles concerned in deglutition.

If the *superior laryngeal* branch is stimulated, spasm of the glottis and diaphragm results.

If the *inferior laryngeal* is cut, an arrest of the respiratory movements of the glottis takes place, as it supplies all the muscles of the larynx except the crico-thyroid.

Cardiac Branches.—If the nerve is cut in the neck, its inhibitory action on the heart is taken off and it is increased in frequency. Galvanization of the peripheral end decreases its action and stops it in diastole, if strong enough.

Pulmonary Branches.—If the nerves are cut in the neck, the respirations are markedly diminished, death finally occurring. Galvanization increases the number; if strong may arrest it.

Esophageal Branches.—Paralysis of these causes an inability to swallow food, which remains in the gullet. It is finally vomited by irritation of the tube.

Gastric Branches.—If the left nerve is cut during digestion, secretion and motion at once cease; slightly irritated, it causes glycosuria.

After division, the bile becomes more fluid in character, the formation of glycogen ceases, and purgatives have no longer any effect.

Eleventh or Spinal Accessory.

This is a motor nerve as well as supplying the larynx through the laryngeals.

Stimulation causes spasm of the *sterno-maxillaris*, *mastoido-humeralis*, and *cervical* and *dorsal trapezius*.

Division causes paralysis of these as well as shortness of breath, from incoördination of muscles and inability to make a prolonged vocal sound.

Twelfth or Hypoglossal.

This is purely motor and division causes paralysis of the muscles of the tongue and difficulty in mastication and deglutition.

THE SPINAL CORD.

The inferior motor roots emerge from the larger extremity of the horn of gray matter on either side, and communicate with the large multipolar motor cells found in groups in that situation.

The superior or sensory roots enter the cord, immediately communicating with the tripolar sensory cells of the smaller extremity of the gray matter, which comes to the surface.

Some of both the motor and sensory roots enter the columns of the opposite side or lateral tracts, not all of the fibres thus passing up or down at the same point.

Decussation of motor and sensory tracts.

Most of the motor nerves cross to the opposite side at the medulla, the nerves from the right side of the brain ending on the left side of the body, and *vice versâ*. Some of the motor roots continue down the cord on the same side as the *direct pyramidal tract*.

The *sensory nerves decussate* all along the cord, not at one fixed point, ending at the sensory portion of the internal capsule and hippocampus major. Thus one side of the brain governs the sensation of the opposite side.

Functions of the Cord.

I. *As a conductor.* II. *As an independent nerve centre.*

I. *As a Conductor.*—The inferior and inferior lateral columns convey motor impulses from the brain to the periphery. If a section of both motor tracts is made, motor paralysis will result below that point. If one tract, motor paralysis on the same side only.

If the sensory portion of the cord is cut completely, a similar absence of sensation below that point and inability to coördinate will be the result. If a unilateral sensory section is made, there will be complete loss of sensation on the opposite side.

Section of one lateral half of the cord causes motor paralysis on the same side, with hyperæsthesia and sensory paralysis on the other.

II. *As a Nerve Centre.*—If a frog is decapitated and placed in a vacuum it will remain quiet. Now, if its surface is irritated, muscular contraction will result. If the cord is broken up no such phenomena take place, showing that the cord controlled these movements, which are called *reflex actions*. The sensory nerves convey the impression to a centre in the cord, which sends it back to the muscles, causing a contraction (Flint).

The *gray substance* of the cord is neither *sensible* nor *excitable*.

The *inferior lateral white columns* are *excitable* throughout, but *not sensible*.

The *superior columns* are *sensible*, more so at the entrance of the posterior nerve-roots. They are not *excitable*. Deeply, they are *neither excitable* nor *sensible*.

THE ENCEPHALON.

The encephalon consists of the *medulla oblongata*, *pons*, *corpora striata*, *corpora quadrigemina*, *optic thalami*, *olfactory lobes*, *cerebellum* and *cerebrum*.

MEDULLA OBLONGATA.

This serves as a medium of *transmission* of *motor* and *sensory impulses*, and also as the centre for numerous functions, as *mastication*, *deglutition*, *vomiting*, a *cardiac centre*, a *vasomotor centre*

and a *respiratory centre*. The *glycosuric centre* has been already referred to (see *Liver*).

PONS VAROLII.

The superficial fibres are *not excitable* or *sensible*; the deeper are *excitable*, and the posterior are only *sensible*. It presides over voluntary motion and sensation.

CORPORA STRIATA.

Electrical stimulation of one of these causes general muscular contraction on the opposite side. Destruction of the internal capsule causes loss of motion and sensation on the opposite side of the body. The anterior part of the internal capsule is motor, the posterior sensory.

CORPORA QUADRIGEMINA.

They are situated in the path of visual conduction, and are connected with the sense of sight and the reflex movement of the iris.

OPTIC THALAMI.

These are probably connected with sensation, vision and complex muscular actions, though their function is not thoroughly understood.

OLFACTORY LOBES.

These are the centres for the special sense of smell, and their destruction causes a loss of this sense. Fibres have been traced to the uncinata gyrus, temporo-sphenoidal region and optic thalami.

CEREBELLUM.

The cerebellum presides over the coördination of movements of progression, being connected intimately with the superior column of the cord. Their destruction leads to absence of coördination.

CEREBRUM.

The *cerebral hemispheres* are the centres of intellect or mind, receiving impressions and giving off impulses. An animal deprived of the cerebrum retains the special senses of sight, sound, taste, etc., but the intellectual faculties are all lost. From experimentation on the lower animals and by observation in disease, centres have been located which preside over certain functions.

The *motor area* is located in the cortex above the fissure of

Sylvius and at the junction of the anterior with the middle third of the surface. The upper part presides over the hinder extremity of the opposite side, the middle over the anterior extremity, and the lower over the face. In front of the latter in man is found the speech centre on the left side.

The *centre for sight* is located in the occipital region; those for *smell, hearing* and *taste* in the temporo-sphenoidal region.

THE SYMPATHETIC SYSTEM.

This chain of twenty-eight ganglia is sensible after long stimulation.

After section of the cord in the neck, there is increased vascularity by paralyzing the coats of the small vessels.

Functions.—It influences the general process of nutrition and forms the *vasomotor system*. This sends branches to small blood-vessels, and influences local circulation by *vaso-dilators* and *vaso-contractors*.

SPECIAL SENSES.

TOUCH.

When a foreign body is brought into contact with the surface, it is appreciated by the nerves of the part as the special sense of touch.

This sense is located in the skin and also on mucous membranes for a certain distance. The termination of nerves in the skin has been already noticed. In the horse, with a single digit covered with hard material, the hoof is an imperfect organ of touch, but can estimate solidity and resistance.

The lip is a well-marked tactile organ, the end bulbs of Krause being very abundant.

SMELL.

The sense of smell is very acute in the horse. It has already been sufficiently considered under the anatomical description.

TASTE.

Taste enables the animal to detect the flavor of substances. The anterior two-thirds of the tongue preside over the ability to recognize acids and alkalies, and is supplied by the chorda tym-

pani of the seventh, the posterior one-third, recognizing bitters and sweets, being supplied by the glosso-pharyngeal nerve. The circumvallate or calyciform papillæ are probably gustatory, the other papillæ serving to entangle substances, so that their flavor can be detected.

HEARING.

The **External Ear** collects the sound-waves and carries them inward to the membrana tympani.

The Middle Ear.

The *membrana tympani* receives the sound-waves and transmits them through the ossicles to the foramen ovale opening into the vestibule.

The *Eustachian tube* allows air to enter the tympanum, and thus equalizes the pressure on both sides of the membrana tympani. The guttural pouch, at its termination below, is probably connected with phonation.

The Internal Ear.

The *semicircular canals* have some function connected with maintaining equilibrium.

The *organs of Corti* are probably the essential parts of the internal ear, and here the sound-waves are recognized, each sound by a separate organ, the organs receiving the waves by vibrations of the endolymph transmitted from the perilymph.

SIGHT.

Sight is the special sense by which we are enabled to form an idea of objects by means of the eye.

Mechanism.

The rays of light enter the eye by passing through the cornea, aqueous humor, pupil, crystalline lens and vitreous to the retina, where they are recognized and the impression sent to the brain by the optic nerve.

The *function* of the *cornea*, *aqueous*, and *lens* is to refract the rays of light and bring them to a focus on the retina.

The *iris* regulates the amount of light entering the eye by means of its muscular fibres dilating and contracting the pupil.

The *retina* receives the impression of light, the layer of rods

and cones being the most sensitive portion. The point of entrance of the optic nerve is known as the *blind spot*.

Accommodation.

When an object is distant, the rays of light are more parallel, less refraction is necessary, and the lens is flattened. When the object is near, the opposite condition holds, the lens becoming convex by contraction of the ciliary muscle; this decreasing the intra-ocular pressure and allowing the lens to increase in thickness. In the ordinary condition the intra-ocular pressure on the suspensory ligament of the lens retains it in a flattened state.

Space need not, obviously, be given to errors of refraction and accommodation.

REPRODUCTION.

For discussion of copulation and development of the embryo, see works on Veterinary Obstetrics and Embryology.

COMPLIMENTS
OF
P. Blakiston's Son Co.,
PHILADELPHIA, PA.

INDEX.

- Abdomen, 123
Absorption, 188
Anatomy, 9
Angiology, 81
Animal heat, 190
Anus, 128
Aorta, anterior, 85
 common, 85
 posterior, 93
 thoracic, 93
Arterial pressure, 176
Arteries, structure of, 85
Artery, anterior radial, 87
 tibial, 97
 axillary, 85
 collateral of cannon, 88
 common carotid, 89
 interosseous, 88
 external carotid, 91
 iliac, 96
 femoral, 96
 humeral, 87
 internal carotid, 91
 iliac, 96
 pedal, 98
 popliteal, 97
 posterior radial, 87
 tibial, 97
 pulmonary, 98
 spermatic, 95
Arthrology, 37
Articulations, 37
 of anterior extremity, 41
 classes of, 37
 hyoid, 40
 of lower jaw, 39
 of posterior extremity, 45
 structure of, 38
 thoracic, 40
 vertebral, 38

Bile, action of, 186
 amount of, 185
 composition of, 185
 tests for, 185
Bladder, 144
Blood, amount of, 173
 coagulation of, 174
 composition of, 173
 gases in arterial, 179
 venous, 179
 plasma of, 173

Bone, hyoid, 24
 number of, 10
 structure of, 10
Bones of anterior extremity, 25
 face, 18
 head, 13
 pelvis, 31
 posterior extremity, 31
 thorax, 24
 varieties of, 9
 vertebral column, 11
Brain (see Cerebrum)
 membranes of, 105
Bronchi, 138

Cæcum, 128
 digestion in, 187
Cerebellum, 107
 function of, 199
Cerebrum, 105
 fissures of, 107
 functions of, 199
 lobes of, 108
 ventricles of, 109
Chyle, composition of, 189
Circulation, 175
 nervous mechanism of, 177
Colon, large, 128
 small, 128
Concha, 157
Corpora quadrigemina, 106
 function of, 199
Cowper's glands, 148

Defecation, 188
 nervous mechanism of, 188
Deglutition, 183
 stages of, 183
Digestion, 180
 in large intestine, 187
Digestive system, 120
Ductless glands, 140
 function of, 193
Duodenum, 125

Ear, 157
 external, 157
 canal of, 159
 cartilages of, 157
 muscles of, 158

- Ear, internal, 161
 middle, 159
 Epididymis, 146
 Eustachian tube, 160
 Excretion, 190
 Expiration, 178
 changes of air in, 178
 muscles of, 178
 Eye, appendages of, 166
 blood supply of, 167
 function of, 201
 humors, 162
 muscles of globe of, 165
 lids of, 165
 tunics of, 162

 Fæces, 188
 amount of, 188
 Fluids, permanent, 191
 transitory, 191
 Food, 181
 amount of, required, 181

 Gastric juice, action of, 184
 amount of, 184
 composition of, 184
 Guttural pouches, 160

 Hair, 168
 Hearing, 201
 Heart, blood supply of, 84
 cavities of, 83
 diastole of, 175
 nerve supply of, 84
 number of pulsations of, 176
 sounds of, 175
 systole of, 175
 valves of, 83, 84
 weight of, 81
 Heat units, number of, 190
 Hoofs, 168
 Hymen, 151

 Ileum, 125
 Inspiration, muscles of, 177
 Intestinal juice, action of, 186
 composition of, 187
 movements, 188
 Isthmus, parts of, 106

 Jejunum, 125

 Kidneys, 141
 function of, 192
 hilum of, 141
 Malpighian bodies of, 141
 pelvis of, 141

 Larynx, 133
 cartilages of, 133
 ligaments of, 134
 movements of, 177
 muscles of, 135
 nerve supply of, 136

 Liver, 129
 fissures of, 129
 glycogenic functions of, 186
 ligaments of, 129
 lobes of, 129
 parenchyma of, 129
 Lungs, 138
 Lymph, amount of, 189
 composition of, 189
 Lymphatic duct, 103
 glands, 102
 Lymphatics, 102

 Malpighian corpuscles, 143
 Mammary glands, 155
 function of, 191
 Mastication, 182
 Mastoid cells, 159
 Mediastinæ, 140
 Medulla oblongata, 105
 function of, 198
 Membrana tympani, 159
 Micturition, mechanism of, 193
 Milk, composition of, 191
 Mouth, 120
 Muscles, appendages of, 50
 of abdomen, 65
 of anterior extremity, 66
 of back, 63
 of ear, 158
 of eye, 165
 of face, 51
 of foot, 72
 of hyoid, 54
 of inferior cervical region, 57
 of leg, 77
 of mastication, 53
 of palate, 55
 of pelvis, 72
 of perineum, 150
 of pharynx, 56
 of tail, 80
 of thigh, 75
 of thorax, 63
 of tongue, 55
 of trunk, 57
 structure of, 50
 varieties of, 50
 Myology, 50

 Nasal fossæ, 155
 Nerve, abducens, 113
 auditory, 113
 facial, 113
 glosso-pharyngeal, 113
 hypo-glossal, 114
 oculo-motor, 111
 olfactory, 111
 optic, 111
 patheticus, 111
 pneumogastric, 114
 spinal accessory, 114
 tri-facial, 112
 ganglia of, 111
 Nerves, brachial plexus of, 115
 cervical, 115

- Nerves, cranial, function of, 195
 dorsal, 118
 lumbo-sacral plexus of, 117
 structure of, 103
 terminations of, 103
 Nervous system, 103
 divisions of, 103
 structure of, 103
 Neurology, 103
 Nostrils, 156
- Esophagus, 122
 Olfactory lobes, function of, 199
 Optic thalami, 107
 Orbits, 162
 Ossicles of tympanum, 160
 Ovaries, 153
 Oviducts, 153
- Palate, 120
 Pancreas, 131
 Pancreatic juice, action of, 186
 amount of, 186
 composition of, 186
 Pericardium, 81
 Perineum, 150
 Peritoneum, 132
 reflections of, 133
 structure of, 133
 Penis, 149
 Perspiration, 191
 function of, 191
 Peyer's glands, 127
 Pharynx, 122
 Physiology, 173
 Pineal gland, 107
 Pituitary gland, 107
 Pleura, 139
 Pons varolii, 106
 function of, 199
 Prehension, 181
 Prostate gland, 148
- Receptaculum chyli, 103
 Rectum, 128
 Reflex action, 198
 Reproduction, 202
 Respiration, 177
 nervous mechanism of, 179
 number of movements of, 178
 Respiratory organs, 133
- Saliva, 183
 amount of, 183
 composition of, 183
 function of, 183
 Salivary glands, 122
 structure of, 122
 varieties of, 122
 Schneiderian membrane, 156
 Secretion, 190
 Sight, 201
 Sinuses of dura, 99
 Skin, 167
 glands of, 168
- Skull, fossæ of, 23
 Small intestine, 125
 Smell, 200
 Spinal cord, 103
 columns of, 104
 fissures of, 104
 functions of, 198
 membranes of, 104
- Spleen, 132
 function of, 194
 Stomach, 123
 capacity of, 123
 coats of, 123
 glands of, 125
 Supra-renal capsules, 144
 function of, 193
 Sympathetic nervous system, 118
 function of, 193
- Taste, nerves of, 157
 papillæ of, 157
 Teeth, 120
 action of, 182
 structure of, 121
 varieties of, 121
 Testicles, 145
 descent of, 146
 function of, 147
 Thoracic duct, 103
 Thorax, 140
 Thymus, 141
 function of, 194
 Thyroid, 140
 function of, 194
 Tongue, 120
 Touch, 200
 Trachea, 136
 Tunica vaginalis testis, 145
- Ureters, 144
 Urethra, female, 151
 male, 148
 Urinary organs, 141
 Urine, 192
 composition of, 192
 Uriniferous tubes, 143
 Uterus, 152
- Vagina, 151
 Valve, pyloric, 124
 of Vieussens, 110
 Valvulæ conniventes, 127
 Vas deferens, 147
 Veins, jugular, 99
 of abdomen, 101
 of anterior extremity, 99
 of head and neck, 99
 of posterior extremity, 102
 portal, 101
 pulmonary, 102
 saphenous, 102
 Vesiculæ seminales, 147
 Villi, 127
 Viscera, 120
 Vulva, 150
 bulbs of, 151

A Companion Volume to Gould's Pocket Dictionary

A POCKET CYCLOPEDIA OF MEDICINE *and* SURGERY

EDITED BY

GEORGE M. GOULD, A.M., M.D.

Author of "Gould's Medical Dictionaries," Editor of "American Medicine"

AND

WALTER L. PYLE, A.M., M.D.

Assistant Surgeon Wills Eye Hospital, Philadelphia; formerly Editor
"International Medical Magazine," etc.

BEING BASED UPON GOULD AND PYLE'S LARGE "CYCLOPEDIA OF
PRACTICAL MEDICINE AND SURGERY"

Uniform with Gould's Pocket Dictionary. 64mo. Flexible Leather,
Gilt Edges, Round Corners, net \$1.00; with Thumb Index, \$1.25



HIS book bears to Gould and Pyle's large "Cyclopedia of Medicine and Surgery" a relation similar to that which the Pocket Dictionary bears to Gould's complete "Illustrated Dictionary." As the Dictionary gives the derivation, pronunciation, and definition of medical **words**, the Cyclopedia is designed to furnish general information concerning medical **subjects**. Every subject, concerning which the student may desire a brief and thorough description, supplementing the mention which may be given in lectures or a general text-book, is taken up and treated thoroughly and concisely. To those desiring concise authoritative information on medical or surgical themes or who wish to look up any new term or matter of recent discovery and use, the book will prove invaluable. It includes articles on Emergencies, Hygiene, Poisons, Nursing, etc.; describes Drugs and their Uses; gives Treatment of Diseases; explains Surgical Operations; contains many Prescriptions and Formulæ, Tables of Differential Diagnosis, Dose Table in both English and Metric Systems, etc.

P. BLAKISTON'S SON & CO., Publishers and Booksellers
1012 WALNUT STREET, PHILADELPHIA

FOR MEDICAL STUDENTS.

BINNIE. C. **PLASTIC SURGERY.** A Manual for Practitioners and Students. By JOHN FAIRBAIRN BINNIE, A.M., C.M. (Aberdeen);

DATE DUE SLIP

UNIVERSITY OF CALIFORNIA MEDICAL SCHOOL LIBRARY

THIS BOOK IS DUE ON THE LAST DATE STAMPED BELOW

Dec 11

DEC 27 1937

JUL 2 - 1940

14 DAY

MAY 5 1965

RETURNED
BY MAIL

7/27/73

14 DAY

APR 2 1965

RETURNED

MAR 31 1965

14 DAY

MAY 2 1965
RETURNED

APR 4 - 1965

American
Chirurgie,
Engravers,
rs, \$3.00

PATH-
ans. By
iversity of
Edition.
rs, \$2.50

EASES,
RS IN
of Berlin.
RLES W.
Jefferson
colored,
et, \$6.00

Edition.
cal Mid-
City, etc.
Original

er, \$7.00
Includ-
of Patho-
Pathology
on. 495
et, \$4.00

IECOL-
D., Pro-
; Gyne-
strations,
t, \$5.00.

ICINE.
oroughly
N, M.D.,
atologist,

ers, \$2.50
Edition.
strator of

ity. 153
et, \$1.50
ye, Ear,
strations.
et, \$1.50

sellers.

BRUBAKER.
By ALBERT
Hygiene, Jeff
College of D
356 Illustrati

HANSELL A
Treatise on
Surgery. B
Ophthalmolo
Eye, Philad
Ophthalmic
SWEET, M.
Assistant A
College Ho
etc. With

KYLE. MA
THROA
of Otolog
Indiana,
etc. Wi

WILLIAM
WILLIA
partner
With a

TYSON.
Editio
and N
vised.

TYSON.
Editio
tions.

BLAKIS
Thro
Foot

SWAN
and
geon
Rev

GREEN
A M
M.D
the
of I
230

BART
Bod
BA
the

L737 Ballou, W.R.
U6B1
1907
... A compend
anatomy and
ogy.

8502
of equine
physiol-

8502

6350352



3 1378 00635 0352

Library of the
University of California Medical School and Hospitals

